

Stereotactic Radiosurgery for Vestibular Schwannomas

Ummei Hani, Saqib Bakhshi, M Shahzad Shamim

Abstract

The approach to treating vestibular schwannomas ranges from wait-and-scan policies to micro-and radiosurgery. However, in the past few decades, Stereotactic Radiosurgery (SRS) has emerged as an approved primary treatment option as well. In this review, we have assessed some of the existing literature on the role of SRS in the management of vestibular schwannomas, and to estimate its efficacy in tumour control and conservation of cranial nerve function.

Keywords: Vestibular Schwannoma, Acoustic Neuroma, Stereotactic Radiosurgery, Gamma Knife

Introduction

Vestibular Schwannomas (VS) are primary brain tumours, comprising 80% of the cerebellopontine lesions of the brain.¹ Throughout the last three decades, the management strategies of VS have ranged from observation to microsurgical resection and radiosurgery, based on the Koos classification that stratify tumours based on tumour volume, extra-meatal extension and compression of the brainstem.^{1,2} Stereotactic radiosurgery (SRS) has established itself as a valid treatment option for solitary small/medium sized lesions, ranging from 25-30 mm in cisternal diameter, and for residual lesions after microsurgical debulking.³⁻⁵

While microsurgical resection has remained the mainstay of treatment for tumours more than 30mm and/or those compressing the brainstem (Koos grade IV), SRS has emerged as a popular treatment modality since Leksell first used the Gamma Knife SRS (GK-SRS) to treat a VS in 1969. (4-6) The literature prior to 1992 reported increased morbidity with SRS, majorly due to the lesion being treated with higher tumour margin doses (16 Gy), or pseudo progression of large VS following SRS.^{5,6} However, recent studies reported improved outcomes with optimal dosing (12-13 Gy), along with using sophisticated dose-planning software and high-resolution stereotactic MRI.^{3,6} In this study, we have reviewed the literature for long term patient

outcomes in patients undergoing SRS as the primary treatment modality for small, medium and large sized Vestibular Schwannomas. The studies are reported in chronological order, the older papers reported first.

Review of Evidence

Kondziolka et al., in their 1998 landmark publication reviewed 182 patients who had undergone GK-SRS at a mean dose of 16.6 Gy as the primary treatment for VS.⁷ At 1 year of follow-up, 73.8% of the tumours had unchanged volume, while 25.5% decreased in size. At 5 years, 72% tumours had shrunk, with the lesion stable in the rest 28%. Preservation of pre-treatment facial nerve function was seen in 79% while hearing was preserved in 51% of the patients.⁷ In another landmark paper with 927 patients studied prospectively, Regis et al., strongly supported the use of GK-SRS for VS over microsurgery, in terms of tumour control and preservation of functional hearing.⁸ The patient population had lesions ranging from Koos grade I to grade IV, with an average tumour volume of 12.7 mm³, and useful hearing in at least 47% of the patients. Post-

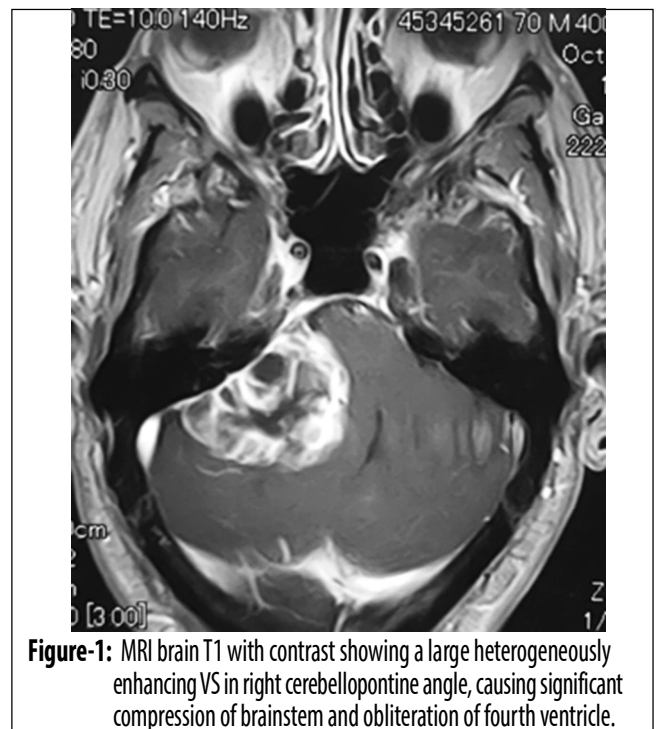


Figure-1: MRI brain T1 with contrast showing a large heterogeneously enhancing VS in right cerebellopontine angle, causing significant compression of brainstem and obliteration of fourth ventricle.

The Aga Khan University Hospital, Karachi, Pakistan.

Correspondence: Muhammad Shahzad Shamim
e-mail: shahzad.shamim@aku.edu

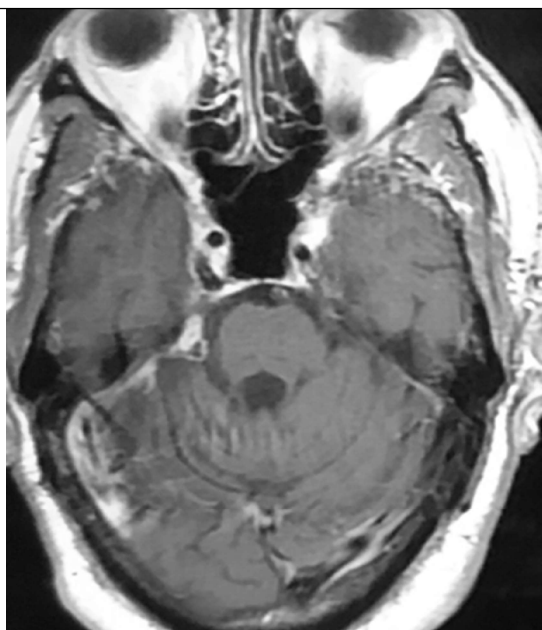


Figure-2: Post-operative MRI brain T1 with contrast of the same patient showing a small residual tumour.

treatment tumour control at the last follow-up was 97%, with hearing preservation in 62.7% of the patients at 3 years. Despite 42 stage 4 lesions included in the study, only few permanent complications such as trigeminal injury and facial palsy were noted in 0.6% and 1.3% of the patient population, respectively.⁸

Nagano et al., prospectively analyzed 87 patients studying the efficacy of GK-SRS.⁹ Mean tumour volume at the time of presentation was 2.5 cm³ (ranging from 0.1 to 13.3 cm³, with transient volume expansion in 58% of the tumours at 8.6 months of follow-up. A 31% mean reduction in tumour size was noticed at 5 years of follow-up, while 9 tumours progressed in size from their initial volumes. Homogeneously enhancing tumours were reported to demonstrate less shrinkage. (9) Van De Langenberg et al., retrospectively reviewed 33 patients with large, progressive, Koos grade IV VS which were more than 6 cm³ in size and at least indenting the brainstem.¹⁰ Mean tumour volume at presentation was 8.8 cm³ (6.1-17.7 cm³) and control was assessed at a median follow-up of 30 months. Radiological growth control and clinical growth control were achieved in 88% and 76% of the patients, respectively. Mild, transient complications of facial and trigeminal neuropathy were noticed in 8 patients. Preserved serviceable hearing, facial and trigeminal functions were 58%, 91% and 86% respectively.¹⁰

Hayashi et al., in his study of 260 VS patients with tumours ranging from Koos grade I through IV (0.1-9.0 cm³ tumour volume), reported 94.6% loss of central contrast enhancement at 6 months of follow-up and significant transient enlargement of more than 2 mm in any dimension in 25.8% of tumours at 12 months. At 3 years of follow up with 182 patients, tumour control and shrinkage were noted to be 98.4% and 76.4% respectively, with more than 50% mean reduction in the tumour volume. Pretreatment facial nerve function was preserved in 97.8%, with improvement in 2.2% of the patient population. Serviceable hearing was preserved in 87.9% patients, with improved hearing in 7 patients (3.8%).⁴ After having reviewed 379 VS patients undergoing SRS as primary treatment in 2014, Boari et al., concluded that better outcomes could be achieved if the time between symptom onset, diagnosis and treatment was shortened.¹¹ Mean tumour volume at presentation was 1.94 cm³ (0.013 - 14.3 cm³), which was treated at a mean marginal dose of 13Gy. Tumour control was achieved in 97.1%. 82.5% tumours shrunk by a relative reduction of 34.1%. Complication rate was low, with transient symptom worsening being the most common complication. Pretreatment symptoms of vertigo, balance disturbances, and facial and trigeminal neuropathy were completely resolved after treatment. However, there was no significant resolution of tinnitus. A total of 49% of the patients had preservation of functional hearing at long term follow-up, with better hearing outcomes in younger patients.¹¹ Iorio-Morin et al., evaluated 68 patients with Koos stage IV VS undergoing primary treatment with GK-SRS.¹² Median tumour volume at the time of presentation was 7.4 cm³ (4-19 cm³), with a baseline serviceable hearing in 60% of the patients. A median marginal dose of 12 Gy was used. Actuarial tumour control was 92% at 10 years of follow up. Hearing was preserved in 89% of the patients at 2 years of follow up and decreased to 49% at 5 years. Facial nerve function was preserved in 100% of the patients. Balance disturbances, facial pain, facial numbness and tinnitus were few of the reported complications, however, all were mild and transient.¹² Another study by Bailo et al., evaluated 59 patients with VS greater than 2.5 cm³ in size, and concluded that while surgical resection should remain the primary approach for large size VS, SRS provided with a safe and effective alternative in patients who were not good candidates for surgery. Mean tumour volume at presentation was 5.98 cc, with maximum

volume up to 14.3 cc. Tumour control and shrinkage were achieved in 98.4% and 86.4% of the patients respectively. Functional hearing was preserved in 31.3% of the patients. However, 5.1% (n=3) patients developed a permanent facial nerve deficit while 6.8% (n=4) people developed new or worsened trigeminal impairment. New onset hydrocephalus requiring treatment with VP shunt was seen in 18.5% (n=10) of the patients.³

Lefranc et al., reviewed 86 patients with grade IV VS who underwent primary treatment with GK-SRS and reported GK-SRS to be safe and effective in patients with no symptoms of brainstem compression or trigeminal dysfunction at presentation. Patients were followed up for 3-16 years and tumour control with no clinical deterioration was achieved in 90.7% (n=78) of the patients. 36 patients had functional hearing loss before treatment, which was preserved in 25 patients post treatment. 9.3% of the cases underwent delayed surgical resection or ventricular shunting for tumour growth after radiosurgery.⁵ Johnson et al., recently reported outcomes of 871 patients who underwent treatment for VS primarily with GK-SRS.¹ Median tumour volume was 0.9 cc (0.02-36 cc), and the tumours were treated with a median marginal dose of 13 Gy. The follow-up period ranged from 1-25 years. Progression Free Survival (PFS) was 97% at 3 years, 95% at 5 years and 94% at 10 years follow up, with only 1.3% of the patients undergoing subsequent microsurgical resection for progressive tumour growth. Small tumour volumes were reported to be associated with better PFS.¹ 326 patients had serviceable hearing (GR 1 or 2) at the time of SRS, which was preserved in 89.8% at 1 year, 68.4% at 5 years and 51.4% at 10 years of onset. Post-SRS 5.8% (n=51) patients developed trigeminal neuropathy, while 1.6% of the patients developed a transient facial palsy of House Brackman grade 2 to 3.¹

Conclusion

SRS is an efficient treatment modality for small, medium,

and asymptomatic large sized vestibular schwannomas, both in terms of tumour control, and cranial nerve preservation. However, these studies do not report the technical difficulties and morbidity associated with microsurgical resection of post-SRS tumours, in cases where SRS fails.

References

1. Johnson S, Kano H, Faramand A, Pease M, Nakamura A, Hassib M, et al. Long term results of primary radiosurgery for vestibular schwannomas. *J Neurooncol* 2019;145:247-55.
2. Erickson NJ, Schmalz PG, Agee BS, Fort M, Walters BC, McGrew BM, et al. Koos Classification of Vestibular Schwannomas: A Reliability Study. *Neurosurg.* 2019 1;85:409-414. doi: 10.1093/neuros/nyy409.
3. Bailo M, Boari N, Franzin A, Gagliardi F, Spina A, del Vecchio A, et al. Gamma Knife radiosurgery as primary treatment for large vestibular schwannomas: clinical results at long-term follow-up in a series of 59 patients. *World neurosurg.* 2016;95:487-501.
4. Hayashi M, Chernov MF, Lipski SM, Tamura N, Yomo S, Horiba A, et al. Do we really still need an open surgery for treatment of patients with vestibular schwannomas? *Gamma Knife Neurosurgery in the Management of Intracranial Disorders: Springer;* 2013. p. 25-36.
5. Lefranc M, Da Roz LM, Balossier A, Thomassin JM, Roche PH, Regis J. Place of Gamma Knife stereotactic radiosurgery in grade 4 vestibular schwannoma based on case series of 86 patients with long-term follow-up. *World neurosurg.* 2018;114:e1192-e8.
6. Battista RA. Gamma knife radiosurgery for vestibular schwannoma. *Otolaryngol. Clin. North Am.* 2009;42:635-54.
7. Kondziolka D, Lunsford LD, McLaughlin MR, Flickinger JC. Long-term outcomes after radiosurgery for acoustic neuromas. *N Engl J Med* 1998;339:1426-33.
8. Regis J, Delsanti C, Roche P, Thomassin J, Pellet W. Functional outcomes of radiosurgical treatment of vestibular schwannomas: 1000 successive cases and review of the literature. *Neuro-Chirurgie.* 2004;50(2-3 Pt 2):301-11.
9. Nagano O, Serizawa T, Higuchi Y, Matsuda S, Sato MR, Yamakami I, et al. Tumor shrinkage of vestibular schwannomas after Gamma Knife surgery: results after more than 5 years of follow-up. *J. Neurosurg.* 2010;113(Special_Supplement):122-7.
10. van de Langenberg R, Hanssens PE, Verheul JB, van Overbeeke JJ, Nelemans PJ, Dohmen AJ, et al. Management of large vestibular schwannoma. Part II. Primary Gamma Knife surgery: radiological and clinical aspects. *J. Neurosurg.* 2011;115:885-93.
11. Boari N, Bailo M, Gagliardi F, Franzin A, Gemma M, del Vecchio A, et al. Gamma Knife radiosurgery for vestibular schwannoma: clinical results at long-term follow-up in a series of 379 patients. *J. Neurosurg.* 2014;121(Suppl_2):123-42.
12. Iorio-Morin C, AlSubaie F, Mathieu D. Safety and efficacy of Gamma Knife radiosurgery for the management of Koos grade 4 vestibular schwannomas. *Neurosurg.* 2015;78:521-30.