

Transcervical superior wedge resection (osteotomy) and fixation with contoured plate for the non-union of femoral neck fractures

Allah Rakhio Jamali,¹ Nadeem Ahmed,² Saeed Ahmed Shaikh,³ Muhammad Qasim Ali Samejo,⁴ Ghulam Mahboob⁵

Abstract

Study was conducted to determine the healing rate of non-union femoral neck fractures following a new transcervical superior based wedge resection and fixation with contoured plate. This study is based on a concept, that the presence of a residual part of the femoral neck on the trochanteric side of the non-union and removal of a wedge with a superior base not only converts shearing forces into compression forces but also provides fresh bone with an osteogenic potential. This is a descriptive case series 'one group pre-test post-test design', conducted from 2010 to 2016 with a sample size of 18, convenience sampling technique with a minimum follow up of 12 months.

Eighteen patients with a mean age of 32.44 ± 8.8 years were operated with transcervical wedge resection and fixation. However, only 14 completed a minimum follow up of twelve months. Thirteen (93%) patients achieved union while, one had stable fibrous union which later on developed avascular necrosis and underwent a total hip replacement. There was a mean shortening of 2.05 ± 0.4 cm. Seven (50%) had post-operative Lurch and 4 (28.6%) required shoe raise while 1 had low grade infection.

Keywords: Nonunion femoral neck, Transcervical Osteotomy, Union rate, Post-operative shortening, Avascular necrosis of femoral head.

<https://doi.org/10.5455/JPMA.19242>

Introduction

Fractures of the femoral neck are notorious and many of them end up in a non-union, despite optimal efforts. An overall non-union rate of 23% for femoral neck fractures was reported after a meta-analysis of 106 studies.¹ A significant rise in the non-union rate of the femoral neck fractures was observed with posterior communication (61.9%) and Pauwel's type III fractures (66.7%).² Another study reported 50% non-union with Pauwel's type III

fractures.³ There is no standard definition of non-union but Food and Drug Administration (USA).

(FDA) requires a minimum of nine months from the time of injury and no signs of healing during last 3 months; however, it fails to account for the neglected femoral neck fractures which always end up in a non-union.³ For the sake of this study, we have considered femoral neck fracture as non-union, if it has remained neglected for two months (or more) or resulted in a loss of position with implant loosening, persistent pain and inability to bear the weight after three months post fixation. Sandhu⁴ has described 3 stages of the non-union of the femoral neck fractures.

There are anatomical, biomechanical and technical reasons for this notoriety.^{2,3} Various options are being used to deal with the non-union of the femoral neck fractures. These include Pauwel's valgus osteotomy, transcervical osteotomy at Vastus ridge, intertrochanteric sliding osteotomy, vascular iliac grafts with fixation, fibular grafts with fixation, re-fixation and arthroplasty.

However, all techniques aimed at achieving union have some flaws including, altering the proximal femoral anatomy and posing problems for subsequent arthroplasty, failure to change the basic biomechanics of the fracture, additional surgical procedures and high failure rate. Hip arthroplasty has a proven record of success but is less ideal in younger population. In order to maintain the anatomy of proximal femur and convert shearing forces at fracture site into compression forces, a new technique of transcervical superior based wedge resection and fixation with a Contoured Dynamic Compression Plate along with bone grafting was developed and it was hypothesized that this will improve the union rate as compared to other techniques.

Concept and Biomechanical Aspects of Osteotomy

This procedure is based upon a concept, that there is a residual part of femoral neck on the trochanteric side in cases of non-union of mid cervical or sub capital fractures. By removing a triangular wedge with approximately 1 cm base on the superior side, the shear forces at the fracture side can be converted into compression forces while at

¹⁻⁴Department of Orthopedics, Jinnah Post Graduate Medical Center, Karachi,

⁵Department of Orthopedics, Sir Syed Medical University, Karachi, Pakistan.

Correspondence: Allah Rakhio Jamali. Email: jamalimir1@gmail.com

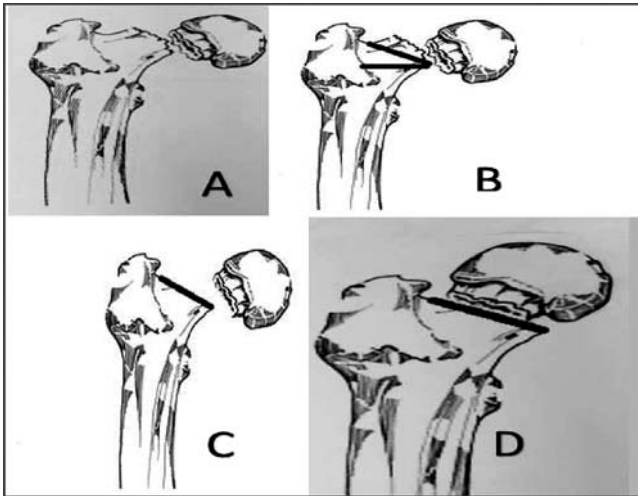


Figure-1: (A) Showing an outline of the nonunion of the femoral neck. (B) Proposed wedge at an angle of 30 degrees, though 30-45 degrees can be accepted (C) Removal of wedge. (D) Stable reduction with a Pauwel's angle of 30 degrees after removal of a wedge.

the same time allowing refreshing of the femoral head side with micro oscillating saw or fine osteotome and removing any fibrous tissue present (Figure-1). Primary target is to achieve a Pauwel's angle of 30° - 45°. The size of wedge may vary with diameter of the femoral neck, availability of bone stock on the superior aspect of the neck on the trochanteric side and existing Pauwel's angle of nonunion. Osteotomy provides large contact area of healthy bone as well as some bone graft without altering the shape of the proximal femoral shaft. Additional procedure of obtaining a bone graft is avoided in most cases, as graft obtained locally may suffice.

Accurate reduction is achieved under direct vision and compression is achieved by the two cancellous screws through contoured broad plate. Additional screws (one or two) provide further stability to the construct.

By reducing the lever arm, the amount of forces acting at the non-union site are decreased but may result in decreased abductor power along with some shortening as compared to the normal side. However, some lengthening is achieved by valgus reduction and correction of the overlap from pre-operative status. The main advantages of this procedure include, dealing with local pathology directly, achieving bony stability, providing fresh bone with osteogenic potential as well as some bone graft, reducing level arm, thus forces acting upon hip and maintaining proximal femoral anatomy. However, it does cause some shortening.

Case Series

This was a descriptive case series 'one group pre-test and

post-test design' study, conducted at the Jinnah Postgraduate Medical Centre (JPMC) and Anklesaria nursing home from 2010 to 2016. Sample size was 18 and a convenience sampling technique (subject to voluntary consent of patient after discussing pros & cons of the procedure and alternate options) was used.

The inclusion criteria for this study were, age 50 years or less, neglected fracture of two months or more, loss of fixation, implant loosening, persistent pain and inability to bear weight after fixation, good quality bone and non-union of stage 1, 2 and 3 according to Sandhu's classification.⁴

The exclusion criteria were, age over 50, evidence of avascular necrosis (AVN) on X-rays, severe osteopenia, poor quality of head fragment due to loosening/migration of previous implants, wound infection following previous surgery and steroid or other immunosuppressive therapy.

Confounding variables were, adherence to post-operative follow up/rehabilitation, quality of fixation and stability, vascular insult during surgery and healing potential of the freshened bone ends.

Surgery was performed under anaesthesia (spinal or general) and prophylactic antibiotic coverage on a radiolucent table with C. arm control. Traction table can be used as it provides better imaging for the reduction and fixation, but interferes with osteotomy by limiting the movements. Traction was kept loose to allow rotation and adduction/abduction for facilitating the osteotomy.

Hip was approached through Watson Jones methods. Capsulotomy was done utilizing anterior and horizontal limbs of the Z type capsulotomy. Non-union site was cleared up of fibrous tissue/loose bodies etc. Limb was then externally rotated to see the status of the distal non-union end and length of the neck left superiorly. A superiorly based wedge (approximately 1cm) was removed to achieve an angle of 30°-45°, depending upon the residual neck on the superior side. On the femoral head side, only thin sclerotic shell is removed with mini oscillating saw or a thin osteotome. Sometimes it is necessary to stabilize femoral head with a K. wire to facilitate freshening of the bone on this end. No bone was removed inferiorly except in one case with fire arm injury where some bone on femoral head side was removed to achieve stable fixation (Figure-2A)

A six hole broad dynamic compression plate was contoured to fit over greater trochanter and proximal femur. Fracture was reduced in slight valgus position under direct visualization by the abducting leg around

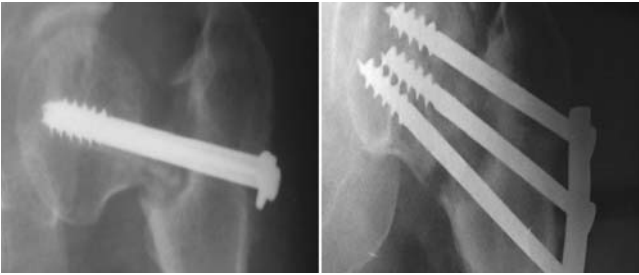

Figure-2A: Pre-Operative and post- operative X-rays.

30°-45° and temporarily stabilized with a K. wire crossing acetabulum. Reduction was rechecked with a C.arm. Once reduction was confirmed, drill holes were made (two through the plate and one or two outside the plate to 5mm from sub-chondral bone). Non-union was stabilized by compression with cancellous screws achieved by manually pressing the trochanter and opposite side of the pelvis. Plate was stabilized by three cortical screws through the femoral shaft. Quality of reduction/screws size and position was rechecked through a C arm and X-rays, minor adjustments made.

On plain operating table, fracture was reduced by direct visualization and was temporarily stabilized with three K.wires up to the sub-chondral bone. The quality of reduction and position was confirmed by a C arm. Lateral view was obtained by gently flexing hip up to 90° and slightly abducting it.

Below knee back slab was applied to restrict the activities for one month. Patients were given post-operative intravenous antibiotics (for 72 hours) and were discharged on the third day. Sitting was allowed from the next day onwards. Non weight bearing was allowed after one month. Partial weight bearing was allowed after 2 months post operatively, progressing gradually to full weight bearing depending upon the radiological progress. This conservative approach at rehabilitation was due to less ideal quality of the bone and variable stability. This can be modified with a good quality of the bone and fixation. The X-ray assessment was done monthly until union was evident or otherwise. Minimum follow up required for this study was 12 months.

Results were evaluated for the union rate, time taken for the union, limb shortening and complications. Eighteen patients (16 male and 2 females) with a mean age of 32.44±8.8 (13-45 years) were included in this study. Thirteen (72.21%) had history of road traffic accident, 3 (16.7%) had fall and 1 each with firearm injury and metabolic bone disease. Fifteen (83.3%) had previous

failed surgery, while 3 were neglected fractures.

Patients with metabolic bone disease also had significant bowing of the femoral shaft requiring correction with a wedge resection and fixation with a long DCP. The mean time between injury and surgery was 3.69±1.6 months (2-8 months). Thirteen (72.2%) patients has stage II non-union, 4 (22.2%) had stage 1 and 1 patient had stage III (5.55%).

Post operatively, mean Pauwel's angle achieved was 35.6°±2.9, [Pauwel's 1 in 4 (22.3%) and Pauwel's 2 in 14 (77.7%)]. The post-operative neck shaft angle achieved was in range of 130° -138° (average 136°). None of the 18 patients showed loss of position during the period they were followed. Two patients were lost to follow up and another two had not completed minimum one year follow up. Hence, these 4 cases were not included in the final results. The mean follow up was 16.17±8.35 months (3-4 months).

Of the remaining 14 patients, 13 (93%) achieved bony union while one had stable fibrous union and was able to walk without support for 2 years during the follow up. No loss of position was evident in this patient but later on he developed significant pain due to avascular necrosis (Figure-3). He underwent hip replacement for persistent pain.

The mean period for healing was 7.53± 2.3 months. There

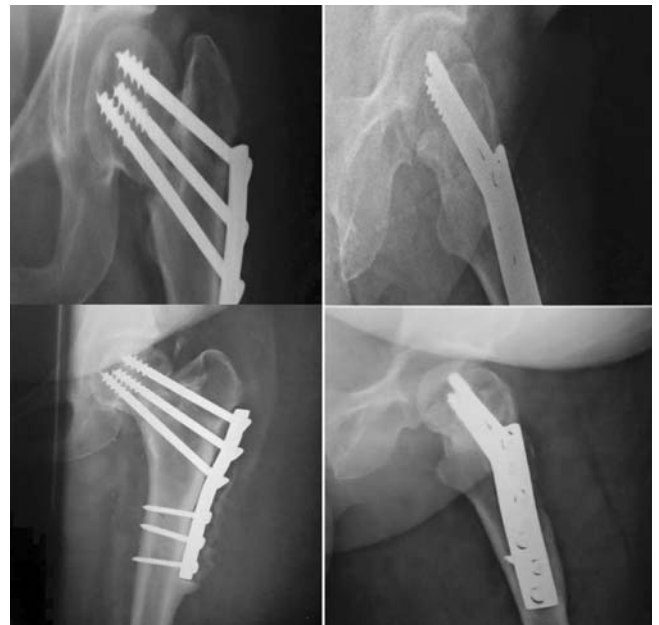

Figure-2B: Post-Operative X-rays at one and two year follow up showing healing. Periosteal new bone is seen over plate due to low grade infection which cleared after removal of implant. This patient required removal of bone from inferior part of neck on femoral head side.

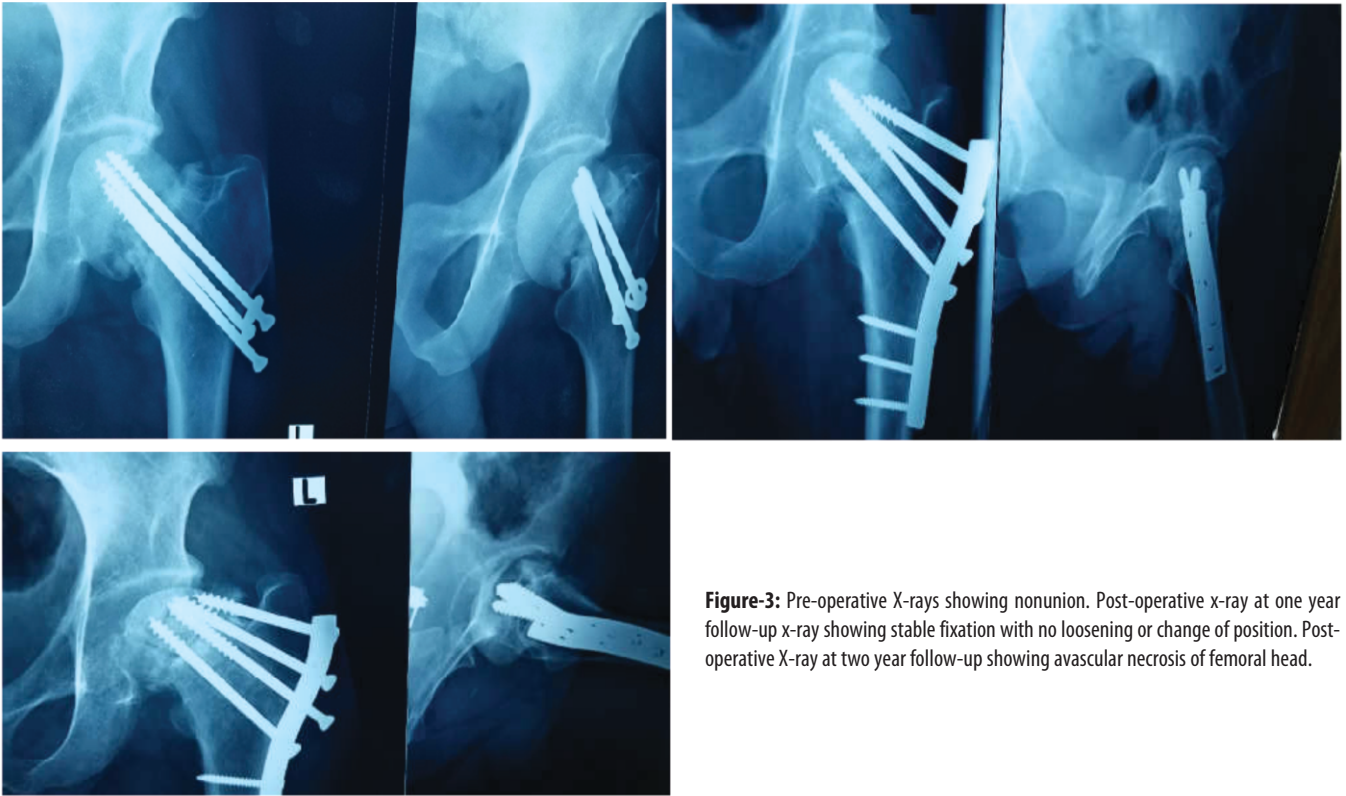


Figure-3: Pre-operative X-rays showing nonunion. Post-operative x-ray at one year follow-up x-ray showing stable fixation with no loosening or change of position. Post-operative X-ray at two year follow-up showing avascular necrosis of femoral head.

was a mean shortening of 2.05 ± 0.4 cm. Seven (50%) out of 14 patients had post-operative lurch and 4 (28.6%) of them required a shoe raise. Five (35.7%) patients had pain in the trochanteric region partly explained by backing out of the screws. One patient had pain in the groin with avascular necrosis and stable fibrous union. Another patient had low grade infection at the tip of the plate though non-union had healed (Figure-2B). One patient with stage 3 non-union presented with a challenging situation as head fragment was small and even 16mm threaded screws would just fit from subchondral region to the non-union site. Furthermore, with resorption of the neck and additional cut due to osteotomy, the hip joint space appeared widened with an appearance of a subluxation. However, the fixation achieved was stable and maintained during the 3 months follow up. He did not return back for further follow ups. He had a shortening of 3cm which was more than what was observed in all other patients.

We tried to analyse the results on Harris hip score⁵ but encountered significant problems. The major problems in our series were shortening /limp and pain at the trochanteric region due to backing out of the screws. Range of motion at hip was not a major issue. We assessed results using a Harris score keeping in mind the limitations. Ten (71.4%) patients scored >90 (excellent), 3 (21.4%)

scored 80-90 (good) and 1 (7.14%) was below 70 (poor).

Discussion

Variety of factors contribute to the non-union of the femoral neck fractures. The quality of reduction is only consistent with technical factors influencing the final outcome measure.

Non-union of the femoral neck fractures is a challenging problem with no single satisfactory solution as all of them carry additional unwanted outcome measures such as shortening, limp, avascular necrosis, secondary osteoarthritis of the hip, revision surgery and additional procedures.^{1,2,4,6,7} This is in part due to the absorption of neck, small size of the head fragment, poor circulation and risk of avascular necrosis, poor healing potential, damage to the bone due to previous fixation, vertical shear line/large shear forces and problems inherent with different procedures etc. Solutions can be broadly divided into two groups including attempts to achieve union and hip replacement surgery. The primary target to achieve union is by converting shear stress into compressive stress along with a stable fixation and promotion of the bone healing by bone grafting.

Noda et al⁸ reported that the peak Von Mises stresses at

the fracture site along lateral femoral neck were 140 Mpa (Mega Pascal unit) in Powell I configuration as compared to 16 and 8 Mpa in Powell II and III. Medially, the peak Von Mises stresses were reported to be 35, 50 and 130 Mpa (mega pascal unit) in Powell I, II and III respectively. The stresses on the medial femoral neck in Powell III act as traction stresses leading to displacement and non-union. A possible explanation for these traction stresses in Powell III may be the failure of calcar to effectively serve as a fulcrum during loading.

Sandhu⁴ described three stages of non-union considering various factors and suggested guidelines to achieve union in stage I and stage II. Sandhu⁴ also stressed upon the importance of the size of the proximal fragment. A size less than 2.5 cm was associated with a poor outcome. Magu et al⁹ reported that the absolute head volume of less than 43mm was associated with high failure rates, yet the average head volume for females was only 40.8mm. 77.2% of patients in this study had stage II non-union. However, we did not measure absolute femoral head volume.

Femoral osteotomies improve the biomechanics at non-union site and healing. They are either valgus osteotomies (Pauwel's or its modifications) or medial displacement osteotomy at subtrochanteric or intertrochanteric level. Valgus osteotomy is more efficient than displacement osteotomy in converting shear into compression forces. It also corrects rotation and improves limb length/abductor power. The advantages and disadvantages of this transcervical osteotomy are discussed in the biomechanical aspects of this osteotomy but a major disadvantage observed was shortening.

The objective to convert Pauwel III configuration to Pauwel I, may require a 40°-50° wedge. The ideal post-operative angle to eliminate all shearing forces is 20° but too much valgus osteotomy has its own problems. Sharma et al¹⁰ aimed to achieve a Pauwel's angle of 30° or less but had difficulty in precise measurements, so he removed 30° wedge graft and observed an average change of 25° in the fracture inclination angle with sliding sub trochanteric osteotomy; hence, recommending 25°-30° wedge, as more than 30° may compromise the blood supply. Gavaskar et al¹¹ achieved a post-operative angle of 35° from preoperative angle of 67°. In this series, the average post-operative fracture angle of 35°±2.9 was achieved with the removal of a 1cm wedge approximately with a slight valgus reduction.

A variable union rate (55%-100%) following osteotomy has been reported.¹ Lateef¹² achieved a union in all the patients in a similar osteotomy at vastus ridge and fixation

with Tupman plate. Magu et al⁷ achieved 91.6% union rate with Powell's osteotomy and limb length equalization in 83%, whereas, Sharma et al¹⁰ achieved a union in 82% of the cases. The healing period for non-union of the femur neck with osteotomy has shown a wide variation ranging from 11 weeks to 20 weeks. In this series, 93% of the cases achieved bony union while, one had stable fibrous union along with avascular necrosis of the femoral head who underwent total hip replacement. The average period for healing of non-union was seven months.

Position achieved at reduction is significant factor in the development of an AVN, as valgus reduction causes kinking of the lateral epiphyseal vessels and the tethering of the medial epiphyseal vessels. Valgus and rotatory malposition may cause avascular necrosis. Similarly, posterior lateral approach causes a reduction in the blood supply of the femoral head. The rate of avascular necrosis following surgery for the non-union of the neck has been reported to be 2.94%-14.3% with different procedures. These studies had a small sample size, making it difficult to arrive at an accurate conclusion. Similarly, in our study one case developed avascular necrosis of the femoral head (7.2%).

Limb length improves following Pauwel's valgus osteotomy for the non-union of the femoral neck. Magu et al⁷ achieved limb length equalization in 35 (92.11%) out of 38 patients. Lateef¹² achieved limb length equality in all the patients. Siavashi¹³ reported a mean residual shortening of 1 cm following valgus osteotomy.

Schwartzmann¹⁴ reported a mean reduction of 8.9mm (64.8mm as compared 73.77 mm in normal) in abductor length following Valgus osteotomy and 13.2% of the patients displayed a Trendelenburg gait. Gavaskar¹¹ reported abductor lurch in 37% of the cases following valgus osteotomy, whereas, Magu⁷ reported in 17.4% of the cases.

A mean shortening of 2.05±0.4cm was observed post operatively in this series. Half of the patients had post-operative lurch and 4 required a shoe raise. This was a major drawback of this study. It can be explained by pre-operative neck absorption in stage II and III non-union and removal of the wedge. Limb lengthening at later stage can correct it, but is a time consuming procedure.

A postoperative neck shaft angle from 104° to 144° is reported in the literature, whereas, in this series it ranged between 130°-138° (average 136°).

Lateef¹² reported a 10°-20° restriction of the flexion in 60% the cases. In this series the average hip flexion was from 0-120°. Two patients had terminal flexion restricted.

Five patients had restricted external rotation (0 -25°).

Schwartzmann¹³ reported 39% excellent and 56% good Harris hip score following the valgus intertrochanteric osteotomy. Siavashi¹² reported a mean Harris score of 89 after modified valgus osteotomy. Magu et al⁷ reported a Harris score of 80 - 100 in 83.3% of the patients. In this series 92.8% cases achieved good or excellent Harris score, however the trochanteric pain or shortening was of concern while considering limitations.

It can be concluded that the transcervical osteotomy at a non-union site does address some of the issues by dealing with the problem locally, correcting Powell's angle, inducing osteogenesis and reducing lever arm but adds another problem of shortening and lurch. Limb length discrepancy was partially corrected but may require limb lengthening in selected patients, though we did not do it. However, raised shoe was given to 4 patients. This procedure does improve healing rate/stability but additional capsulotomy may add vascular harm. Further work needs to be done in this regard. This osteotomy can be very useful in younger patients with stage I and II non-union of the femoral neck.

Disclaimer: None to declare.

Conflict of Interest: None to declare.

Funding Sources: None to declare.

References

1. Roshan A, Ram S. The neglected femoral neck fracture in young adults: review of a challenging problem. *Clin Med Res*. 2008; 6:33–9.
2. Upadhyay A, Jain P, Mishra P, Maini L, Gautum VK, Dhaon BK. Delayed internal fixation of fractures of the neck of the femur in young adults. A prospective, randomised study comparing closed and open reduction. *J Bone Joint Surg Br*. 2004; 86:1035–40.
3. Raaymakers EL. Fractures of the Femoral Neck: A review and Personal Statement. *Acta Chir Orthop Traumatol Cech*. 2006; 73:45–59.
4. Sandhu HS. Management of fracture neck of femur. *Indian J Orthop*. 2005; 39:130–6.
5. Harris WH. Traumatic arthritis of the hip after dislocation and acetabular fractures, treated by mold arthroplasty. An end result study using a new method of result evaluation. *J Bone Joint Surg Am*. 1969, 51:737–55.
6. Jain AK, Mukunth R, Srivastava A. Treatment of neglected femoral neck fracture. *Indian J Orthop*. 2015; 49:17–27.
7. Magu NK, Rohilla R, Singh R, Tater R. Modified Pauwels' intertrochanteric osteotomy in neglected femoral neck fracture. *Clin Orthop Relat Res*. 2009; 467:1064–73.
8. Jain AK, Mukunth R, Srivastava A. Treatment of neglected femoral neck fracture. *Indian J Orthop*. 2015;49:17–27.
8. Noda M, Saegusa Y, Takahashi M, Tezuka D, Adachi K, Naoi K. Biomechanical study using the finite element method of internal fixation in Pauwels type III vertical femoral neck fractures. *Arch Trauma Res*. 2015; 4:e23167.
9. Magu NK, Magu S, Rohilla RK, Batra A, Jaipuria A, Singh A. Computed tomographic evaluation of the proximal femur: A predictive classification in displaced femoral neck fracture management. *Indian J Orthop*. 2014; 48:476–83.
10. Sharma, M, Sood, LK, Kanojia, RK, Sud, A. Valgus osteotomy for nonunion fracture neck femur. *Indian J Orthop*. 2004; 38:88–91.
11. Gavaskar AS, Chowdary NT. Valgus sliding subtrochanteric osteotomy for neglected fractures of the proximal femur; surgical technique and a retrospective case series. *J Orthop Surg Res*. 2013; 8:4.
12. Latif A, Mukhopadhyay K, Bhattacharyya A, Roy SK, Kumar S. Transcervical osteotomy with modified Tupman plate for fracture neck femur--a new concept. *J Indian Med Assoc*. 2011; 109:424–5.
13. Siavashi B, Golbakhsh MR, Savadkoobi DG. Modified Valgus Osteotomy for Treatment of Femoral Neck Fracture Non-Union. *Orthop Muscul Syst*. 2012; 1:110.
14. Schwartzmann CR, Spinelli LF, Yépez AK, Boschini LC, Silva MF. Femoral neck non-union treatment by valgus intertrochanteric osteotomy. *Acta Ortop Bras*. 2015; 23:319–22.