

Clinicopathological characteristics of patients with surgically resected lung cancer having tumours harboring anaplastic lymphoma kinase fusion protein

Bo Chen,¹ Zhiming Jiang,² Chenghui Li,³ Hongyang Lu⁴

Abstract

Platinum-based postoperative adjuvant chemotherapy is the standard treatment for stage II-IIIa non-small cell lung cancer (NSCLC). Novel therapeutic modalities are required to improve the outcome of an early stage NSCLC. Patients with advanced NSCLC having anaplastic lymphoma kinase (ALK) fusion protein are sensitive to ALK inhibitors such as crizotinib. This study aimed to further explore the clinicopathological characteristics of postoperative patients with early-stage lung cancer harboring ALK fusion protein and provide a basis to carry out postoperative adjuvant crizotinib treatment. A total of 19 patients were retrospectively reviewed, and the clinicopathological parameters and follow-up data were collected and analysed. ALK rearrangements easily exist in male and in non-smokers patients with adenocarcinoma histology. Brain metastasis occurs easily, and prognosis of patients with stage IIIa is relatively poor. Detection of ALK fusion protein should be a routine testing. Postoperative adjuvant crizotinib treatment for patients with stage IIIa NSCLC harboring ALK fusion protein is promising.

Keywords: ALK, Disease-free survival, Lung cancer.

<https://doi.org/10.5455/JPMA.3142>

Introduction

Lung cancer, including non-small cell lung cancer (NSCLC) and small cell lung cancer (SCLC), is the most common malignancy and the leading cause of cancer-related mortality worldwide. Previous large-scale studies have established platinum-based chemotherapy as the standard postoperative adjuvant treatment in stage II-IIIa NSCLC. The usefulness of excision repair cross-complementation group 1 in guiding platinum-based chemotherapy in NSCLC is limited.¹ Negative results were obtained in the randomised phase III trial, studying the role of bevacizumab in adjuvant chemotherapy. Novel

¹Department of Pathology, ^{2,4}Zhejiang Key Laboratory of Diagnosis & Treatment Technology, ³Department of Thoracic Medical Oncology, Zhejiang Cancer Hospital, China.

Correspondence: Hongyang Lu. Email: luhy@zjcc.org.cn

therapeutic modalities are required to further improve outcome for patients with early stage NSCLC.

Echinoderm microtubule-associated protein-like4 (EML4)-anaplastic lymphoma kinase (ALK) fusion protein is a dominant oncogenic protein present in approximately 4% to 5% of all cases of NSCLC.² Several other fusion partners, except EML4, have also been observed for ALK. The 5-year risk of progression or recurrence has doubled for patients with ALK-positive compared to ALK-negative.³ ALK inhibitors have become the first line of treatment in advanced NSCLC patients with ALK rearrangements.

This study aimed to further explore the clinicopathological characteristics of postoperative patients with surgically resected early-stage lung cancer, harboring ALK fusion protein and provide a basis to carry out the postoperative adjuvant crizotinib treatment on these patients. A total of 19 patients were included in this study, and the clinicopathological parameters and follow-up data were collected and analysed.

Case Series

A total of 19 patients with lung cancer harboring the ALK fusion protein were reviewed at the Zhejiang Cancer Hospital in China between January 2013 and December 2014. They were diagnosed by immunohistochemistry (IHC) using a highly sensitive anti-ALK (D5F3) rabbit monoclonal primary antibody (Roche, Inc., AZ, USA) with an OptiView Amplification Kit and an OptiView DAB IHC Detection Kit (Roche, Inc.). All specimens were obtained from resected tumors of lung cancer. The pathological diagnosis was based on the standard criteria defined by the World Health Organisation. The stages were defined according to the eighth edition of TNM classification for lung cancer. Specimens were obtained from 8 female and 11 male patients, ranging in age from 33 to 71 years old. The median age of the patients was 57 years and the median pack-years of smoking history was 30. The pathological type, stages and smoking history are shown in Table-1. This study was approved by the Medical Ethical Committee of the Zhejiang Cancer Hospital.

A 66-year old male who was a heavy smoker was

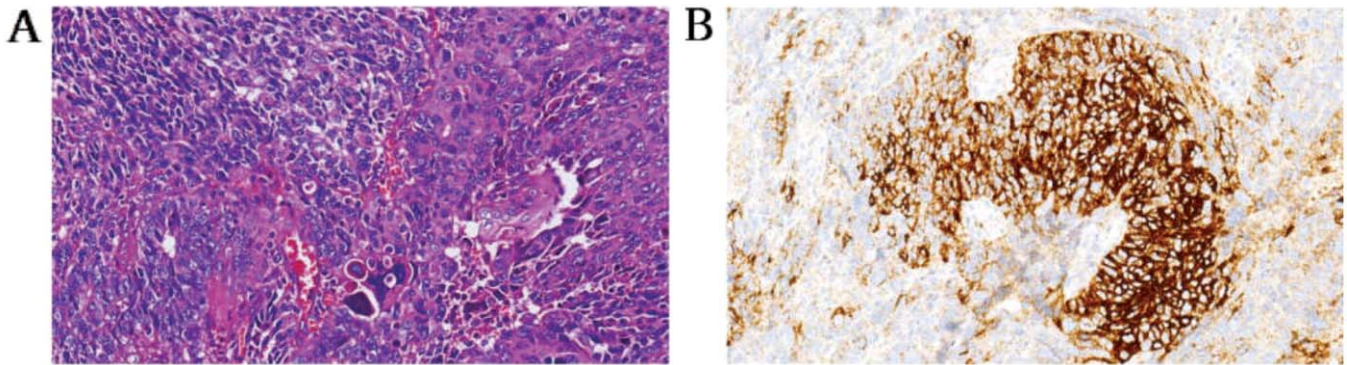


Figure-1: Patient with small cell lung cancer (SCLC) combined with squamous cell carcinoma having tumors harboring ALK fusion protein. (A) HE staining of the tumor; (B) ALK fusion protein (positive). ALK: Anaplastic lymphoma kinase; HE: hematoxylin-eosin.

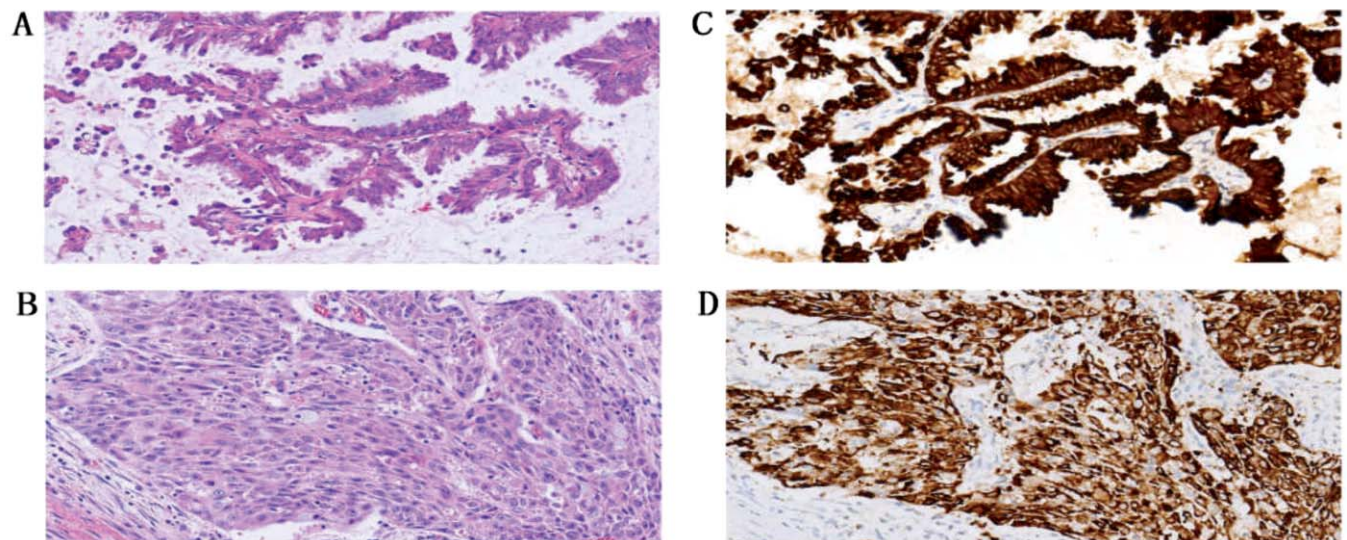


Figure-2: Patient with two tumors including lung adenocarcinoma and lung squamous cell carcinoma harboring ALK fusion protein. (A) HE of lung adenocarcinoma; (B) HE of lung squamous cell carcinoma. (C) ALK fusion protein positive for lung adenocarcinoma; (D) ALK fusion protein positive for lung squamous cell carcinoma. ALK: Anaplastic lymphoma kinase; HE: hematoxylin-eosin.

diagnosed with SCLC combined with squamous cell carcinoma at stage IA3 (T1cN0M0) who had received four cycles of etoposide combined cisplatin (Figure-1). Another 44-year old non-smoker female patient with two tumors including lung adenocarcinoma (T1bN0M0, IA2) and lung squamous cell carcinoma (T2aN0M0, IB) received four cycles of adjuvant chemotherapy with gemcitabine combined with cisplatin. ALK positive was detected in both adenocarcinoma and squamous cell carcinoma in this patient (Figure-2). All other patients with stages IA and IB lung adenocarcinoma did not receive adjuvant chemoradiotherapy. Patients with stages IIA, IIB and IIIA received three or four cycles of adjuvant chemotherapy with gemcitabine combined with cisplatin, or pemetrexed combined with cisplatin,

including one patient with stage IIIA who received adjuvant thoracic radiotherapy.

At the follow-up deadline of May 10, 2018, no patients had been lost. The survival time was calculated from the date of pathological diagnosis.

ALK-positive lung cancer easily occurred in males, and non-smokers patients with adenocarcinoma. The follow-up results of all the patients are given in Table-2. Six patients relapsed, of which three of them due to brain metastasis: one patient with lung adenocarcinoma (pT1bN0M0, IA2) had brain metastasis 23 months after surgery; another patient with adenocarcinoma and squamous cell carcinoma had lung metastasis 23 months after surgery; the third patient with lung adenocarcinoma

Table-1: Clinicopathological features of all patients (n=19).

	Cases
Stage	
IA1/IA2/IA3	0/5/2
IB	3
IIA	1
IIB	6
IIIA	3
Pathological type	
Adenocarcinoma	15
Squamous cell carcinoma	4
SCLC combined squamous cell carcinoma	1
Smoking	
Non-smokers	11
Light smokers	0
Moderate smokers	1
Heavy smokers	7
SCLC small cell lung cancer	

Table-2: The results of follow-up for all patients (n=19).

Stage	Follow-up
Stage I	
Case 1 (IA2)	Occurred brain metastasis 23 months after surgery
Case 2 (IA3)	No relapse (>46months)
Case 3 (IA2)	No relapse (>46months)
Case 4 (IA2)	No relapse (>45months)
Case 5 (IA3)	No relapse (>45months)
Case 6 (IA2)	No relapse (>42months)
Case 7 (IB)	No relapse (>52months)
Case 8 (IB)	No relapse (>50months)
Case 9 (IB, IA2)*	Occurred lung metastasis 23 months after surgery
Stage II	
Case 1 (IIA)	No relapse (>47months)
Case 2 (IIB)	No relapse (>54months)
Case 3 (IIB)	No relapse (>44months)
Case 4 (IIB)	No relapse (>55months)
Case 5 (IIB)	No relapse (>50months)
Case 6 (IIB)	Occurred lymph node metastasis 39 months after surgery
Case 7 (IIB)	Occurred brain metastasis 5 months after surgery
Stage III	
Case 1 (IIIA)	Occurred adrenal metastasis 7 months after surgery
Case 2 (IIIA)	Occurred brain metastasis 9 months after surgery
Case 3 (IIIA)	No relapse (>45months)

*The stage for squamous cell carcinoma is pT2aN0M0(1B), and the stage for adenocarcinoma is pT1bN0M0(IA2).

(pT2aN1M0, IIB) had lymph node metastasis 39 months after surgery; one patient with lung squamous cell carcinoma (pT2aN1M0, IIB) had brain metastasis 5 months after surgery; another patient with lung adenocarcinoma (pT3N1M0, IIIA) had adrenal metastasis 7 months after surgical resection, and the sixth patient with lung adenocarcinoma (pT2aN2M0, IIIA) had brain metastasis 9

months after surgical resection.

Discussion

In the present cohort, IHC (Ventana) was used in all the patients with lung cancer to detect the status of ALK. Most of the patients enrolled in our study were adenocarcinoma and non-smokers, which is consistent with literature.⁴ Gender percentage and median age in the cohort were consistent with Li's report.⁵ A case of SCLC combined with adenocarcinoma harboring EML4-ALK fusion protein and an exon 19 EGFR mutation in each histological component was reported.⁶ In the present cohort, one patient with SCLC combined with squamous cell carcinoma harbored ALK rearrangement. ALK-rearranged squamous cell lung carcinomas are rare tumors that can also respond to anti-ALK-targeted therapy.⁷ It may be imperative to identify all patients with NSCLC harboring ALK translocations because the ALK TKI crizotinib is highly effective in ALK-translocated patients, especially in those who have never smoked.

Patients with lung cancer having ALK rearrangement can be treated more successfully with ALK inhibitors, such as crizotinib, alectinib and ceritinib, than with chemotherapy. Crizotinib was superior compared to the standard first-line pemetrexed-plus-platinum chemotherapy performed on patients with previously untreated advanced ALK-positive NSCLC.⁸ Compared with chemotherapy, crizotinib demonstrated a significantly higher intracranial disease control rate in patients with brain metastasis.⁹ The overall survival of patients with ALK-positive NSCLC is less than that of ALK-negative patients following surgical resection.³ In our retrospective study, two of three patients with ALK-positive stage IIIA lung cancer relapsed quickly and early, despite receiving adjuvant chemotherapy. The administration of gefitinib following pemetrexed and carboplatin adjuvant therapy showed significant improvement in disease-free survival (DFS) in patients with resected stage IIIA-N2 NSCLC harboring EGFR mutations (39.8 vs 27.0 months, P=0.014).¹⁰ It was speculated that the use of crizotinib could result in an improvement in DFS and decrease in brain metastasis for ALK positive NSCLC with stage IIIA. In addition, the main limitation of our study is the relatively small sample size enrolled due to the low frequency of ALK rearrangement in lung cancer. Owing to the retrospective nature of this study, a constructed prospective trial may be needed in the future.

Conclusion

In conclusion, all lung adenocarcinomas and lung squamous cell carcinomas should be examined for ALK fusion protein. Brain metastasis occurs easily and the prognosis for patients with stage IIIA is not satisfactory. The

use of ALK inhibitor in patients with ALK-positive NSCLC following surgical resection is a potential therapeutic option to improve the outcome. Postoperative adjuvant crizotinib treatment for patients with NSCLC, especially those with stage IIIA harboring the ALK fusion protein, is promising and needs further evaluation.

Disclaimer: None to be declared.

Declaration of Interest: The authors declare no potential or real conflicts of interest.

Sources of Funding: This work was supported by Zhejiang province public welfare and technology application project of China (2016C33118), and the 1022 Talent Training Program of Zhejiang Cancer Hospital. Financial sponsors played no role in the design, execution, analysis and interpretation of data or writing of the study.

References

1. Thomale J, Le Chevalier T, Dunant A, Shepherd FA, Tsao MS, Graziano S, et al. ERCC1 isoform expression and DNA repair in non-small-cell lung cancer. *N Engl J Med.* 2013; 368:1101-10.
2. Soda M, Choi YL, Enomoto M, Takada S, Yamashita Y, Ishikawa S, et al. Identification of the transforming EML4-ALK fusion gene in non-small-cell lung cancer. *Nature.* 2007; 448:561-6.
3. Yang P, Kulig K, Boland JM, Erickson-Johnson MR, Oliveira AM, Wampfler J, et al. Worse disease-free survival in never-smokers with ALK+ lung adenocarcinoma. *J Thorac Oncol.* 2012; 7: 90-7.
4. Ma H, Yao WX, Huang L, Jin SH, Liu DH, Liu Y, et al. Efficacy of D5F3 IHC for detecting ALK gene rearrangement in NSCLC patients: a systematic review and meta-analysis. *Oncotarget.* 2016; 7:70128-42.
5. Li T, Maus MK, Desai SJ, Beckett LA, Stephens C, Huang E, et al. Large-scale screening and molecular characterization of EML4-ALK fusion variants in archival non-small-cell lung cancer tumor specimens using quantitative reverse transcription polymerase chain reaction assays. *J Thorac Oncol.* 2014; 9:18-25.
6. Toyokawa G, Taguchi K, Ohba T, Morodomi Y, Takenaka T, Hirai F, et al. First case of combined small-cell lung cancer with adenocarcinoma harboring EML4-ALK fusion and an exon 19 EGFR mutation in each histological component. *J Thorac Oncol.* 2012; 7:e39-e41.
7. Vergne F, Quéré G, Andrieu-Key S, Descourt R, Quintin-Roué I, Talagas M, et al. ALK-rearranged squamous cell lung carcinoma responding to crizotinib: A missing link in the field of non-small cell lung cancer? *Lung Cancer.* 2016; 91:67-9.
8. Solomon BJ, Mok T, Kim DW, Wu YL, Nakagawa K, Mekhail T, et al. First-line crizotinib versus chemotherapy in ALK-positive lung cancer. *N Engl J Med.* 2014; 371:2167-77.
9. Solomon BJ, Cappuzzo F, Felip E, Blackhall FH, Costa DB, Kim DW, et al. Intracranial Efficacy of Crizotinib Versus Chemotherapy in Patients With Advanced ALK-Positive Non-Small-Cell Lung Cancer: Results From PROFILE 1014. *J Clin Oncol.* 2016; 34:2858-65.
10. Li N, Ou W, Ye X, Sun HB, Zhang L, Fang Q, et al. Pemetrexed-carboplatin adjuvant chemotherapy with or without gefitinib in resected stage IIIA-N2 non-small cell lung cancer harbouring EGFR mutations: a randomized, phase II study. *Ann Surg Oncol.* 2014; 21:2091-6.