

Polymicrobial Cerebral Abscess in a Child with Uncorrected Tetralogy of Fallot

Yusra Shafquat, Mohammed Zeeshan, Saeeda Chandio, Zain Mumtaz

Abstract

Aggregatibacter aphrophilus and Beta haemolytic *Streptococci* Lancefield group F are part of the normal oral flora and are known to cause endocarditis, sinusitis, empyema, meningitis and septic arthritis. They are now emerging as a cause of brain abscess particularly in patients with congenital heart diseases. We report a case of a 10-year-old boy with Tetralogy of Fallot (TOF), who presented with fever, headache and drowsiness. Culture yielded the growth of *Aggregatibacter aphrophilus* and Beta hemolytic *streptococci* Lancefield group F. He became clinically stable after treatment with ceftriaxone.

Keywords: Infective endocarditis, tetralogy of Fallot, *Aggregatibacter aphrophilus*, brain abscess.

Introduction

The prevalence of Congenital heart diseases (CHD) in last decade is estimated to be 9 per 1,000 live births. In the three continents of Asia, Europe and North America, the highest prevalence has been found among Asian children with a CHD prevalence of 9.3 per 1,000 live births. Among the distribution of the most common eight types of CHD, the prevalence of Tetralogy of Fallot (TOF) is 5%.¹ Cerebrovascular accident and cerebral abscess are the most commonly anticipated complication in patients with uncorrected TOF.² *Streptococcus milleri* group is the most common microorganism of brain abscess with CHD.³ *Aggregatibacter aphrophilus* belongs to HACEK group and is commonly associated with infective endocarditis, however it also has pyogenic manifestations, including brain abscess.⁴

Case Report

A 10-year-old boy was admitted in a private hospital of Karachi, Pakistan with a history of fever and headache for 2 weeks and drowsiness for 2 days. The patient was a known case of Tetralogy of Fallot (FOT) with no history of surgical correction. On admission, the patient had a temperature of 39°C. Initial blood cultures showed group F *streptococci*. A tomography scan of the head showed a

Aga Khan University Hospital, Karachi, Pakistan.

Correspondence: Mohammed Zeeshan. e-mail: mohammed.zeeshan@aku.edu

ring enhancing lesion in the left frontal lobe surrounded by oedema. Craniotomy was performed and the purulent specimen was sent to microbiology in November 2017. Transthoracic echocardiogram showed no vegetation. Transesophageal echocardiogram was not performed because of unavailability of paediatric instruments. The gram stain of the specimen showed numerous pus cells, numerous gram positive cocci in chains and pleomorphic gram negative coccobacilli. Chocolate agar, Sheep blood agar (aerobic and anaerobic), MacConkey agar and Robertson cooked meat broth were set. Chocolate agar showed growth of small, round, convex slightly yellow pigmented colonies with entire margin [Figure 1(a)] and beta haemolytic small colonies of streptococci were observed on Sheep blood agar which was group F on Lancefield grouping [Figure 1(b)]. *Streptococcus* group F was susceptible to penicillin, ceftriaxone, clindamycin, erythromycin and vancomycin. The gram negative cocco-bacilli were oxidase negative, catalase negative and grow without X and V factors. The

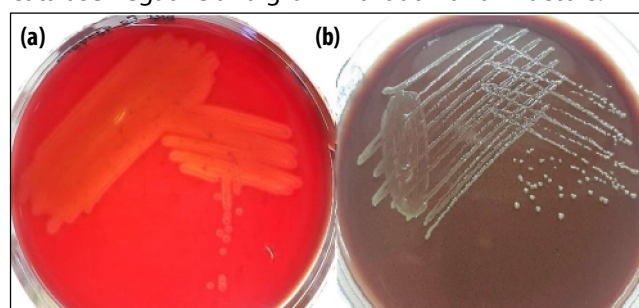


Figure-1: (a) Growth of Beta haemolytic *Streptococci* group F on sheep blood agar after 24 hours. (b) Growth of *Aggregatibacter aphrophilus* on chocolate agar

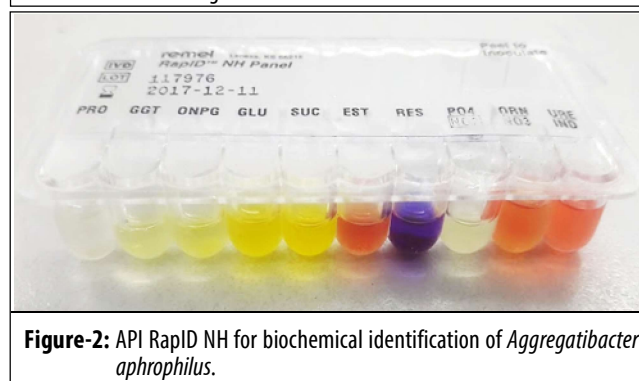


Figure-2: API RapID NH for biochemical identification of *Aggregatibacter aphrophilus*.

isolate was identified as *Aggregatibacter aphrophilus* by biochemical testing on API RapID NH (Remel) [Figure 2]. MIC of ampicillin and ceftriaxone were performed by E-tests and both were susceptible to it.

The patient was treated with ceftriaxone (50mg/kg/dose intravenous 12 hourly) for 6 weeks. The patient showed clinical improvement after 48 hours of therapy and was discharged after five days. On follow up after 4 weeks, the patient had fully recovered with no neurological deficits.

Discussion

In cyanotic congenital heart disease (CCHD) subclasses, Tetralogy of Fallot (TOF) with pulmonary atresia is one of the most common congenital defects.⁵ Non-pyogenic and pyogenic neurological complications are commonly seen in patients with uncorrected TOF patients. Generally, brain abscess is caused by contiguous or haematogenous spread of microorganisms. The most common sources identified are infective endocarditis, bacteraemia and secondary to dental infections. The main contributing factors for brain abscess in these children are chronic hypoxia leading to polycythemia and poor host immunity.⁶

Beta haemolytic *Streptococci* group F and *Aggregatibacter aphrophilus* are part of normal oral flora. *Aggregatibacter aphrophilus* is a gram negative bacilli that belongs to HACEK group. This microorganism is capnophilic and requires elevated level of CO₂. Apart from their pyogenic potential, these two are also causative organisms of infective endocarditis. Haematogenous spread of septic thrombi to distant sites through systemic and venous circulation has serious manifestations.⁷

In our patient these two microorganisms were isolated from pus aspirate; however *Aggregatibacter aphrophilus* didn't show growth in blood culture, possibly because of its slow growing fastidious nature and elevated CO₂ requirement. Only single blood culture was positive for Beta haemolytic *Streptococci* group F.

No vegetation was observed on transthoracic echocardiogram (TTE) in our patient; however positive blood culture for Beta haemolytic *streptococci* group F was indicative of possible IE. According to modified Duke's

criteria, the presence of three minor criteria - fever, cardiac abnormality and positive blood culture are suggestive of possible IE.

In infants and children weighing <60 kg, children without chest abnormality or clear lung field without any pathology, transthoracic echocardiogram (TTE) are sufficient for the diagnosis of any lesion-involving endocardium. However, transesophageal echo (TEE) can be done in certain clinical situations.

To our knowledge this is the first case of Polymicrobial brain abscess with oral flora in uncorrected FOT patient.

Clinical treatment of congenital heart disease must assess the central nervous system in case of positive blood culture especially with *Streptococcus* species, *Staphylococcus* species and organisms from HACEK group. More importantly, communications between the clinician and the laboratory about the details of sample collection, transportation and patient's history is essential for a better patient outcome.

Disclaimer: Poster presentation at 40th Annual Conference of Pakistan Association of Pathologist 2017 on 14-16th December 2017

Conflict of Interest: None to declare.

Funding Sources: None to declare.

References

1. van der Linde D, Konings EE, Slager MA, Witsenburg M, Helbing WA, Takkenberg JJ, et al. Birth prevalence of congenital heart disease worldwide: a systematic review and meta-analysis. *J Am Coll Cardiol* 2011; 58: 2241-7.
2. Baltimore RS, Gewitz M, Baddour LM, Beerman LB, Jackson MA, Lockhart PB, et al. Infective endocarditis in childhood: 2015 update: a scientific statement from the American Heart Association. *Circulation* 2015; 132: 1487-515.
3. Sheehan JP, Jane Jr JA, Ray DK, Goodkin HP. Brain abscess in children. *Neurosurg Focus* 2008; 24: E6.
4. Belkacem A, Caseris M, Yazdanpanah Y. A Case of *Aggregatibacter aphrophilus* Multiple Abscess. *Open Forum Infect Dis* 2015; 2(2): ofv031.
5. Humayun KN, Atiq M. Clinical profile and outcome of cyanotic congenital heart disease in neonates. *J Coll Physicians Surg Pak* 2008;18: 290-3.
6. Aftab S, Usman A, Sultan T. Frequency of cerebrovascular accidents and brain abscess in children with tetralogy of fallot. *Dr. Pak J Neurol Sci* 2015; 10: 23-6.
7. Nørskov-Lauritsen N. Classification, identification, and clinical significance of *Haemophilus* and *Aggregatibacter* species with host specificity for humans. *Clin Microbiol Rev* 2014; 27: 214-40.