

## Diffuse myocardial calcification in a drug addict, complicating advanced life support

Aylin Hatice Yamac

### Abstract

Myocardial calcification is a rare echocardiographic finding, which is often found in patients who have suffered from a myocardial infarction. Rarely, myocardial calcification may be present in individuals without a significant medical history. Until today, there has not been a published case report emphasising the relation between myocardial calcification and cocaine usage. Herein, we report a case of a young male with diffuse calcification of the left ventricular myocardium, who had an addiction to cocaine. This case highlights an uncommon etiology for myocardial calcification and it may lead to further studies about cardiotoxic effects of cocaine.

**Keywords:** Myocardial calcification; Cocaine abuse; Cardiac computed tomography.

### Introduction

There are different etiologies that may result in myocardial calcification. The most common types of the condition can briefly be classified as metastatic and dystrophic calcification. Dystrophic calcification mostly occurs in ventricular aneurysms after a myocardial infarction. It is associated with local tissue damage and cellular necrosis.<sup>1,2</sup> Metastatic calcification derives from increased levels of serum calcium salts, resulting from diseases such as hyperparathyroidism, chronic renal disease, hypervitaminosis D, osteomyelitis and metastatic tumours.<sup>1,2</sup> Rarely, myocardial calcification can be seen in cardiac tumours, such as rhabdomyomas and endotheliomas.<sup>3</sup>

Regardless of the underlying reason, the pathophysiology of the process is thought to be the same. "Idiopathic calcification" can be added as a third form of myocardial calcification, however the prevalence, etiology and mechanisms of this form is unknown due to very limited published data.<sup>1</sup> Only some publications presented myocardial calcification cases of unknown origins so far.<sup>4,5,6,7</sup>

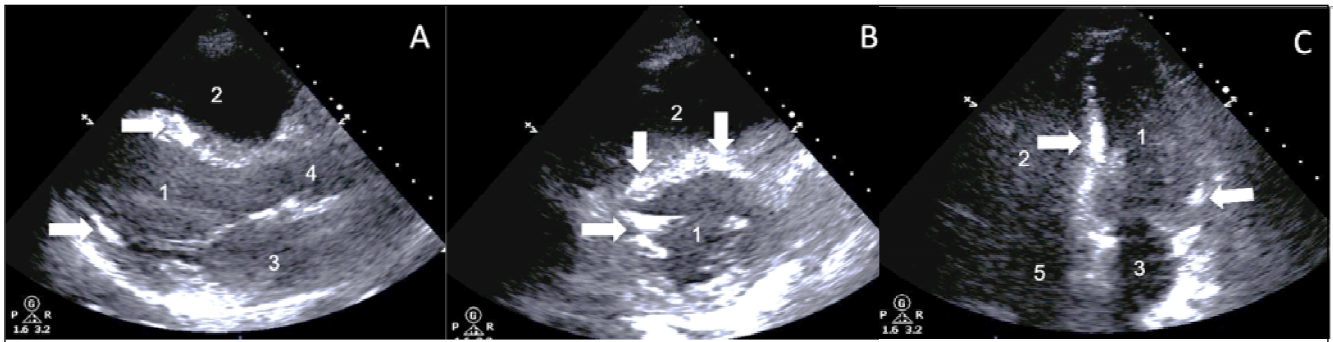
Cocaine is well known to be associated with coronary calcification, although there is no reference in current publications of its effects on myocardium. The only published data referring to the relation between cocaine and myocardial calcification are the case reports of Yup et al and Chan et al, where maternal cocaine consumption resulted in foetal myocardial calcification.<sup>8,9</sup> To the best of our knowledge, this case is the first one relating myocardial calcification with cocaine usage in an adult.

### Case Report

A 26-year-old male had been the target of a gunshot attack, which resulted in a perforated abdominal bullet injury. He had an addiction to cocaine but without any sign of intravenous drug abuse. According to his wife's statement, he has been using only "crack" cocaine for 6 years and not consuming any other type of drug. He was referred to our hospital (Bezmialem Vakif University Hospital) August 2017, undergoing emergent right hemicolectomy and segmentary intestinal resection. On the fourth day of follow-up, the patient's clinical condition deteriorated, characterised by hypotension (mean arterial pressure 55 mmHg, tachycardia (heart rate 140 beats per minute) and hypoxaemia (spO<sub>2</sub> 58 mmHg). The Swan Ganz Catheter measurements revealed a cardiac index of 1.8 l/min/m<sup>2</sup>, a systemic vascular resistance of 600 dynes sec/cm<sup>5</sup> and mixed venous saturation (SvO<sub>2</sub> of 48%), indicating a -combination of cardiogenic and septic shock. Wound and blood cultures revealed an infection with Extended-spectrum beta-lactamase (ESBL)-positive *Escherichia coli*. Thus the patient was treated with Imipenem and Vancomycin. Inflammatory markers like C-reactive protein (CRP) and procalcitonin were elevated, measuring 10 mg/dl (reference value < 0.5 mg/dl) and 22 ng/ml (reference value < 0.5 ng/ml) one day before exitus letalis. Calcium levels were measured as a minimum value of 6.3 and maximum value of 8.9 mg/dl (reference values 8.4- 10.2 mg/dl) during hospital stay. Several fever episodes with temperatures of up to 40°C were treated with antipyretic therapy. In line with the Swan Ganz catheter measurements, the left ventricular ejection fraction (LVEF)

Bezmialem Vakif University, TURKEY.

**Correspondence:** Aylin Hatice Yamac, e-mail: aylin-yamac@yandex.com

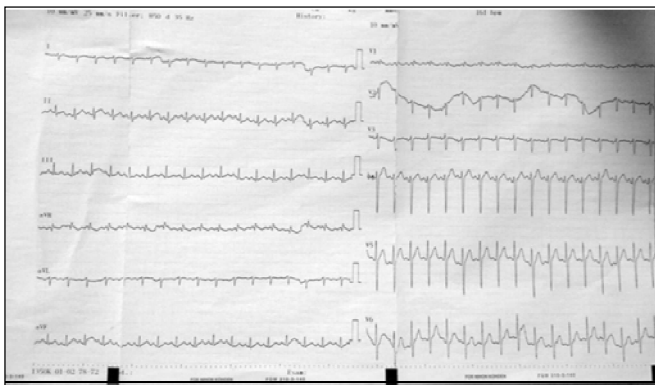


1. Left ventricle 2. Right ventricle 3. Left atrium 4. Aorta ascendens 5. Right atrium

**Figure-1:** Echocardiography, A: Parasternal long axis view, B: Parasternal short axis view, C: Apical 4-chamber view, Arrows are indicating calcification.

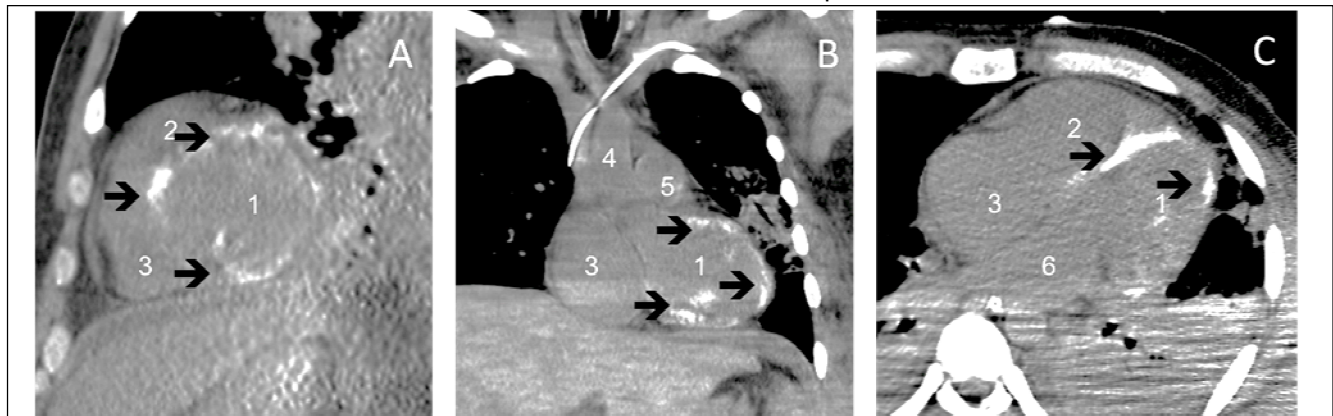
was severely reduced, measuring 32% according to the Biplane Simpson's Method. The size of the left ventricle was normal with an end-diastolic diameter of 48 mm, but the lateral, inferior, apical, septal left ventricular walls and papillary muscles demonstrated high echogenicity (Figure 2). The increased echogenicity showed a patchy formation with diffuse distribution, infiltrating the myocardium and papillary muscles (Figure 1).

To summarise, the echocardiographic findings revealed a combined picture of sepsis- or stress-induced cardiomyopathy and left ventricular systolic dysfunction due to severe myocardial calcification (Figure 1). Hereby, it has to be considered that the patient was treated with high dose inotropes like dopamin and noradrenalin. A clear differentiation was not possible. The electrocardiography (ECG) showed sinus tachycardia without ST segment changes, T wave or conduction abnormalities (Figure 2).



**Figure-2:** Electrocardiography

In contrast to the myocardium, the pericardium was thin without any sign of calcification or infiltration. Despite maximal haemodynamic support, including the insertion of an intra-aortic balloon pump, escalating inotropic and antibiotic therapy the patient could not be stabilised. Thus a thoracic computerized tomography (CT) scan was performed, revealing a diffuse calcification of the left ventricular myocardium, suggesting myocardial calcinosis [Figure 3]. The patient died due to multiple organ dysfunction 5 days after admission and an autopsy was not performed due to lack of consent.



1. Left ventricle 2. Right ventricle 3. Right atrium 4. Ascending aorta 5. Pulmonary artery 6. Left atrium

**Figure-3:** Cardiac Computed Tomography (CCT) Scan, A: CCT Sagittal plane, B: CCT Coronal plane, C: CCT Axial plane, Arrows are indicating calcification.

## Discussion

Myocardial calcification is a rare condition, which might complicate the treatment of patients in critical conditions. As it is not a common echocardiographic finding, it may not come to the minds of most physicians at first. Calcification as a result of an old ischaemic myocardial infarction is unlikely to be seen in a young patient without any cardiac history. Furthermore, after myocardial infarction, more often localised calcification is detected, rather than diffuse calcification, as demonstrated in this case. Computed tomography scanning is the gold standard for the diagnosis.<sup>1</sup> As the patient was involved in criminal activities, we assumed him to be having access to drugs. Thus, after the results of the imaging investigation, we took a detailed medical history, where his cocaine addiction emerged.

On the other hand in a clinical context of sepsis, there might be some factors like catecholamine-induced cardiomyopathy and ischaemia, yielding diffuse myocardial calcification. Indeed, there are several case reports, demonstrating myocardial calcification, which occurs in septic patients 24 to 42 days after admission, whereas the initial CT scan did not display any signs for calcium.<sup>10,11,12</sup>

More recently, another report demonstrated a case of sepsis-related myocardial calcification, where 5 days after hospital admission, the cardiac CT scan showed a morphologically normal-appearing left ventricular wall. Significant myocardial calcium accumulation was seen 13 days after hospital admission with a predominantly epicardial distribution and only after 44 days, an extensive myocardial calcification in the left ventricle became apparent.<sup>13</sup>

In all these cases sepsis related myocardial calcification occurred later and not within the first week of admission, as demonstrated in our case. Here, the mechanism of myocardial calcification seems not to be sepsis related, especially if we consider that the abdominal bullet trauma gave us a clear point of time when the infectious disease might have started. In contrast, an exact point of time for disease-begin was not clear in another report, where a young patient was admitted in the hospital due to septic shock. Although at day 6 after admission, the CT scan had shown diffuse calcification of the myocardium, it seems that the disease, namely pneumonia, started long before hospital admission.<sup>14</sup> Unfortunately, no exact timeframe for disease development and survey are given.

It is really unlikely, that extensive myocardial calcification visible on CT scan on day 4 is a result of sepsis per se. Cocaine abuse over long years seems more causally related to myocardial calcinosis.

Data about myocardial calcification without evidence of initiating factors is limited to a few case reports. Moreover cocaine consumption has not been evaluated as a possible etiologic factor so far. Although cocaine is significantly related to coronary artery calcification, possible relation between diffuse myocardial calcification in adults is not mentioned in any publication as yet. At present, no therapies, other than symptomatic treatment of the restrictive cardiomyopathy due to myocardial calcification, are available.

## Conclusion

Since cocaine addiction is uncommon and not considered as a favorable behaviour globally, the lack of publications may be due to interviewer bias (as the interviewer might not ask about cocaine consumption, the patient may hide the fact). It is clear that such coincidental pathologies may increase mortality risk by decreasing the effectiveness of support therapies in critically ill patients. This case is important to raise awareness about a previously unmentioned, possible underlying etiologic factor of myocardial calcification, which may guide future studies.

## Declarations:

Ethics approval: Available.

Patient's consent: Consent was taken from the patient's family for publication of the case report for scientific reasons.

Availability of data and materials: Materials described in the manuscript, including all relevant raw data, will be freely available to any scientist wishing to use them for non-commercial purposes.

**Disclaimer:** None to declare.

Competing interests: There are no competing interests.

**Funding Sources:** The work was not funded.

## References

1. Nance J, Crane G, Halushka M, Fishman E, Zimmerman S. Myocardial calcifications: Pathophysiology, etiologies, differential diagnoses, and imaging findings. *J Cardiovasc Comput Tomogr* 2015; 9: 58-67.
2. McClure J, Pieterse A, Pounder D, Smith P. Myocardial fibre calcification. *J Clin Pathol* 1981; 34: 1167-74.

3. Imaging of Cardiac Calcifications. [Online] [Cited 2015 Aug 5]. Available from: URL: <http://emedicine.medscape.com/article/352054-overview>.
  4. Duke, M. (1957). Massive calcification of the myocardium of unknown origin. *AMA Arch Pathol.*, 64(1), p.8.
  5. Edelstein J. Primary, massive calcification with ossification of the myocardium. *Am Heart J* 1946; 31: 496-500.
  6. Barnard D, Pape L, Missri J, Dalen J. Massive myocardial calcification and normal coronary arteries. *Tex Heart Inst J* 1985; 12: 363-5.
  7. El-Bialy, A., Shenoda, M., Saleh, J. and Tilkian, A. Myocardial calcification as a rare cause of congestive heart failure: a case report. *J Cardiovasc Pharmacol Ther* 2005; 10: 37-143.
  8. Yap T, Diana D, Herson V, Chameides L, Rowe J. Fetal Myocardial Calcification Associated With Maternal Cocaine Use. *Am J Perinatol* 1994; 11: 179-83.
  9. Chan Y, Sampson A. Massive myocardial calcification in second-trimester fetuses: antenatal detection and causes. *Ultrasound Obstet Gynecol* 2005; 25: 193-6.
  10. Schellhammer F, Ansén S, Arnold G, Brochhagen HG, Lackner K. Myocardial calcification following septic shock. *Cardiology* 2002; 98: 102-3.
  11. Simonson S, Miller WT Jr, Perl A, Torigian DA. Diffuse left ventricular myocardial calcification in the setting of sepsis of CT imaging. *J Thorac Imaging* 2007; 22: 343-5.
  12. Lapatto-Reiniluoto O, Vaalamo M, Takkunen O, Mänttari M. Left ventricular calcification following resuscitation. *J Intern Med* 2000; 248: 85-7.
  13. Torfs M, Salgado R, Van Herck P, Corthouts B, Robert D, Parizel PM. A Curious Case of Acute Myocardial Calcifications. *Circulation* 2016; 133: 426-7.
  14. Torracchi Carrasco AM. Myocardial calcification: A rare complication of pneumonia and sepsis. *Arch Bronconeumol* 2017; 53: 270.
-