

Advances in structural heart disease: MitraClip for Secondary Mitral Regurgitation — A potential game changer

Shahrukh Hashmani,¹ Ammarah Yasmeen,² Shayana Rukhsar Hashmani³

Secondary mitral regurgitation (MR) also known as the 'functional' MR, is not primarily due to underlying valve pathology. It is due to left ventricular dysfunction either secondary to idiopathic dilated cardiomyopathy or due to underlying coronary artery disease (CAD). Regional or global left ventricular (LV) systolic dysfunction and adverse LV remodelling can cause restricted leaflet motion and failure of leaflet coaptation resulting in MR.¹ Thus, the mechanism is largely ventricular rather than valvular. MR burdens the LV with a volume overload state that leads to a series of compensatory myocardial and circulatory adjustments. Eventually, the myocardium fails, the ventricle decompensates, and the patient exhibits signs of heart failure. It has been strongly associated with decreased quality of life, increased rate of hospitalization for heart failure, and shortened survival.^{2,3} Hence, the prognosis among patients with heart failure and secondary mitral regurgitation is extremely poor associated with high mortality rates.

In the remote past, the only option to treat secondary MR was to treat the underlying etiology. Guideline-directed medical therapy (GDMT) and cardiac resynchronization therapy (CRT) provided symptomatic relief, improved the left ventricular function, and in some patients, it lessened the severity of mitral regurgitation.⁴ As correction of valve in case of primary MR improve outcomes, the contrary was not true in case of secondary MR as the valve was structurally normal. Hence, neither percutaneous or surgical repair nor surgical replacement of the mitral valve had shown to lower the rate of hospitalization or death associated with secondary mitral regurgitation.⁴

Percutaneous repair by MitraClip is a transcatheter technology based on the surgical Alfieri edge-to-edge repair, which involves suturing together the middle segments of the anterior and posterior mitral valve leaflets, thereby creating a "double orifice" mitral regurgitant area.⁵ The MitraClip system utilizes a cobalt chromium clip covered with a polypropylene fabric that

grasps the leaflet and reduces mitral regurgitation (MR) by increasing the coaptation between the regurgitant valve leaflets. In some cases, a second clip may be required to adequately reduce the MR severity toward a goal of final regurgitant severity $\leq 2+$.⁶

In The Endovascular Valve Edge-to-Edge Repair Study (EVEREST) II trial, transcatheter mitral-leaflet approximation with the MitraClip device was found to be safer than surgical mitral-valve repair but was not as effective in reducing the severity of mitral regurgitation.⁷ In August, 2018; Mitra FR trial was published that showed that in patients with secondary MR, the rate of death or unplanned hospitalization for heart failure at 1 year did not differ significantly between patients who underwent percutaneous mitral-valve repair in addition to receiving medical therapy and those who received medical therapy alone.⁸ But the recently published landmark trial "COAPT - Cardiovascular Outcomes Assessment of the MitraClip Percutaneous Therapy for Heart Failure Patients with Functional Mitral Regurgitation trial contradicted the Mitra FR trial. These investigators showed that in patients with moderate to severe or severe secondary mitral regurgitation that remained symptomatic despite the use of maximal tolerated doses of GDMT, transcatheter mitral-valve repair resulted in a lower rate of hospitalization for heart failure and lower all-cause mortality within 24 months of follow-up than medical therapy alone.⁹

COAPT trial is a randomized controlled trial that had two groups; one group was assigned to GDMT while the other group had mitra clip in place in addition to the GDMT. With long follow up of 2 years, the rate of hospitalization for heart failure significantly reduced in the group receiving mitra clip. Similarly, all-cause mortality was also significantly decreased in the device group. (Figure A and B) The rate of freedom from device related complications at 12 months was significantly lower as compared to both the EVEREST-II trial and MITRA FR trial. One of the reasons why this trial was successful was that the procedural success rates for MitraClip implantation was 98%, with immediate achievement of a MR grade of 2+ or lower (moderate MR or less) in 95% of the patients. This was also durable over time with only 0.9% of patients reporting 3+MR (severe MR) at 2 years follow up compared to 14%

¹Cleveland Clinic Abu Dhabi. ²⁻³Aga Khan Hospital, Karachi, Pakistan.

Correspondence: Shahrukh Hashmani

Email: drshahrukhashmani@gmail.com

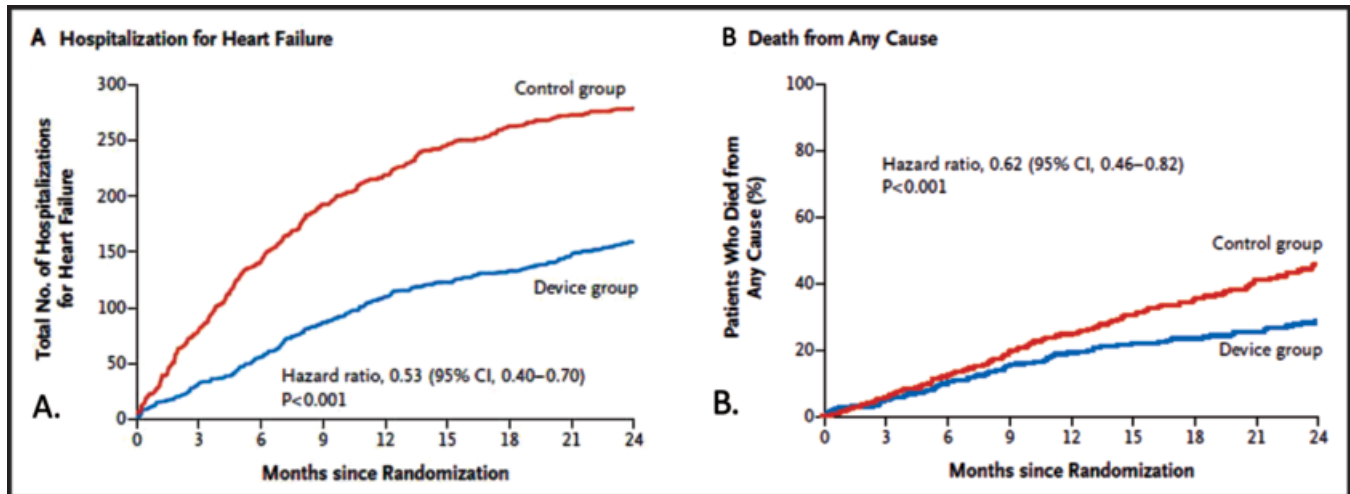


Figure: A shows rates of hospitalization for heart failure were significantly reduced at 24 months in the device group compared to the control group. Similarly Panel. B, shows decrease mortality in device group compared to the control group.

as reported in previous trials.¹⁰ The results from COAPT trial can have a significant impact on the management of patients with secondary MR.

In conclusion, COAPT trial showed that in patients with moderate-to-severe or severe secondary mitral regurgitation with heart failure who remained symptomatic despite the use of maximal doses of GDMT, transcatheter mitral valve repair (MitraClip) resulted in a lower rate of hospitalization for heart failure, lower mortality, and better quality of life and functional capacity within 24 months of follow-up than medical therapy alone.

Disclaimer: None to declared.

Conflict of Interest: None to declared.

Funding Sources: None to declared.

References

1. Levine RA, Schwammenthal E. Ischemic mitral regurgitation on the threshold of a solution: from paradoxes to unifying concepts. *Circulation*. 2005; 112: 745-58.
2. Sannino A, Smith RL II, Schiattarella GG, Trimarco B, Esposito G, Grayburn PA. Survival and cardiovascular outcomes of patients with secondary mitral regurgitation: a systematic review and metaanalysis. *JAMA Cardiol*. 2017; 2: 1130-9.
3. Goliash G, Bartko PE, Pavo N, et al. Refining the prognostic impact of functional mitral regurgitation in chronic heart failure. *Eur Heart J*. 2018; 39: 39-46.
4. Stone GW, Vahanian AS, Adams DH, et al. Clinical trial design principles and endpoint definitions for transcatheter mitral valve repair and replacement: Part 1: clinical trial design principles - a consensus document from the Mitral Valve Academic Research Consortium. *J Am Coll Cardiol*. 2015; 66: 278-307.
5. Maisano F, La Canna G, Colombo A, Alfieri O. The evolution from surgery to percutaneous mitral valve interventions: the role of the edge-to-edge technique. *J Am Coll Cardiol*. 2011; 58:2174.
6. Armstrong EJ, Rogers JH, Swan CH, et al. Echocardiographic predictors of single versus dual MitraClip device implantation and long-term reduction of mitral regurgitation after percutaneous repair. *Catheter Cardiovasc Interv*. 2013; 82:673.
7. Feldman T, Foster E, Glower DD, et al. Percutaneous repair or surgery for mitral regurgitation. *N Engl J Med*. 2011; 364: 1395-406
8. Obadia JF, Messika-Zeitoun D, Leurent G, Lung B, Bonnet G, Piriou N, Lefèvre T, Piot C, Rouleau F, Carrié D, Nejjari M. Percutaneous repair or medical treatment for secondary mitral regurgitation. *N Engl J Med*. 2018 Aug 27.
9. Stone GW, Lindenfeld J, Abraham WT, Kar S, Lim DS, Mishell JM, Whisenant B, Grayburn PA, Rinaldi M, Kapadia SR, Rajagopal V. Transcatheter Mitral-Valve Repair in Patients with Heart Failure. *N Engl J Med*. 2018 Sep 23.
10. Goldstein D, Moskowitz AJ, Gelijns AC, et al. Two-year outcomes of surgical treatment of severe ischemic mitral regurgitation. *N Engl J Med* 2016; 374: 344-53.