

Urothelial carcinoma in children, case report with review of literature

Zeeshan Arshad, Syed Zafar Zaidi

Abstract

Urothelial carcinoma is the third most prevalent malignancy in adults, accounting for 2.1 % of all cancer-related deaths. The highest incidence in the 6th decade of life but it is rare in the paediatric population and its incidence is less than 1% constituting a very rare disease. We report the case of a 13 years old boy, who presented to the outpatient department at The Indus Hospital, Karachi, in May 2017, with the complaint of painless gross haematuria.

Keyword: TCC children.

Introduction

Urothelial tumours are rare in children and should be excluded in young patients who present with painless haematuria. Tumours are predominately low-grade, more common in males at a 3:1 ratio, more common in White compared to Black patients and have low recurrence rate.

Case Report

A 13 years old boy presented in the outpatient department at The Indus Hospital, Karachi, in May 2017 with complaints of gross haematuria. Initial ultrasonography was performed which showed small polypoidal lesion in the posterior wall of urinary bladder (Figure-1). Computed Tomography was performed which showed iso-dense solid lesion in the posterior wall of

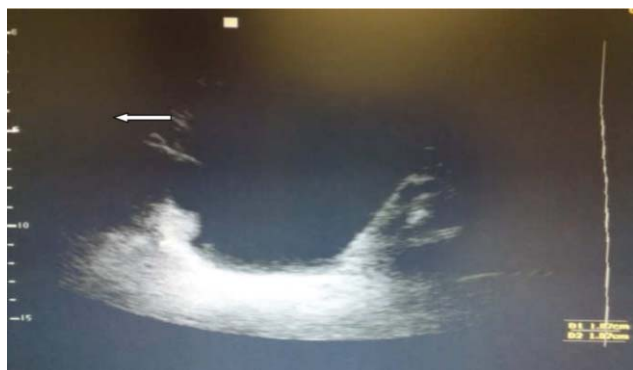

Figure-1: Iso-echoic polypoidal lesion in right posterior lateral wall of urinary bladder.

Urology Department, The Indus Hospital, Karachi, Pakistan.

Correspondence: Zeeshan Arshad. Email: zeeshandaa@hotmail.com

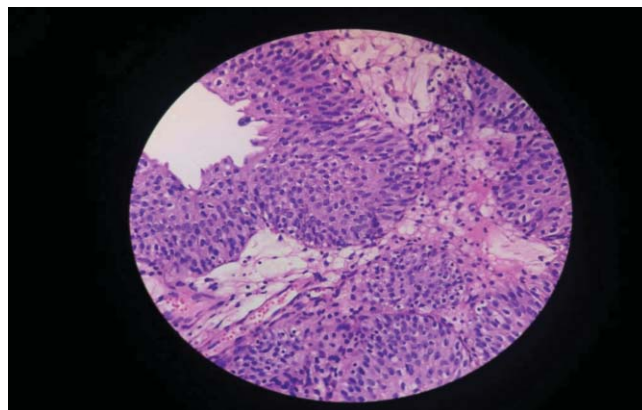


Figure-2: Discohesive cell with loss of polarity, hyperchromatic and pleomorphic nuclei.

urinary bladder. Cystoscopy was done which showed a small papillary lesion in the posterior wall of urinary bladder. Complete trans-urethral resection of lesion was done and Foleys Catheter was placed. Intravesical Mitomycin 40 mg was instilled within 24 hours. Foleys catheter was removed on the first post-operative day and patient was discharged. Histopathological examination revealed low grade papillary urothelial carcinoma without the involvement of lamina propria and muscles (Figure-2). Weekly adjuvant intravesical Mitomycin 40 mg for 6 weeks was given. Surveillance cystoscopy performed at 3 months and subsequently showed no recurrence of the lesion.

Discussion

Urothelial carcinoma is most common in 6th or 7th decade of life but it is very rare in the younger age and only few cases have been reported.¹ Its incidence of < 0.4% in the first two decades of life has been reported in a study by Javadpour and Mostofi.² A more recent review of previous reports identified 125 patients who were aged <20 years, of whom only 20 were aged <10 years³ It usually presents with gross haematuria.⁴ Urothelial carcinoma in children is often low-grade lesions, solitary, non muscle invasive, low malignant potential and rarely recurrent. It is three times more common in boys than girls. There are no specific risk factors in the small number of cases reported. In children it is associated with passive smoking, exposure to cyclophosphamide or muscle

relaxants, and with specific syndromes, such as Turner's syndrome.⁵ Literature regarding etiology, adequate management and prognosis of urothelial carcinoma is limited.⁶ Molecular analysis shows that Ki67 expression and low cyclin D1 immuno-histological expression is linked to higher risk of recurrence in children but p27Kip1 expression and p53 over-expression is not associated with higher rate of recurrence. On the other hand, reduced p27Kip1 expression is correlated with a greater risk of recurrence in elderly patients.⁷ There have been many reports which suggest clinical characteristics and treatment for urothelial carcinoma in children but still there is debate on progression and prognosis. There are no common guidelines for management or surveillance.⁵ Treatment depends on the transurethral resection of the lesion. In majority of patients transurethral resection of tumour is sufficient and all that is required.⁶ In case of invasive, high-grade urothelial carcinomas, outcome is worse.⁴ Urothelial carcinoma of high grade and even low grade can show progression resulting in mortality.⁸ Recurrence rate in children is about 7%.⁹ Adjuvant treatment after complete transurethral resections, for superficial non muscles invasive lesion is not necessary in children. It has been suggested that cystoscopy every 6 months for the first 2 years and urinary cytology/bladder ultrasound once a year for low lesion is¹⁰ adequate. Adjuvant intravesical instillation therapy, follow-up including computed tomography, and 3-month interval cystoscopy are justified in case of high-grade urothelial carcinoma.

Conclusion

Urothelial carcinoma in paediatric age group is a very rare entity. Younger patients with urothelial carcinoma usually have a good prognosis. Low grade, non muscle invasive urothelial carcinoma requires only trans-urethral

resection of the lesion. Urologists should keep in mind that children with urothelial carcinoma should be regularly screened for recurrence to timely identification of recurrence or progression.

Disclaimer: None.

Conflict of Interest: None.

Funding Sources: None.

References

1. Rifat UN, Hamadalla NY, Safi KCC, Al Habash SS, Mohammed M. Urothelial bladder tumour in childhood: A report of two cases and a review. *Arab J Urol.* 2015; 13:116-21.
2. Kang SK, Kim YS, Ko WJ, Park SU, Kie JH, Lee SY. High-Grade Urothelial Carcinoma of the Bladder in a Child. *KJ Urol Onco.* 2016; 14:181-4.
3. Lerena J, Krauel L, García-Aparicio L, Vallasciani S, Suñol M, Rodó J. Transitional cell carcinoma of the bladder in children and adolescents: six-case series and review of the literature. *J Ped Urol.* 2010; 6:481-5.
4. Grapin-Dagorno C, Peycelon M, Philippe CP, Berrebi D, El Ghoneimi A, Orbach D. Urothelial tumors in children. *Bulletin du cancer.* 2017; 104:195-201.
5. Chu S, Singer J. Transitional cell carcinoma in the pediatric patient: a review of the literature. *Urol.* 2016; 91:175-9.
6. Antonio M. Transitional cell carcinoma of the bladder in children. Long term follow-up. *Austin J Urol.* 2016; 3:1-3.
7. Paner GP, Zehnder P, Amin AM, Husain AN, Desai MM. Urothelial neoplasms of the urinary bladder occurring in young adult and pediatric patients: a comprehensive review of literature with implications for patient management. *Adv Anat Pathol.* 2011; 18:79-89.
8. Kral M, Michalek J, Skarda J, Tichy T, Smakal O, Kodet R, et al. High-grade urothelial bladder cancer in children: A case report and critical analysis of the literature. *Biomed Pap Med Fac Univ Palacky Olomouc Czech Repub.* 2016; 160:578-82.
9. Park S, Kim KS, Cho SJ, Lee D-G, Jeong BC, Park KH, et al. Urothelial tumors of the urinary bladder in two adolescent patients: emphasis on follow-up methods. *KJ Uro.* 2014; 55:430-3.
10. Bujons A, Caffaratti J, Garat JM, Villavicencio H. Long-term follow-up of transitional cell carcinoma of the bladder in childhood. *J Ped Uro.* 2014; 10:167-70.