

## Adjunctive surgical procedures enhancing treatment outcome — A literature review

Farheen Fatima, Adeel Tahir Kamal, Mubassar Fida, Maheen Ahmed, Hafiz Taha Mahmood

### Abstract

The face is the most expressive zone of the human body that communicates our feelings and thoughts. This may also influence the interaction between people. The aesthetic adjunctive procedures are life-changing. In contemporary orthodontic treatment, orthognathic surgeries are performed to correct the functional aspects of dentofacial deformities. In cases where the aesthetic outcome is not improved, patient dissatisfaction is often encountered. Many adjunctive surgical procedures can be used to enhance the anaesthetics of orthodontic or orthognathic surgical cases. Dwelling not merely on the ideal occlusion, the results could be enhanced by analysing the whole-face to improve the overall treatment outcome.

**Keywords:** Frontal augmentation, Rhinoplasty, rhytidectomy, Osteotomy.

### Introduction

The motivation for patients seeking orthodontic treatment comes from the desire to improve aesthetics and/or oral function.<sup>1-4</sup> Orthodontic consultation or referral could be due to functional concerns such as difficulty with mastication and speech, temporomandibular disorders (TMD), nasal blockage or obstructive sleep apnoea.<sup>3-5</sup> Patients could be either aesthetically or functionally driven for orthodontic treatment.<sup>6</sup>

Psychosocial studies claim that attractive people are more often successful in love and in life. Beautiful faces exhibit higher marital competence, are more likely to get hired for jobs compared to their less attractive peers.<sup>7-9</sup> With the increasing adult population of orthodontic patients and the demand for short duration, less invasive and the best aesthetic outcome after orthodontics, clinicians are faced with a challenge. Ideal skeletal and dental relationships once thought to result in the most proportionate profiles no longer dominate the treatment planning process. This paradigm shift has given rise to

.....  
Aga Khan University Hospital, Karachi.

**Correspondence:** Farheen Fatima. Email: farheen\_fatimas@hotmail.com

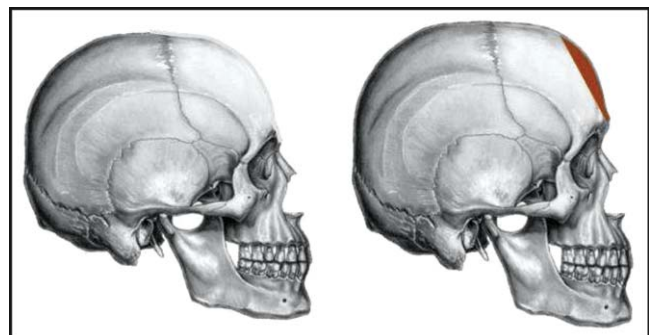
the need of adjunctive surgical procedures to enhance the outcome of orthodontic treatment. With the incorporation of these surgical procedures, the orthodontist and the plastic surgeon can work together to achieve exceptional results.

Over the years, various plastic surgery procedures have been developed and modified. Numerous surgeons have advocated different methods to meet the needs of not only those suffering from a dentofacial deformity, but also for those who seek an enhancement in their facial appearance. A continuous struggle to develop better surgical techniques, biocompatible materials and medicaments is fuelled by the phenomenal requirements of patients who desire beautiful faces.

This article was planned to discuss several adjunctive surgical procedures that can be performed to enhance the result of orthodontic treatment and the advances which have occurred overtime. Specifically, it encompasses frontal augmentation, rhinoplasty, midface implants, lip procedures, inferior body osteotomy, rhytidectomy and neck contouring procedures. Concepts which are implicit in this discussion lie beyond the scope of this review.

### Frontal Augmentation

Patients suffering from dentofacial deformity may present with deficient frontal bone development. Disfigurement of the facial architecture affects these individuals socially and psychologically. Syndromes, such as bilateral coronal craniosynostosis, require



**Figure-1:** Frontal augmentation.

frontal augmentation<sup>10</sup> (Figure-1). The frontal augmentation includes various surgical procedures including autologous fat grafting and alloplastic implants such as hydroxyapatite, expanded polytetrafluoroethylene (ePTFE), silicone, methyl methacrylate and the use of hyaluronic acid with and without radiofrequency have been reported.<sup>11-14</sup> It is important to note that the rate of resorption of autologous fat implant is unpredictable. Moreover, the formation of periorbital lipogranuloma after autologous fat injection has been reported.<sup>15-17</sup>

## Rhinoplasty

Rhinoplasty has become a popular procedure worldwide. It is done not only for the correction of pathological conditions such as a deviated nasal septum, but for the enhancement of nasal morphology (Figure-2). The technique of this procedure can be either an open or closed. The closed approach is most commonly employed. There are no external incisions on the nose and incisions are placed in the septal mucosa or the rim of the nares. The open procedure comprises of a transcolumellar incision that provides access to the internal structures of the nose. It is reserved for the management of conditions such as secondary revision of cleft lip and nose, crooked asymmetric nose, revision rhinoplasty and in patients with an abnormal morphology of the nasal tip.<sup>18</sup>

Maxillary surgery creates undesirable effects on the nose such as widening of the alar base, increase in prominence of the nasal tip and decrease in the prominence of the nasal dorsum.<sup>19</sup> A rhinoplasty can be done in combination with orthognathic surgical procedures to aid in correcting the undesirable effects

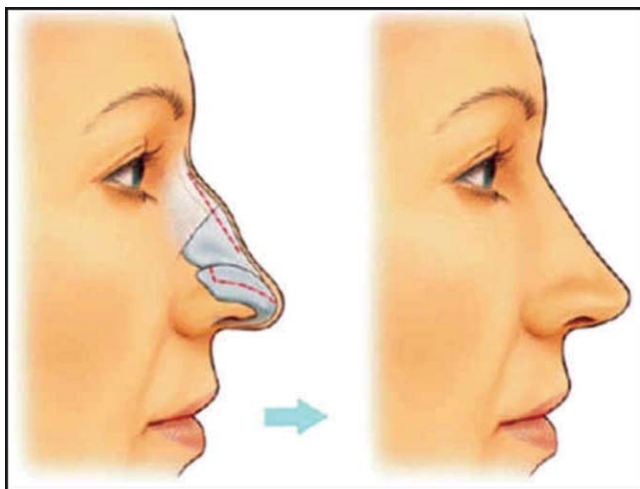


Figure-2: Rhinoplasty.

of maxillary surgery. It can be classified as a simultaneous or staged technique on the basis of the timing of the surgery. The oedema, increased surgical time, surgeon fatigue and post-surgical control of bleeding are factors which deter surgeons to undertake a simultaneous approach.<sup>20</sup> Techniques such as the Alar Cinch Suture are performed by anchoring the fibroareolar tissue through the vestibular incision at the alar-facial junction on both sides and the two free ends of the suture are tightened to reduce alar base width.<sup>21</sup> An alternative to the alar cinch suture technique is the Weir Procedure. It includes a wedge excision technique which spares entering into the nostril. It avoids the violation of the naturally curved ala and the nostril border that may result in over-straightening the ala.<sup>22-24</sup>

## Lip Procedures

Full lips with well-defined borders have often been associated with beauty and youth. The perception of the ideal size of the lips has varied over time and in different cultures. Lip procedures are frequently advocated along with orthodontic treatment to enhance treatment results. The patients who undergo LeFort I osteotomies have a tendency to develop untoward effects such as flattening of the upper lip and reduction in the vermilion border height.<sup>25</sup> Lip flattening may result from the release and the lateralisation of muscle attachments. In these patients, a lip lengthening procedure may help to overcome the side effects. The V-Y procedure can be used to lengthen the lip by converting the horizontal incision into V-Y pattern and suturing both vertical and horizontal arms of the incision. In cases where the patient has a short philtrum, this should be performed with rhinoplasty.

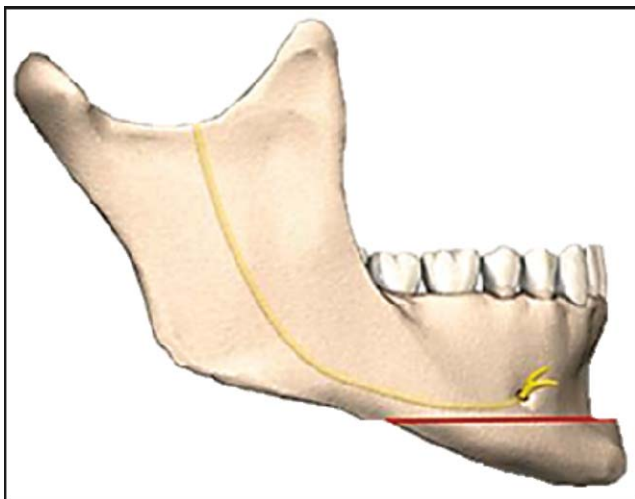
The lip lift procedure improves the appearance of thin lips by increasing the amount of vermilion display of the upper lip. This procedure improves the vermilion display but does not affect the total bulk of the lip.<sup>26</sup> This can be performed either by making an incision at the base of nose and excising enough tissue to lift the vermilion or by a direct incision on the lip.<sup>27</sup>

Lip augmentation could be performed either by the injection of collagen, dermogen, cymetra and fascion or an implant of allodermor synthetic material such as gortex. Reduction cheiloplasty is not a commonly performed procedure, as the current trend is towards thick prominent lips. In reduction cheiloplasty, an incision is made in the oral commissure and the desired amount of lip, including the submucosal gland is excised to obtain a reduced size.

Botulinum toxin is a polypeptide produced by the gram-positive anaerobic bacterium *Clostridium botulinum*. The muscle paralyzing feature of botulinum toxin has proven to be useful in more than 50 pathological conditions, including cosmetic applications.<sup>28</sup> This can be used for procedures such as the temporal brow lift, levatorlabii superioris, nasal flare, mental crease, facial asymmetry, upper lip wrinkling, hypermobile upper lip, Crow's feet, facial palsy and in aging of the neck. Complications that have been reported include nausea, fatigue, malaise, flulike symptoms, and rashes at sites distant from the injections. Percutaneous injections may cause pain, oedema, erythema, ecchymosis, headache and hypoesthesia.

### Inferior Body Osteotomy

The inferior border osteotomy is a versatile procedure to deal with the abnormal morphology of the chin and can be performed with orthognathic surgery (Figure-3). The bony chin can be moved in all directions, but the limitation with backward movement is the relaxation of the soft tissues over the chin which leads to an aesthetic wrinkling of the skin. Moving the chin forward or up can be achieved by angling the direction of the osteotomy cut upward; moving it down requires a bone graft but is quite feasible.<sup>29</sup> It is much less invasive than LeFort I or mandibular ramus surgery and can greatly improve the functional and aesthetic outcomes of orthodontic treatment for long-face Class II patients.<sup>30</sup> The advantages of this procedure is that it is predictable, stable and improves the chin-neck contour. The disadvantages include the fact that there is chance of damage to the mental nerve and notching that can occur at the inferior border of the mandible.<sup>17</sup>



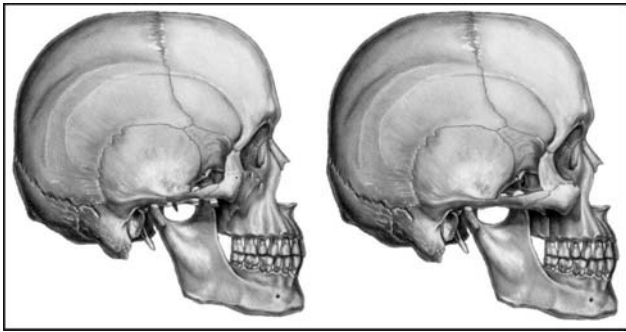
**Figure-3:** Inferior body osteotomy.

Alloplastic chin augmentation with silicone rubber or porous polyethylene is an excellent option for patients with deficiency of vertical and/or horizontal projection of the anterior mandible.<sup>31</sup> Implants are offered in a variety of shapes and sizes. This makes it convenient to reshape the chin in three dimensions. The inferior border of the mandible can also be augmented with the newer implants in the market. The materials commonly employed include gortex, silicone, meshed polymer, high-density polyethylene and synthetic hydroxyapatite. The advantages of these implants in comparison to the inferior body osteotomy include that it reduces the probability of injury to the mental nerve, it is reversible if the patient is not satisfied with the result, and lateral augmentation of the mandible is possible. The disadvantages to this technique include the chance of infection and resorption.<sup>17,32</sup>

### Rhytidectomy and Midfacial Implants

A number of techniques of facelift surgery have been described over the past century. The ideal facelift procedure would encompass technical ease, minimal operative time, short patient convalescence, minimal risk and complications, durable efficiency and maximal patient satisfaction. To date no single best surgical technique completely fulfils the criteria for an ideal procedure.<sup>33</sup>

Facelift surgery began to gain popularity after the First World War. Early on, techniques involved small skin incisions in natural skin creases. Modifications were described by studies,<sup>34-38</sup> with each contributing to the improvement in surgical techniques. Although facelift surgery generally involved more aggressive surgery involving deeper planes of dissection, there was a change in the late 1980s towards less invasive techniques. Less invasive procedures included short-scar facelifts, mini-lifts, the S-lift, the minimal access cranial suspension (MACS) lift and minimally invasive threadlifting.<sup>39</sup> Alloplastic implants are a surgical alternative to rhytidectomy approaches for restoration of midface volume. Implants augment the midfacial skeleton, restoring volume and a youthful, heart-shaped appearance to the face,<sup>39</sup> include silicone, ePTFE, or high-density polyethylene. Disadvantages include implant displacement, deformation, extrusion and infection.<sup>40</sup> Autologous fat grafting is another alternative for volumisation and many plastic surgeons are using this technique concurrently with rhytidectomy. Sinno et al.<sup>41</sup> found that 85% of clinicians have added autologous fat grafting as part of their surgical practice. The two most common



**Figure-4:** Midfacial implant.

regions augmented were the perioral and the deep malar compartments (Figure-4). Autologous fat grafting provides the large amount of volume needed for comprehensive midface rejuvenation. This is not possible with alloplastic fillers without considerable expense. Glasgold et al.<sup>42</sup> noted that only subjects receiving fat transfers to the cheek were satisfied with the results, and recommended fillers only for isolated lip and nasolabial fold augmentation. A recent review discussed the addition of platelet-rich plasma-enriched autologous fat graft in regenerative and aesthetic facial surgery. It was noted that there was an increase in the survival rate of fat grafts. It was also concluded that it may enhance the results of autologous facial fat graft in regenerative and aesthetic facial surgery.<sup>43</sup>

### Neck Contouring Procedures

A smooth neckline gives a grace to the personality and gives a sense of refinement that aids in enhancing an individual's overall appearance. Neck contouring surgery helps patients of any age to accomplish a naturally attractive neckline. If submental skin laxity is the only problem, the skin removed during the rhytidectomy may be sufficient for an improvement in the neck appearance. A variety of techniques are available to address the neck, including liposuction, midline platysmaplasty and chin augmentation.

During liposuction 1 or 2 tiny incisions are made that are concealed beneath the chin or behind the ears. A cosmetic surgeon inserts a small liposuction cannula, removing excess fat and sculpting a natural contour to the chin and neck. Suction-assisted lipectomy is commonly performed with emphasis on medial excision in the central subplatysmal fat region. Lateral excision is limited because there is less fat in this region and aggressive lateral liposuction.<sup>44</sup> The advantages include the reduction or elimination of a "turkey neck" by

removing excess, sagging skin, smoothing out wrinkles and creases throughout the neck and improvement in the appearance of vertical neck bands. The potential complications from liposuction are dimpling or puckering of skin, asymmetry, nerve damage or an undesirable result.

Platysmaplasty involves tightening and removing skin from the human neck. It has taken many forms, including lateral plication, sectioning and flap rotation, simple midline suturing, progressively tensioned midline sutures and many others.<sup>45</sup>

### Discussion

The ideal functional and aesthetic goals may require incorporation of adjunctive aesthetic procedures not only in adults but also in young patients who are planned for orthognathic surgery.<sup>46</sup> The diagnosis and treatment plan can be facilitated by computer imaging software. The evaluation of soft tissue profile requires nose, midface and chin evaluation, as these may contribute to convexity in facial profile.<sup>1</sup> This is important to inform the patient that orthodontic treatment may not affect the soft tissue profile drastically and patient may require adjunctive aesthetic surgery to improve facial appearance. Therefore, a successful treatment to improve soft tissue profile requires communication between parents and doctor. The goals of the treatment should be discussed before starting orthodontic treatment so that patients and parents are mentally prepared for the future adjunctive surgical procedure.<sup>4,5</sup>

Current trend in planning a procedure requires precise evaluation of facial tissue. This needs consideration of an individual's desires and priorities in terms of planning a new facial image. While planning a rhinoplasty procedure, the adjacent skeletal and soft tissue structures must be assessed besides the primary nasal deformity. In such cases, rhinoplasty can be done after skeletal and dental correction.<sup>19</sup> The variation in chin position could be attained either by moving bony chin or by using alloplastic implants. The dental camouflage at times results in inadequate outcome that can be improved by these simple adjunctive procedures.<sup>6</sup>

Frequently, the correction of facial disharmonies requires relatively simple operative procedures. The patient's acceptance for these procedures depends on person's perception of deformity, counselling for the procedure, duration of surgery and postoperative morbidity, and cost of the treatment.<sup>4</sup> Significant jaw disharmony may require interdisciplinary management

among the orthodontist, the maxillofacial and plastic surgeon, and possibly the prosthodontist. Additional skin treatments, facial rejuvenation and lip procedures can aid in attaining a happy and satisfying experience of the patient.<sup>41,42</sup> In the patients treated for dentofacial deformity the adjunctive surgeries maximise the outcome. Contemporary advances in medical and surgical techniques help in improved perioperative care of the patient. Advances in anaesthesia result in simultaneous aesthetic and orthognathic surgery that maximises the treatment outcome and patients' satisfaction.

## Conclusion

Adjunctive surgical procedures are performed to enhance the facial aesthetics of an individual. A combination of these procedures with orthodontic treatment may produce the desired improvement. Despite the facts that many of the procedures are performed successfully and achieve excellent results, the potential disadvantages and limitations of the current treatment modalities continue to drive clinicians to seek improvements in surgical techniques.

**Disclaimer:** None.

**Conflict of Interest:** None.

**Source of Funding:** None.

## References

1. Samsyanová L, Broukal Z. A systematic review of individual motivational factors in orthodontic treatment: facial attractiveness as the main motivational factor in orthodontic treatment. *Int J Dent*. 2014;2014.
2. Tanna N, Smith BD, Zapanta PE, Karanetz I, Andrews BT, Urata MM, et al. Surgical management of obstructive sleep apnea. *Plast Recon Surg*. 2016;137:1263-72.
3. Jung HD, Kim SY, Park HS, Jung YS. Orthognathic surgery and temporomandibular joint symptoms. *MaxfacPlast and Recon Surg*. 2015;37:14.
4. O'Ryan F, Lassetter J. Optimizing facial aesthetics in the orthognathic surgery patient. *J Oral Maxillofac Surg*. 2011;69:702-15.
5. Pacheco-Pereira C, Abreu LG, Dick BD, De Luca Canto G, Paiva SM, Flores-Mir C. Patient satisfaction after orthodontic treatment combined with orthognathic surgery: A systematic review. *Angle Orthod*. 2016;86:495-508.
6. Nocini PF, Chiarini L, Bertossi D. Cosmetic procedures in orthognathic surgery. *J Oral Maxillofac Surg* 2011;69:716-23.
7. Paustian-Underdahl SC, Walker LS. Revisiting the beauty is beastly effect: examining when and why sex and attractiveness impact hiring judgments. *Int J Human Res Manag*. 2016;27:1034-58.
8. Lee S, Ryu K. Plastic surgery: investment in human capital or consumption? *J Hum Capital*. 2012;6:224-50.
9. Laurentini A, Bottino A. Computer analysis of face beauty: A survey. *Comput Vis Image Underst*. 2014;125:184-99.
10. Simpson A, Wong AL, Bezuhley M. Surgical correction of nonsyndromic sagittal craniosynostosis: concepts and controversies. *Ann Plast Surg*. 2017;78:103-10.
11. Wong JK. Forehead augmentation with alloplastic implants. *Facial Plast Surg Clin North Am*. 2010;18:71-7.
12. Park DK, Song IK, Lee JH, You YJ. Forehead augmentation with a methyl methacrylate onlay implant using an injection-molding technique. *Arch Plast Surg*. 2013;40:597-602.
13. Höning JF, Merten HA. Subperiosteal versus epiperiosteal forehead augmentation with hydroxyapatite for aesthetic facial contouring: experimental animal investigation and clinical application. *Aesthet Plast Surg*. 1993;17:93-98.
14. Hyun MY, Kim SK, Kim BJ, Kim H, Park WS. Efficacy and safety of hyaluronic acid with and without radiofrequency for forehead augmentation: a pilot study using three-dimensional imaging analysis. *Ann Dermatol*. 2016;28:107-9.
15. Hu XZ, Hu JY, Wu PS, Yu SB, Kikkawa DO, Lu W. Posterior ciliary artery occlusion caused by hyaluronic acid injections into the forehead. *Medicine*. 2016;95:1-6.
16. Paik JS, Cho WK, Park GS, Yang SW. Eyelid-associated complications after autogenous fat injection for cosmetic forehead augmentation. *BMC Ophthalmol*. 2013;13:32-6.
17. Lee HS, Kim YC. Periorbital lipogranuloma after autologous fat injection for forehead augmentation. *Ann Dermatol*. 2016;28:245-7.
18. Proffit WR, White Jr RP, Sarver DM. Contemporary treatment of dentofacial deformity. St. Louis, Missouri: Mosby; 2003.
19. Mohamed WV, Perenack JD. Aesthetic adjuncts with orthognathic surgery. *Oral Maxillofac Surg Clin*. 2014;26:573-85.
20. Bertossi D, Albanese M, Turra M, Favero V, Nocini P, Lucchese A. Combined rhinoplasty and genioplasty: long-term follow-up. *JAMA Facial Plast Surg*. 2013;15:192-7.
21. Liu X, Zhu S, Hu J. Modified versus classic alar base sutures after LeFort I osteotomy: a systemic review. *Oral Surg Oral Med Oral Pathol Oral Radiol*. 2014;117:37-44.
22. Rohrich RJ, Ahmad J. A practical approach to rhinoplasty. Plastic and reconstructive surgery. 2016;137:725e-46e.
23. Persichetti P, Toto V, Signoretti M, Del Buono R, Brunetti B, Segreto F, et al. The correction of nasal septal deviations in rhinoplasty. *Ann Maxillofac Surg*. 2013;1:13.
24. Freer OT. The correction of deflections of the nasal septum with minimum of traumatism. *JAMA*. 1902;38:636-92.
25. Constantine FC, Ahmad J, Geissler P, Rohrich RJ. Simplifying the management of caudal septal deviation in rhinoplasty. *Plastic and Recon Surg*. 2014;134:379e-88e.
26. Louis PJ, Austin RB, Waite PD, Mathews CS. Soft tissue changes of the upper lip associated with maxillary advancement in obstructive sleep apnea patients. *J Oral Maxillofac Surg* 2001;59:151-6.
27. Moragas JS, Vercruysse HJ, Mommaerts MY. "Non-filling" procedures for lip augmentation: A systematic review of contemporary techniques and their outcomes. *J Craniomaxillofac Surg*. 2014;42:943-52.
28. Fanous N. Aging lips. Esthetic analysis and correction. *Facial Plat Surg*. 1987;4:179-83.
29. Abubaker AO, Sotereanos GC. Modified LeFort I (maxillary-zygomatic) osteotomy: rationale, basis, and surgical technique. *J Oral Maxillofac Surg*. 1991;49:1089-97.
30. Proffit WR, White Jr RP. Combined surgical-orthodontic treatment: how did it evolve and what are the best practices now? *Am J Orthod Dentofacial Orthop*. 2015;147:S205-15.
31. Sarver DM. Esthetic orthodontics and orthognathic surgery. St Louis, Mosby; 1998.
32. Polo M. Bone resorption under chin implants: The orthodontist's role in its diagnosis and management. *Am J Orthod Dentofacial Orthop*. 2017;151:201-8.
33. Barret DM, Gerecci D, Wang TD. Facelift Controversies. *Facial Plast Surg Clin N Am*. 2016;24:357-66.

34. Bettman A. Plastic and cosmetic surgery of the face. Northwest Med.1920;29:205.
  35. Skoog T. Plastic surgery: new methods and refinements. Philadelphia: W.B. Saunders; 1974.
  36. Adamson PA, Moran ML. Historical trends in surgery for the aging face. Facial PlastSurg1993;9:133-42.
  37. Mitz V, Peyronie M. The superficial musculoaponeurotic system (SMAS) in the parotid and cheek area. PlastReconstrSurg1976;58:80-8.
  38. Furnas D. The retaining ligaments of the cheek. PlastReconstr Surg.1989;83:11.
  39. Soares DJ, Silver WE. Midface skeletal enhancement. Facial PlastSurgClin North Am 2015;23:185-93.
  40. Hopping SB, Joshi AS, Tanna N, Janjanin S. Volumetric facelift: evaluation of rhytidectomy with alloplastic augmentation. Ann OtolRhinolLaryngol. 2010;119:174-80.
  41. Sinno S, Mehta K, Reavey PL, Simmons C, Stuzin JM. Current trends in facial rejuvenation: an assessment of ASPS members' use of fat grafting during face lifting. PlastReconstrSurg2015;136:20e-30e.
  42. Glasgold M, Glasgold R, Lam S. Autologous fat grafting for midface rejuvenation. ClinPlast Surg. 2015;42:115-21.
  43. Picard F, Hersant B, La Padula S, Meningaud JP. Platelet-rich plasma-enriched autologous fat graft in regenerative and aesthetic facialsurgery: Technical note.J Stomatol Oral Maxillofac Surg. 2017;118:228-31.
  44. Matarasso A. Managing the components of the aging neck: from liposuction to submentalplasty, to neck lift. ClinPlast Surg. 2014;41:85-98.
  45. Citarella ER, Condé-Green A, Hasbun SJ. Secondary neck lift and the importance of midline platysmaplasty: review of 101 Cases. Plast and Recon Surg. 2017;139:564e-6e.
  46. Waite PD, Matukas VJ, Sarver DM. Simultaneous rhinoplasty procedures in orthognathic surgery. Int J Oral Maxillofac Surg. 1988;17:298-302.
-