

## Synchronous chondrosarcoma originating from two distant ribs

Ali Cevat Kutluk,<sup>1</sup> Celalettin Ibrahim Kocaturk,<sup>2</sup> Yunus Seyrek,<sup>3</sup> Mehmet Orhan Cizmeci<sup>4</sup>

### Abstract

A chondrosarcoma is a rare bone tumour derived from cartilage-producing malignant mesenchymal cells. A 25-year-old male patient was operated upon to treat a chondrosarcoma arising in the left 2nd and 6th ribs. The tumour underwent en bloc wide resection in collaboration with a plastic surgeon for reconstruction of the resected area. Costal chondrosarcoma is very rare but chondrosarcoma arising from two ribs at the same time has not been reported before in the literature.

**Keywords:** Chondrosarcoma, Chest wall, Synchronous, Reconstruction, Wide resection.

### Introduction

Although chondrosarcoma is the most common malignant tumour of the chest wall, the tumour is nonetheless rare with the frequency of only 0.79 per million subjects/year.<sup>1</sup> The tumour often arises in the pelvis or the long bones. A rib chondrosarcoma is relatively rare. The tumour is resistant to conventional chemotherapy and radiation therapy; surgical resection is the only curative treatment.<sup>2</sup> Most reported series of chest-wall chondrosarcomas are small; case presentations are more common. We describe a chondrosarcoma that simultaneously affected the left 2nd and 6th ribs.

### Case Report

A 25-year-old male who had experienced left anterior chest wall deviation over the past four years was admitted to Yedikule Chest Disease and Thoracic Surgery outpatient clinic in Istanbul/Turkey in July 2014. He had no pain or palpable mass, and no history of trauma. Computed tomography (CT) of the thorax showed that the 6th rib was abnormally thick (3 cm) and deformed (Figure-1). Due to long and stable nature of the lesion and the report of low potential of malignancy of the radiologist we resected the 6th rib only with safe margins. Macroscopic histopathological examination revealed an 8 × 2 × 1.5-cm expansile mass, and microscopic examination revealed a lesion of dimensions 5.5 × 2 × 0.8

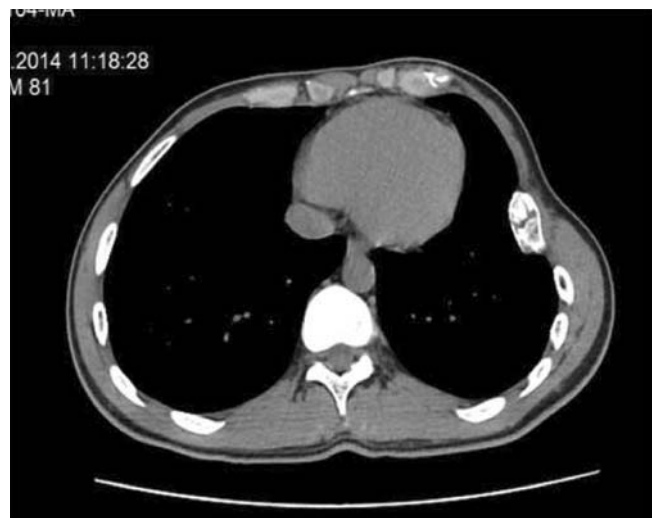


Figure-1: Preoperative Thorax CT.

cm with 0.8-cm tumour-free resection margins. Immunohistochemical staining diagnosed a grade 2 chondrosarcoma.<sup>3</sup>

Later positron emission tomography (PET) was performed to explore whether pulmonary and/or extrapulmonary metastases were present. PET revealed no abnormality but a maximum standard uptake value (SUVmax) of 1 at the left 2nd rib (Figure-2). Given the PET and pathological data, we decided to perform a second operation.

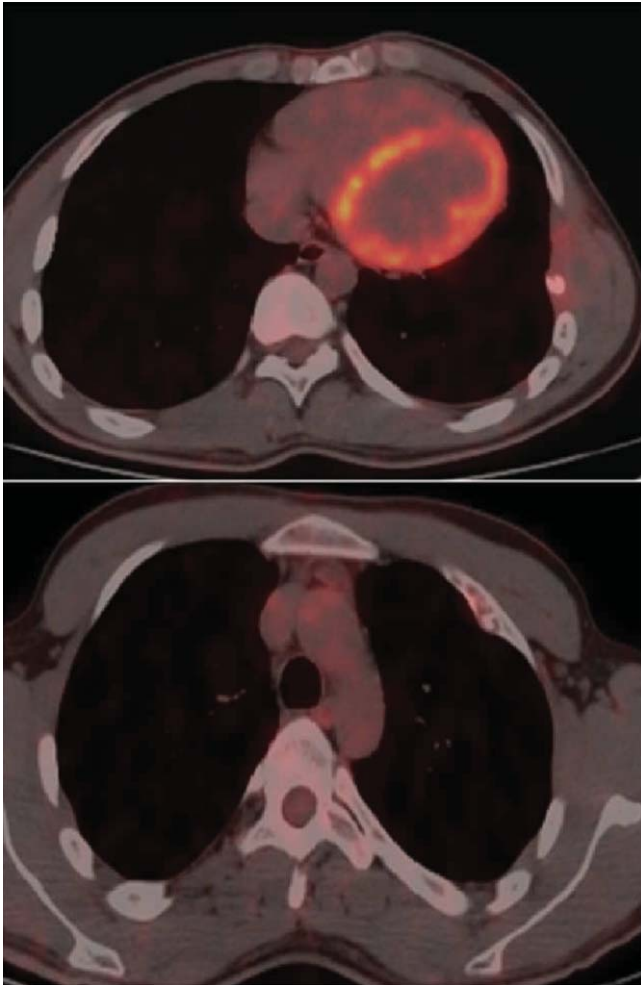
After a month of the first operation to provide adequate resection margins the 5th, 6th, and 7th ribs were subjected to en bloc wide resection with the surrounding skin and soft tissue. Two titanium bars together with a prolene mesh overlying were fixed in the posterior-to-anterior direction to provide stability, and to support the area of the defect, an ipsilateral, latissimus dorsi, rotational musculocutaneous flap was prepared by a plastic surgeon.

In order to avoid extra chest wall instability by resecting first and third ribs only the second rib was resected through a 4-cm-long incision.

Histopathological examination revealed no tumour in the larger specimen (the remainder of the 5th, and the 6th and 7th ribs). The 2nd rib exhibited atypical

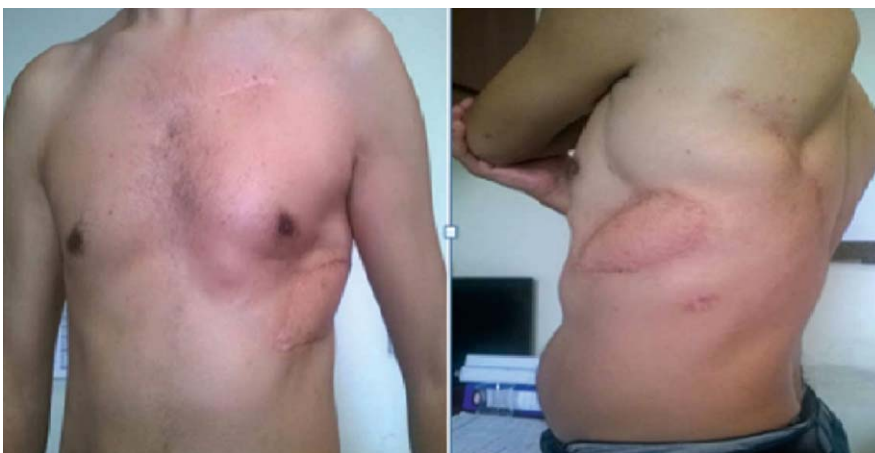<sup>1-3</sup>Yedikule Chest Disease and Thoracic Surgery Hospital, Istanbul, <sup>4</sup>Istanbul University, Istanbul, Turkey.

**Correspondence:** Ali Cevat Kutluk. Email: dralikutluk@gmail.com



**Figure-2:** PET-CT of the lesion at the second rib after the first operation.

chondromatous proliferation and was examined by a pathologist specializing in bone. The ultimate diagnosis was a grade 1 chondrosarcoma. Our tumour oncology



**Figure-3:** The patient 32 months after the second operation.

council evaluated the case and decided to schedule careful follow-up. The patient had neither chest wall instability nor infectious complications postoperatively and no local recurrence has been noted over 43 months of follow-up (Figure-3).

### Discussion

Chondrosarcoma is now defined by two separate codes in the International Classification of Diseases. These codes reflect different prognoses; grade 1 tumours are distinguished from those of grades 2 and 3.<sup>3</sup> Grade 1 chondrosarcomas were reclassified by the World Health Organization in 2013 as "atypical cartilaginous tumour" (ACT/CS1).<sup>4</sup> The tumours are moderately cellular, with an abundant matrix of hyaline cartilage. They rarely metastasize; the 10-year survival rate is 83-95%. As the grade rises, the cellularity increases, the extent of chondroid matrix falls, and the 10-year survival rate decreases.<sup>3,5</sup>

Most case series have a slight male predominance; the median patient age is about 50 years. Patients usually present with enlarging painful masses in the anterior chest wall.<sup>2,6,7</sup> Our case was 25 years of age and had no symptoms except for a chest wall deformity. He had a 3-cm-diameter mass in the 6th rib, with calcification. A percutaneous biopsy may not accurately reflect the true histological grade of the lesion because of tumour heterogeneity and possible sampling errors.<sup>7</sup>

As the tumours are relatively refractory to chemotherapy and radiotherapy, wide resection of all affected thoracic tissue, with appropriate margins, followed by reconstruction of the chest wall to ensure the preservation of respiratory mechanics, is essential.

The reconstructive prostheses should be covered with healthy vascularized tissue. The gross tumour-free margins should include at least some of the normal ribs lying superior and inferior to the tumour, and should extend for at least 4 cm both anteriorly and posteriorly.<sup>7</sup> Defects larger than 5 cm in diameter, and those overlying cardiac structures, must be reconstructed. Large defects at the posterior apex are covered by the scapula and do not require reconstruction. Both polypropylene (Prolene or Marlex) mesh and polytetrafluoroethylene (PTFE, Gore-Tex) have been successfully employed to this end; each material has its proponents.<sup>8</sup>

Even after wide local excision, local recurrence may develop in up to 50% of all patients. A high tumour grade, inadequate margins on initial resection, and resection in a general center has been reported to predict local recurrence.<sup>9</sup>

A chondrosarcoma arising simultaneously in two ribs is rare. Malignancy should be kept in mind when a lesion is evident in cartilage or bone. If the diagnosis is ambiguous, a pathologist specializing in the field should be consulted. Wide resection with adequate margins, followed by appropriate reconstruction, affords the only chance of long-term survival. The tumour is resistant to both chemotherapy and radiotherapy. Additional cartilaginous and/or osseous lesions should be sought in patients with chondrosarcomas.

**Disclaimer:** None to declare.

**Ethical Approval:** Ethical approval for publishing this case report is obtained from the Yedikule Chest Disease and Thoracic Surgery Clinic and the referred patient

**Conflict of Interest Statement:** No conflict of interest arose during the preparation and publication of this case report.

**Financing:** The authors declare that they have not received any financial support while researching and writing this case report.

## References

1. Somers J, Faber LP. Chondroma and chondrosarcoma. *Semin Thorac Cardiovasc Surg.* 1999; 11: 270-7.
2. Sangma MM, Dasiah S. Chondrosarcoma of a rib. *Int J Surg Case Rep.* 2015;10:126-8.
3. Gelderblom H, Hogendoorn PC, Dijkstra SD, van Rijswijk CS, Krol AD, Taminiu AH, et al. The clinical approach towards chondrosarcoma. *Oncologist.* 2008; 13, 320-9.
4. Hogendoorn PCW, Bovee JM, Nielsen GP. Chondrosarcoma (grades I-III), including primary and secondary variants and periosteal chondrosarcoma. In: Fletcher CDM, Bridge JA, Hogendoorn PCW, Mertens F, eds. *World Health Organization classification of tumors of soft tissue and bone*, 4th ed. Lyon: 2013; IARC, pp 264.
5. Angelini A, Guerra G, Mavrogenis AF, Pala E, Picci P, Ruggieri P. Clinical outcome of central conventional chondrosarcoma. *J Surg Oncol.* 2012; 106:929-37.
6. Tateishi U, Gladish GW, Kusumoto M, Hasegawa T, Yokoyama R, Tsuchiya R, et al. Chest wall tumor: radiologic findings and pathologic correlation: part 2. Malignant tumor, *Radiographics.* 2003; 23:1491-508.
7. Rascoe PA, Reznik SI, Smythe WR. Chondrosarcoma of the thorax. [Online] [Cited 2011 March 09]. Available from URL: <http://dx.doi.org/10.1155/2011/342879>
8. Altunkaya A, Aktunc E, Buyukates M, Kandemir O, Turan SA, Kutluk AC. Giant chest wall tumor invading the abdominal cavity: simultaneous reconstruction of the chest wall and hemidiaphragm. *Can J Surg.* 2008; 51: E30-1.
9. Widhe B, Bauer HCF. Surgical treatment is decisive for outcome in chondrosarcoma of the chest wall: A population-based Scandinavian Sarcoma Group study of 106 patients. *J Thorac Cardiovasc Surg.* 2009; 137: 610-4.