CASE REPORT

# Primary Synovial Sarcoma of the Mediastinum in an 18-year old male: A case report

Ansab Godil,[1] Muhammad Saad Ali Mallick,[2] Akash Khetpal,[3] Faizan Jabir Godil,[4] Arsalan Majeed Adam,[5] Muhammad Jawaid Mallick[6]

## Abstract

Primary mediastinal synovial sarcomas are very rare occurrences with only a few cases reported in literature to date. We present a similar case in an 18-year old male which proved challenging to diagnose and treat. Radiological imaging and tru-cut biopsy results gave rise to suspicion of an unusual malignancy. The sarcoma underwent en bloc resection and subsequent immunohistochemical staining confirmed the diagnosis of synovial sarcoma. The patient was put on adjuvant chemotherapy after surgery to prevent recurrence. The purpose of this case report is to assist oncologists in the diagnosis and clinical management of this rare tumour.

**Keywords:** Immunohistochemistry, Mediastinum, Synovial Sarcoma.

## Introduction

Synovial sarcoma is a rare and aggressive malignant soft tissue tumour arising most commonly in the extremities of young adults. Other uncommon locations for this tumour are the lung, pleura, chest wall and very rarely, the mediastinum.[1] Imaging studies coupled with histopathology and immunohistochemistry help in the diagnosis of such soft tissue malignancies. Herein, we report a case of synovial sarcoma occurring primarily in the mediastinum of an 18-year old boy. In this report we analyse this rare entity in its presentation, methods of diagnoses and the treatment employed.

## Case Report

An 18-year old male presented to Bait-ul-Sukoon Cancer Hospital, Karachi in January, 2016 with symptoms of intermittent mild to moderate chest pain, not related to physical activity or exertion. He also complained of dyspnoea which was especially severe at night. The patient had no history of smoking or cough and there was no family history of cancer. Physical examination appeared to be non-significant.

[1-5]Dow University of Health Sciences. [6]Oncology Department, Bait-ul-Sukoon Cancer Hospital, Karachi, Pakistan.
**Correspondence:** Arsalan Majeed Adam. Email: arsalan-56@hotmail.com

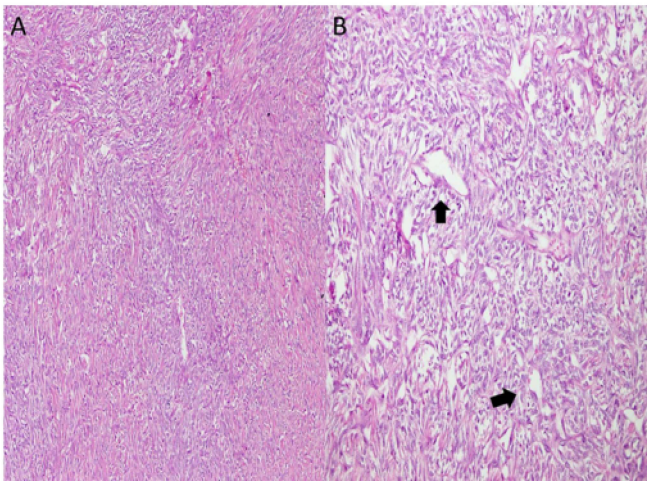


**Figure-1:** A) Spindle shaped neoplastic cells arranged in short fascicles against collagenous background (HnE, 100x magnification). B) Fascicles of spindle cells with intervening thin walled ectatic (hemangiopericytoma-like) vasculature (arrow heads). (HnE, 200x magnification).

A CT scan was performed which demonstrated a large anterior mediastinal mass in the right hemithorax with smooth margins and linear calcification. The mass abutted the ribcage; however no definite erosion was seen. The mass also extended towards the posterior mediastinum and paravertebral region with no accompanying erosion of the vertebral body. Its dimensions were 12x10cm and the mass was seen compressing the diaphragm and lung. Since Bait-ul-Sukoon is a charity hospital, PET scan was not an affordable modality.

A Tru-cut needle biopsy was performed to obtain a tissue diagnosis of malignancy before definitive treatment. The histopathological specimen showed very small linear tissue fragments composed of mesenchymal spindle cells and collagenized stroma, under the microscope. Differential diagnoses of neurofibroma, mesothelioma, fibrosarcoma and sarcomatoid carcinoma were suggested. A right thoracotomy and radical surgical excision of the tumour was performed. A 2mm surgical resection margins

were sufficient to achieve a 'tumour-negative' status. Staging was done using post-surgical resection of the tumour according to its size and lymph node involvement. The tumour resected was sent for biopsy. Sections of that specimen showed spindle cells arranged in fascicles, whorls and sheets within a collagenized background (Figure-1A). The neoplastic cells had indistinct cell boundaries and contained a small amount of pale eosinophilic cytoplasm. The nuclei within these cells were oval and elongated and contained finely dispersed chromatin with no significantly increased mitotic activity. Multiple variably diametered blood vessels (haemangiopericytoma-like vasculature) were present and the tumour cells surrounding these blood vessels had a basophilic tinge (Figure-1B). There were also areas of necrosis along with extensive calcification. The pathologist conferred a diagnosis of mediastinal tumour (spindle cell lesion) and the samples were further sent for immunohistochemistry.

Immunohistochemical stains performed on biopsy specimens denoted positive reactivity for Bcl-2, EMA, Cytokeratin 7, Cytokeratin 19 and CD99 (Figure-2). IHC stains gave equivocal results for Cytokeratin AEI/AE3 and negative results for CD34, CD31, Desmin and Calretinin. These findings proved to be essentially diagnostic of synovial sarcoma.

The patient was given seventeen doses of chemotherapy in the space of thirteen months following the surgery. The VDC/IE (Vincristine, Doxorubicin, Cyclophosphamide alternating with Ifosfamide and Etoposide) regimen was administered every two to three weeks. The patient had developed neutropenia and azoospermia as a consequence of the adjuvant combination chemotherapy. Semen analysis was also performed to evaluate chemotherapy's effects. Till date the patient is alive and free of recurrence 13 months postoperatively. Formal informed and written consent was taken from the patient prior to the reporting of the case.

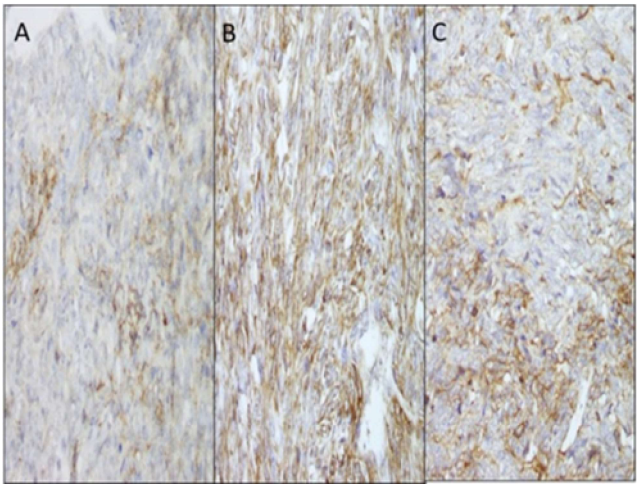


**Figure-2:** Tumour cells demonstrating positive expression for IHC stains: (A) EMA, (B) CD99 and (C) Bcl-2. (HnE, 200x magnification).

## Discussion

Synovial sarcoma is actually a misnomer because the tumour does not originate from the synovium; it only exhibits similarity to synovial tissue at light microscopy.[2] Synovial sarcoma was defined by the WHO in 2002 as a type of mesenchymal tissue cell tumour that exhibits epithelial differentiation and arises mainly in the extremities, with prevalence in the 15-40 age group.[3] Synovial sarcoma presenting in the mediastinum, as it did in our case, is exceedingly rare.

The symptoms of synovial sarcoma involving the mediastinum depend on the structures that are being compressed or invaded by the tumour. Patients may present with chest pain, cough, dyspnoea, reduced breath sounds and weight loss.[2]

At radiologic imaging, synovial sarcomas typically appear as heterogeneous masses that occasionally contain calcium.[4] Adequate pre-operative work up such as a CT scan and a Tru-cut needle biopsy was critical in this case to define the local extent of the tumour, guide the biopsy and obtain clues to a probable diagnosis for better preoperative planning and management.

Synovial sarcomas are highly aggressive tumours with generally poor prognosis. Size of the tumour is an important prognostic indicator. Patients with localized synovial sarcomas of dimensions less than 5cm had a 10-year survival of 88% compared with a 10-year survival of 38% and 8% for patients with sarcoma size of 5 to 10 cm and greater than 10 cm, respectively.[5]

Since a primary synovial sarcoma of the mediastinum is very rare, its optimal therapy is still unclear. Complete surgical resection is the mainstay of treatment for synovial sarcomas arising in the mediastinum and is the overwhelming factor in determining survival. In a systematic review of 22 studies conducted by Salah et al, which included 40 patients with primary synovial sarcoma in the mediastinum, complete resection was the most commonly applied therapeutic strategy. In these series,

23 of the 40 patients had complete resection of the tumour; in 8 of those patients resection was a part of the multimodal treatment which included chemotherapy and/or external beam radiotherapy (EBRT). The other 17 patients were treated by partial resections or with chemotherapy and/or radiotherapy as a consequence of the advanced stage of disease at presentation.[6] Since the tumour in our case was resectable with negative margins after surgery, EBRT was not performed. EBRT is a commonly employed primary therapy when the mass is unresectable.[7]

Pathological diagnosis remains the gold standard for synovial sarcomas which is divided into four types on the basis of histological features of epithelial and spindle cells in the mass. These include a monophasic spindle cell type, a monophasic epithelial type, a biphasic type and a poorly differentiated type.[3] The findings in our case were insufficient to delineate the sarcoma in either of these types.

A diagnosis of synovial sarcoma is difficult to procure purely on the basis of histopathology. Therefore confirmatory tests via immunohistochemical staining should be done, as was done in our case which revealed neoplastic cells diffusely immnoreactive to BCL-2 and focally immunoreactive to EMA, Cytokeratin 7, Cytokeratin 19 and CD-99.

The availability of molecular genetic identification of the t(X;18) via fluorescence in situ hybridization (FISH) has improved diagnostic specificity for synovial sarcomas as this chromosomal aberration is found in over 90% of cases.[7]This genetic analysis test, which was not performed in our case due to financial constraints, helps to substantiate diagnosis especially when synovial sarcoma is suspected in an uncommon location like in the mediastinum.

In summary, synovial sarcoma presenting in the mediastinum is a rare clinical scenario however extremely important to diagnose correctly in order to administer optimal treatment via integration of surgical resection, chemotherapy and radiotherapy.

**Disclaimer:** The abstract has not been presented or published in any journal or conference.

**Consent:** Informed consent was obtained from the patient to reproduce his case in this report.

**Conflict of interest:** None to declare.

**Funding Disclosure:** None to declare.

## References

1. Ravikumar G, Mullick S, Ananthamurthy A, Correa M. Primary Synovial Sarcoma of the Mediastinum : A Case Report. Case Repo Surg. 2011; 2011: 1-4.
2. Braham E, Aloui S, Aouadi S, Drira I, Kilani T, El Mezni F. Synovial sarcoma of the chest wall: a case report and literature review. Ann Transl Med. 2013; 1: 9.
3. Zhou Y, Dong W, Zou F, Al Zhou D, An Ma J. Primary giant mediastinal synovial sarcoma of the neck: A case report and review of the literature. Oncol Lett. 2013; 7:140-4.
4. Gladish G, Sabloff B, Munden R, Truong M, Erasmus J, Chasen M. Primary Thoracic Sarcomas1. Radio Graphics. 2002; 22: 621-37.
5. Deshmukh R, Mankin H, Singer S. Synovial sarcoma: the importance of size and location for survival. Clin Orthop Relat Res. 2004; 419: 155-61.
6. Salah S, Salem A. Primary Synovial Sarcomas of the Mediastinum: A Systematic Review and Pooled Analysis of the Published Literature. ISRN Oncol. 2014; 2014: 1-7.
7. Salah S, Al-Ibraheem A, Daboor A, Al-Hussaini M. Synovial sarcoma presenting with huge mediastinal mass: a case report and review of literature. BMC Res Notes. 2013; 6:240.