

Aortoenteric fistula... A fatal cause of gastrointestinal bleeding. Can it be missed? — A case report

Baseer Sultan Ahmad,¹ Mansoor Ul Haq,² Abeera Munir,³ Saiyed Abdullah Abubakar Mohsin Ehsanullah,⁴ Pervez Ashraf⁵

Abstract

Gastrointestinal (GI) bleeding, is the life threatening presentation of many diseases in emergency room. Aortoenteric fistula (AEF) is one of the rare causes of GI bleeding that can be fatal if not diagnosed and treated promptly. We present a case of a 86 years old hypertensive male with the history of fresh bleeding per rectum, dizziness, fatigability and palpitation for last 12 hours who came to the emergency room in January 2015. He was stabilized and resuscitated. On lab investigation and abdominal CT scan he was diagnosed as aortic aneurysm with AEF. The related pathology, diagnosis and management of the disorder has been discussed in this case report.

Keywords: Aortoenteric fistula, gastrointestinal bleeding, abdominal aortic aneurysm, computed tomography.

Introduction

Aortoenteric Fistula (AEF) is a rare cause of admission to the hospital.¹⁻³ It is not only a rare but catastrophic reason of gastrointestinal bleeding described by Sir Ashley Cooper in 1818.⁴ It is a pathological communication between the aorta and any part of the intestinal tract.^{4,5} This severe condition of AEF can be divided into two types — the Primary Aortoenteric Fistula (PAEF) and the Secondary Aortoenteric Fistula (SAEF).³⁻⁵

PAEF occurs usually in association with abdominal aortic aneurysm. PAEF occurs in 0.69% to 2.36% of patients with an aneurysm of the abdominal aorta, whereas SAEF occurs as a complication of aortic reconstructive surgery.^{3,4}

The most common symptoms of AEF are gastrointestinal blood loss which can be acute or chronic, abdominal pain, pulsating abdominal mass which are also known as classic triad for the diagnosis of AEF.³⁻⁵ AEF is not always easy to diagnose as these classical symptoms may not be present in all the cases.³

The only curative treatment for AEF is surgery without

^{1,2,5}Liaquat National Hospital, ^{3,4}Ziauddin University, Karachi.

Correspondence: Baseer Sultan Ahmad. Email: baseersultan@gmail.com

which the mortality approaches 100%.^{2,4}

Case Report

On 1st January 2015, an 86 year old male was referred to Liaquat National Hospital, Karachi, emergency room with history of fresh bleeding per rectum, dizziness, fatigability and palpitation for last 12 hours. On admission, his vitals were blood pressure 80/60mm/Hg, heart rate 103 beats per minute, respiratory rate 16 per minute. He was pale, lethargic and was sweating with no fever.

His past medical history included diabetes mellitus, hypertension and ischaemic heart disease. The patient had CABG (coronary artery bypass grafting) two years back.

Drug history included clopidogrel 75 mg, aspirin 75 mg, atorvastatin 10 mg daily and esomeprazole 40mg once daily.

Examination revealed a soft mass palpable in the

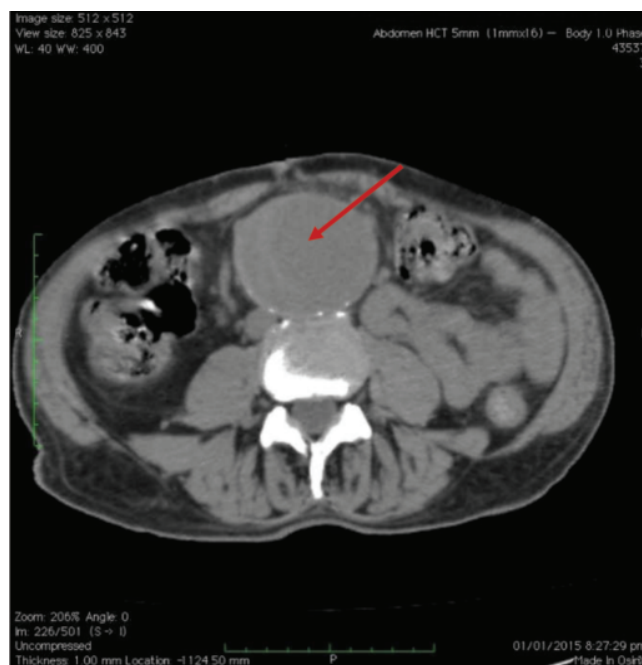


Figure-1: CT scan abdomen without Contrast. Arrow pointing toward aortic aneurysm with a big thrombus.

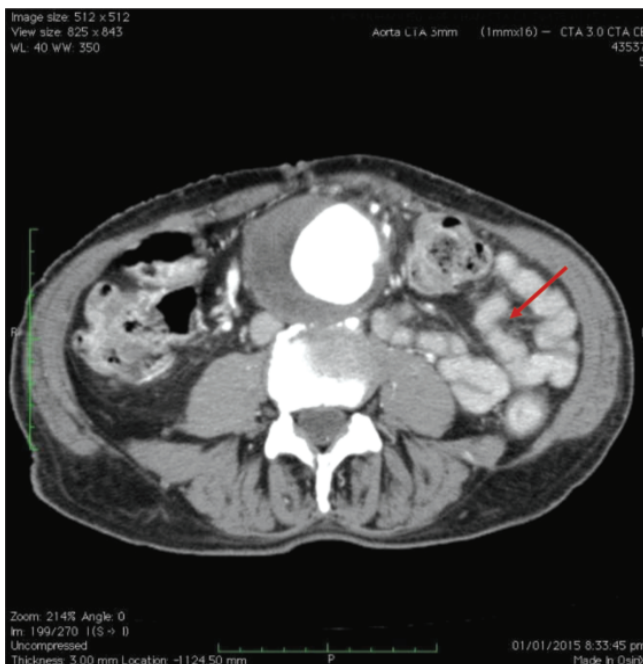


Figure-2: CT scan abdomen with contrast, arrow pointing toward filling of I/V contrast in the small bowel giving the impression of AEF.

epigastrium. Rest of the examination was unremarkable. Digital rectal examination revealed fresh blood. Initial laboratory investigation showed, haemoglobin level 5.6 g/dl, WBC count $6 \times 10^9/L$, platelet count 300,000/cmm, prothrombin time 10 seconds, INR (international normalized ratio) 1.1, creatinine 2.1 and urea 101. Electrolytes were normal.

The patient was resuscitated, 4 units of packed red blood cells were transfused and shifted to ICU. Keeping in view of the history of CABG, hypertension and a palpable mass in the epigastrium and fresh bleeding per rectum, high suspicion of AEF was considered and CT scan of abdomen with I/V contrast was done. This showed a large thrombus in the aorta without contrast (Figure-1). Leaking of contrast in small bowel confirming the diagnosis AEF, can be seen in Figure-2.

An urgent surgical intervention was planned by the vascular surgical team but family deferred surgery and planned to shift the patient to another hospital.

Discussion

Aortoenteric fistula, an abnormal communication between aorta and any part of intestinal tract mostly the duodenum,^{4,5} is one of the life threatening cause of gastrointestinal bleeding.^{1,2} It can be primary as well as secondary.³⁻⁵ Primary Aortoenteric fistula (PAEF) is

most commonly associated with aortic aneurysm.^{3,4} However exact pathogenesis is still a mystery.^{4,6} The other known and rare causes for PAEF are tuberculosis, syphilis, infection, cancer and foreign bodies and collagen vascular disease.^{1,5} Secondary Aortoenteric fistula may occur as a complication of aortic reconstructive surgery.^{3,4} In our case, the patient was diagnosed with PAEF.

The diagnoses of PAEF is quite a challenge as the signs and symptoms of the disease are very obscure and non-specific.³ The patients may present with the classical triad of abdominal pain, gastrointestinal bleeding, and pulsatile mass but this triad is only found in 11-38.5% patients.³⁻⁵ Abdominal pain is seen only in 35% patients, whereas gastrointestinal bleeding is present in 94% and pulsatile mass in 25% patients.⁵ This is a characteristic picture of herald bleeding which is a result of a small fistula tamponaded by thrombus formation.⁷ Other symptoms may include intermittent back pain, fever, sepsis, melena, weight loss, and syncope.^{4,7} The patient in the current case presented with lower GI bleeding and a painless pulsating mass in epigastric region. The most valuable tool for diagnosis of PAEF is a contrast-enhanced CT scan abdomen, which has a detection rate of 61%.^{2,3,5} It has a high sensitivity for PAEF. Radiological finding on CT scan include direct and indirect signs. Direct signs include ectopic gas adjacent to or within the aorta, the presence of vascular contrast within the GI tract. Indirect signs include bowel wall thickening overlying an aneurysm, disruption of the aortic fat cover and retroperitoneal haematoma or haematoma within bowel wall or lumen.

Other tests like conventional radiological methods and endoscopy may hold a poor diagnostic value in aorto-enteric fistula but they can help to exclude the other common causes of GI bleeding if there is time.^{1,2,6} In this case, we made the diagnosis on the bases of history, examination and CT abdomen with IV contrast.

The main objectives for the treatment of PAEF are confirmation of the diagnosis, control of bleeding, repair of bowel defect, eradication of associated infection, and revascularization.⁴ The treatment comprises of surgical intervention and antibiotics.^{4,5} Without surgery, the mortality rate is almost 100%.^{3,4,7} Surgery is the standard treatment for PAEF however Endovascular repair may be an alternative for patients who are poor candidates for surgery or they are haemodynamically unstable.⁴⁻⁶ The survival rate depends on the interval between the onset of bleeding

and surgical intervention.⁴ In this case, our patient was resuscitated, stabilized and emergency surgery was planned but the family refused surgery and left the hospital against medical advice. Ethical approval letter was obtained from department of gastroenterology. Permission was obtained from the patient's family for the publication of the case.

Conclusion

AEF is one of the rare differential diagnosis of lower gastrointestinal haemorrhage with a high mortality of almost 100%. It is a common clinical reminder for practicing gastroenterologists, physicians and gastroenterology fellows that if it is missed, it can be catastrophic. History and examination of the patient is crucial for the diagnosis and treatment of the disease.

Disclaimer: None to declare.

Conflict of Interest: None to declare.

Funding Sources: None to declare.

Reference

1. Mavioglu I, Sucu N, Aytacoglu B, Gul A, Dikmengil M. Primary aorto-colic fistula arising from a post-traumatic aortic pseudoaneurysm. *Euro J Vas endovasc surg.* 2005; 29:97-100.
2. Costea R, Zărnescu E, Zărnescu N, Neagu S. Primary Aortoenteric Fistula: Case Report. *Chirurgia.* 2015; 110:78-80.
3. Mehmood RK, Mushtaq A, Andrew DR, Miller GA. Clinical presentation of a missed primary aorto-enteric fistula. *J Pak Med Assoc.* 2007; 57:616.
4. Xiromeritis K, Dalainas I, Stamatakos M, Filis K. Aortoenteric fistulae: present-day management. *Inter surg.* 2011; 96:266-73.
5. Lee W, Jung CM, Cho E-H, Ryu DR, Choi D, Kim J. Primary Aortoenteric Fistula to the Sigmoid Colon in Association with Intra-abdominal Abscess. *Korean J Gastroenterol.* 2014; 63:239-43.
6. MacDougall L, Painter J, Featherstone T, Overbeck C, Paremal S, Chatterjee S. Aorto-enteric fistulas: a cause of gastrointestinal bleeding not to be missed. *BJMP.* 2010; 3:317.
7. Guner A, Mentese U, Kece C, Kucuktulu U. A rare and forgotten diagnosis of gastrointestinal bleeding: primary aortoduodenal fistula. *BMJ Case Rep.* 2013; pii: bcr2013008712.