

## Calcifying fibrous pseudotumour of maxilla: A rare entity mimicking malignancy: A case report

Talha Ahmed Qureshi,<sup>1</sup> Shabbir Akhtar,<sup>2</sup> Mariam Abid<sup>3</sup>

### Abstract

Occurrence of inflammatory pseudotumour in head and neck region or nose and paranasal sinuses is rare. However, when they do occur, they could be quite aggressive. Etiologically, they are believed to be reactive than neoplastic, and calcification may suggest end-stage. Their clinical presentation and radiologic features may resemble a malignancy. Grossly, they are not encapsulated, but multilobulated and can be circumscribed or infiltrative. Histologically, they constitute of bland spindle cells with scant cytoplasm and occasional mitotic figures. Scattered lymphocytic and plasma cell infiltrates with abundant dense hyalinized collagenous stroma and focal small calcifications are seen. Presence of atypia, DNA aneuploidy, and abnormal p53 expression may suggest malignant potential. Though not known to metastasize, they can lead to local complications, causing destruction of bone and surrounding tissues. Management is mainly by surgical excision though adjunct corticosteroids have been advocated. We report such a rare case of calcifying fibrous pseudotumour of maxilla.

**Keywords:** Inflammatory Pseudotumor, Plasma Cell Granuloma, Maxilla, Case Reports, Case Study

### Introduction

Inflammatory pseudotumour has been described in other parts of the body like GIT, lungs, retroperitoneum, etc., but its occurrence in head and neck is uncommon and its presence in nose and paranasal sinuses is even rare.<sup>1</sup> The etiology is unknown. However the possible cause is inflammatory reaction of tissue injury.<sup>2</sup> Though the pseudotumour is accepted as a benign entity with fibroblastic proliferation which may mimic malignancy due to its occasional aggressive nature, a portion of these

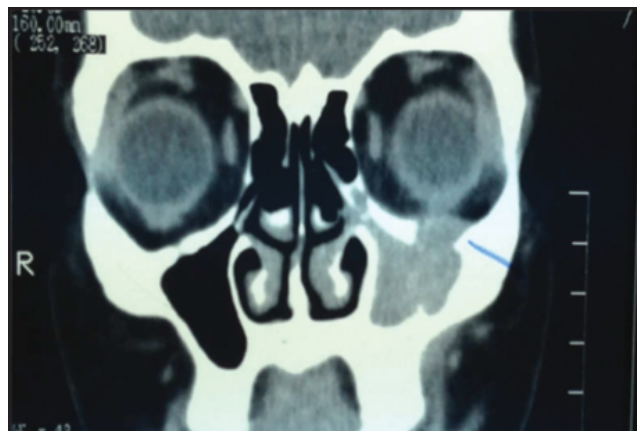
.....  
<sup>1</sup>Department of Otorhinolaryngology, Patel Hospital, Karachi, <sup>2</sup>Section of Otorhinolaryngology, Department of Surgery, Aga Khan University Hospital, Karachi, <sup>3</sup>Department of Pathology, Shifa College of Medicine, Shifa Tameer-e-Milat University, Islamabad, Pakistan.

**Correspondence:** Talha Ahmed Qureshi. Email: tal\_qureshi@yahoo.com

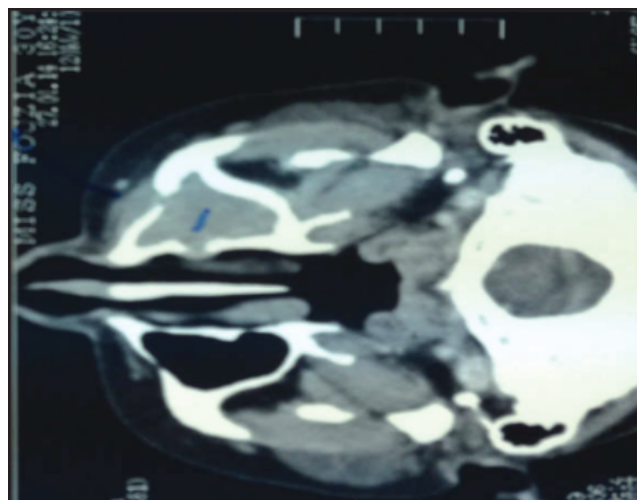
pseudotumours may represent actual neoplasia.<sup>1</sup> We report a rare case of calcifying inflammatory pseudotumour of maxilla mimicking a malignancy.

### Case Report

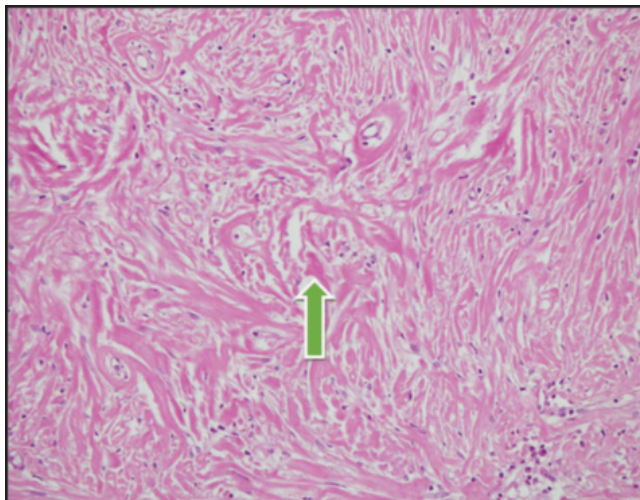
A 30 year old lady presented to the ENT clinic at Aga Khan University Hospital in February 2016 with complaint of swelling on the left cheek. She had no other known co-morbidity. Her cheek swelling had



**Figure-1:** CT scan (coronal view of paranasal sinuses) showing soft tissue mass in left maxilla eroding floor of orbit.



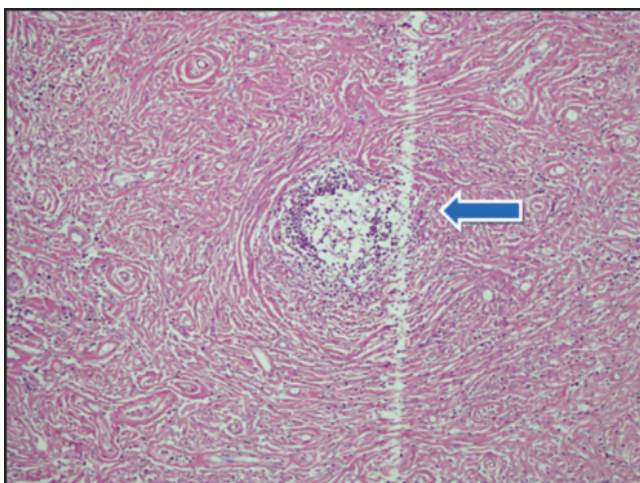
**Figure-2:** CT scan (axial view) showing soft tissue mass in left maxilla eroding anterolateral wall and extending to cheek.



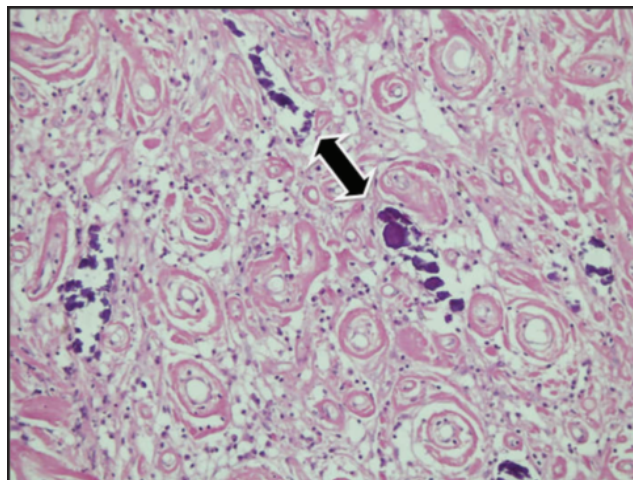
**Figure-3:** Microscopy showing haphazard to whorled hyalinized collagenous stroma seen (Green Arrow) (20X).

begun approximately two years ago and had been progressively increasing in size ever since. The swelling was now associated with redness and tenderness of the overlying skin. There were no associated complaints of fever, nausea, weight loss or any other symptom pertinent to ENT region. Patient had undergone several biopsies earlier in other hospitals by Caldwell-Luc approach but results had been inconclusive. However, her last biopsy revealed spindle cells along with chronic inflammatory cell infiltrate mainly plasma cells and lymphocytes raising possibility of pseudotumour. The patient was a non smoker, and her family history was also unremarkable.

Upon physical examination, a diffuse swelling incorporating the left maxillary region could be seen. The



**Figure-4:** Microscopy showing lymphoid follicle with admixed inflammatory cells (Blue Arrow) (20X).



**Figure-5:** Psammomatous to irregular, dystrophic calcification (Black Arrow) seen in microscopy.

size of swelling was estimated to be 3cm X 4cm and there was no skin ulceration. It was a firm, mildly tender mass on palpation, involving the floor of the orbit of the eye as well. No discharge was noted and colour of the overlying skin was slightly red.

CT-scan showed 'soft tissue density' in left maxillary sinus with erosion of anterior and superior walls. (Figure-1, 2). Consent by patient to present her case as a publication and presentation was taken.

Surgery was planned for confirming the diagnosis and further management. Subtotal maxillectomy via a lateral rhinotomy was performed and medial and lateral walls of maxilla were removed. Intraoperatively, no discrete lesion was identified except inflamed soft tissue eroding anterior wall of the maxilla and the floor of orbit. The lesion was removed in a piecemeal manner. Maxillary cavity was packed and incision site closed. Postoperatively, the patient remained fine and was discharged on antibiotics, anti-inflammatory drugs and corticosteroids (prednisolone 0.5 mg/kg/day),

The patient was both subjectively and objectively better, when seen on her first follow-up after a week. She was continued on oral steroids for another two weeks (prednisolone 0.5 mg/kg/day), and then the steroids were tapered off.

Histopathology with hamatoxylin and eosin staining showed an un-encapsulated pauci-cellular bland spindle cell lesion with abundant, haphazard to whorled hyalinized collagenous stroma (Figure-3). Admixed mixed inflammatory infiltrate comprised of

plasma cells, lymphocytes, eosinophils, mast cells and lymphoid follicles (Figure-4). Varying degree of psammomatous to irregular, dystrophic calcifications were present (Figure-5).

## Discussion

Calcifying fibrous pseudotumours (CFPTs) are paucicellular collagenous lesions with scattered chronic inflammation and focal calcifications.<sup>3</sup> Many previous case studies and literature reviews have suggested that CFPT is a cell-poor, end stage of inflammatory pseudotumor (IPT).<sup>4</sup> Although lung involvement is reported to be the most common presentation of IPTs, variants are known to involve almost any type of anatomical location. Etiologically, they are believed to occur due to reactive rather than neoplastic changes. Its pathogenesis is largely unknown, but IPTs are believed to occur as a result of immunologic host reaction to inciting agents like infections, neoplasms, foreign bodies etc.<sup>5</sup>

The differential diagnoses<sup>6</sup> that should be considered with CFPTs are desmoid tumours, solitary fibrous tumour, desmoplastic fibroblastoma, calcifying aponeurotic fibroma, collagenous fibroma and other sub categories of inflammatory pseudotumours (focal myositis, plasma cell granuloma, inflammatory myofibroblastic tumour etc).<sup>6</sup>

The diagnosis of CFPT requires clinical exclusion of neoplasms and absence of active infectious processes. Literature review suggests a trend favouring younger female population as the primary focus of incidence,<sup>7</sup> although no specific age limit has yet been identified. Definitive diagnosis requires a full histological assessment of the surgically excised mass.

Histologically, the common patterns identified demonstrate that most CFPTs have bland spindle cells, scattered lymphocytic and plasma cell infiltrates, abundant dense hyalinized collagenous stroma with focal small calcifications. The bland spindle cells usually show scant cytoplasm and occasionally mitotic figures. In the infiltrates and scattered lymphocytes, germinal centers can often be identified. Although plasma cells usually predominate, the surrounding cellular debris is known to contain variable representation of neutrophils, eosinophils and mast cells as well.<sup>8-11</sup> Presence of cellular atypia, DNA aneuploidy and abnormal p53 gene expression may suggest malignancy potential. CFPTs are not known to be encapsulated but may be multilobulated, and depending on the exact nature of the mass and its location, can be either circumscribed or infiltrative. Well-circumscribed masses tend to present

frequently with pressure symptoms and likely to be noticed by the patient primarily due to aesthetic issues from its location. Infiltrative CFPTs can be very aggressive and may involve underlying structures like nerves and blood vessels.<sup>8-11</sup> The pseudotumour mass in this reported case was causing significant local bone erosion as well as erythema and tenderness of the overlying skin, though nerves and blood vessels were not affected.

The mainstay management of CEPT remains surgical intervention and excision of the mass.<sup>12</sup> Chemotherapy and radiotherapy might be useful adjuncts, but till date, no significant evaluation of these modalities have been undertaken.<sup>13,14</sup> Given the low probability of local recurrence following adequate surgical excision, CFPTs can be sufficiently managed by surgery alone, although some studies do advocate advantages of adding steroids.<sup>9,15</sup>

Although not known to metastasize, CFPTs can result in a number of local complications due to its aggressive, locally infiltrating nature. Some common complications reported in literature include local bone erosion, infiltration into the surrounding soft tissue and vasculature, overlying skin involvement and cavity obstruction.<sup>16,17</sup>

## Conclusion

Inflammatory pseudotumour is rare in maxilla region, but when present, is aggressive, causing destruction of bone and surrounding tissues. The clinical presentation and radiological features may mimic malignancy, but needs to be histologically differentiated. Management is mainly by surgical excision. Our case report accounted for one of such rare cases of calcifying fibrous pseudotumour of maxilla mimicking malignancy.

**Disclaimer:** None to declare.

**Conflict of Interest:** None to declare.

**Funding Disclosure:** None to declare.

## References

1. Gale N, Zidar N, Podboj J, Volavsek M, Luzar B. Inflammatory myofibroblastic tumor of paranasal sinuses with fatal outcome: Reactive lesion or tumor? *J Clin Pathol* 2003; 56: 715-7.
2. Earl PD, Lowry JC, Sloan P. Intraoral inflammatory pseudotumor. *Oral Surg Oral Med Oral Pathol* 1993; 76: 279-83.
3. Bell DM, Dekmezian RH, Husain SA, Luna MA. Oral Calcifying Fibrous Pseudotumor: Case Analysis and Review. *Head Neck Pathol* 2008; 2: 343-7.
4. Fetsch JF, Montgomery EA, Meis JM. Calcifying fibrous pseudotumor. *Am J Surg Pathol* 1993; 17: 502-8.
5. Binmadi NO, Packman H, Papadimitriou JC, Scheper M. Oral Inflammatory Myofibroblastic Tumor Case Report and Review of

- Literature. *Open Dent J* 2011; 5: 66-70.
6. Kempson RL, Fletcher CDM, Evans HL, Henrickson MR, Sibley RS. Tumors of the Soft Tissues, Atlas of Tumor Pathology, 2001, AFIP Third Series, Fascicle 30. *Br J Dermatol* 2002; 146: 705-18.
  7. Xiao X, Ba Y, Zhang Y. Inflammatory myofibroblastic tumor in the maxillary sinus: a case report and review of literature. *Lin Chung Er Bi Yan Hou Tou Jing Wai Ke Za Zhi* 2012; 26: 67-70.
  8. Gamsizkan M, Yildirim C, Da? K, Günhan O. Calcifying Fibrous Tumor: A Case Report. *Turk Patoloji Derg* 2015; 31: 141-4.
  9. Poh CF, Priddy RW, Dahlman DM. Intramandibular inflammatory myofibroblastic tumour: A true neoplasm or reactive lesion? *Oral Surg Oral Med Oral Pathol Oral Radiol Endod* 2005; 100: 460-6.
  10. Coffin CM, Watterson J, Priest JR, Dehner LP. Extrapulmonary inflammatory myofibroblastic tumor (inflammatory pseudotumor). A clinicopathologic and immunohistochemical study of 84 cases. *Am J Surg Pathol* 1995; 19: 859-72.
  11. Palaskar S, Koshti S, Maralingannavar M, Bartake A. Inflammatory myofibroblastic tumor. *Contemp Clin Dent* 2011; 2: 274-7.
  12. Ben-Izhak O, Itin L, Feuchtwanger Z, Lifschitz-Mercer B, Czernobilsky B. Calcifying fibrous pseudotumor of mesentery presenting with acute peritonitis: case report with immunohistochemical study and review of literature. *Int J Surg Pathol* 2001; 9: 249-53.
  13. Chavez C, Hoffman MA. Complete remission of ALK-negative plasma cell granuloma (inflammatory myofibroblastic tumor) of the lung induced by celecoxib: A case report and review of the literature. *Oncol Lett* 2013; 5: 1672-6.
  14. Butrynski JE, D'Adamo DR, Hornick JL, Dal Cin P, Antonescu CR, Jhanwar SC, et al. Crizotinib in ALK-rearranged inflammatory myofibroblastic tumor. *N Engl J Med* 2010; 363: 1727-33.
  15. Hytiroglou P, Brandwein MS, Strauchen JA, Mirante JP, Urken ML, Biller HF. Inflammatory pseudotumor of the parapharyngeal space: case report and review of the literature. *Head Neck* 1992; 14: 230-4.
  16. Hill KA, Gonzalez-Crussi F, Chou PM. Calcifying fibrous pseudotumor versus inflammatory myofibroblastic tumor: a histological and immunohistochemical comparison. *Mod Pathol* 2001; 14: 784-90.
  17. Ide F, Shimoyama T, Kato T, Horie N, Kusama K. Inflammatory Pseudotumor and Related Lesions of the Oral and Maxillofacial Region: A critical reappraisal based on recent information. *Oral Med Pathol* 2001; 5: 41-7.
-