

Arthroscopic removal of an intraarticular bullet from the hip joint: A case report

Tahsin Gurpinar, Yusuf Ozturkmen

Abstract

Despite the fact that gunshots are a common entity, intra-articular bullets in the hip joint are rarely seen. Since retained bullets in the joints can cause both local damage and systemic toxicity, removal of the bullet is mandatory. We present the case of a 48-year-old man who came with an intra-articular bullet fragment in the hip joint which was extracted arthroscopically in February 2017. The operation was performed in the supine position and portals were placed under fluoroscopic guidance. Standard portals were established, and no additional portal was needed. The operation lasted 30 min and duration of traction was 46 min. No complication was observed, and the patient was allowed full weight bearing just after the surgery. Hip arthroscopy is a reliable option to prevent excessive soft tissue dissection and possible iatrogenic complications of open surgery. In addition, it has a very little complication rate compared to open procedures which require dislocation of the joint.

Keywords: Hip arthroscopy, Bullet in hip, Intraarticular bullet.

Introduction

Hip arthroscopy is an evolving procedure to access the hip joint for diagnosing and treating disorders of the hip since it was first described by Burman in 1931.¹ Common indications are femoro-acetabular impingements, labral tears, synovitis, cartilage lesions, mild joint dysplasia, septic arthritis and intra-articular loose bodies.² Furthermore, in many disorders of the hip, arthroscopy has been replacing traditional open approaches which typically require a wide dissection and thus causing considerable morbidity and prolonged recovery time. On the other hand, a retained bullet in a joint can not only lead to mechanical damage and proliferative synovitis but also can cause systemic absorption of lead and lead poisoning.³ These patients can present with the non-specific neurologic, and gastrointestinal symptoms of lead poisoning and these cases can be difficult to diagnose. In the light of the current literature. We report a

.....
Department of Orthopaedics and Traumatology, Istanbul Research and Education Hospital, Istanbul, Turkey.

Correspondence: Tahsin Gurpinar. Email: tahsingurpinar@msn.com

case of a retained bullet in the hip joint and its arthroscopic removal.

Case Report

A 48-year-old man was admitted to Istanbul Research and Education Hospital, Orthopaedics and Traumatology Department in February 2017 with multiple gunshot wounds. He was injured in a terror attack in Afghanistan, and his initial treatment was performed there. He did not have any hospital records, but according to his statement, after his stabilization, he was sent to our hospital for further evaluation and treatment. On his initial examination in our department, we observed multiple wounds on his lower extremity. The patient was mobile, and no neurological deficit was noted. The X-ray revealed foreign bodies in his right calf, left thigh, butt and in the hip joint. It was decided to leave all the foreign bodies in place apart from the one in the hip joint. Surgical removal of the bullet in the hip joint was planned to avoid joint degeneration, proliferative synovitis and possible systemic absorption of lead. Patient was informed and the consent was obtained for the surgery. CT scan was performed as a part of the preoperative plan to evaluate the exact location of the bullet and any possible fracture (Figure-1).

Under general anaesthesia and muscle relaxation, traction was applied on the fracture table to distract the hip joint properly. Standard anterolateral portal was established under fluoroscopic guidance, and then the joint was distended with 20 mL of saline solution. After getting in the joint with standard 30° scope, haemarthrosis was drained and the joint was irrigated to get a clear view. After obtaining a clear view, an anterior portal was established under direct visualization. Care was taken to maintain low intra-articular pressure to avoid fluid leakage which may lead to intraabdominal fluid extravasation. The femoral head and acetabular cartilage adjacent to the bullet did not appear to be traumatized but the bullet was found firmly embedded in the acetabulum. It was mobilized using a probe and removed from the joint with a grasper (Figure-2). After removal of the bullet, the joint was examined to rule out any free particles or cartilage fragments, and the injured articular cartilage was shaved. Following the complete diagnosis of the joint, traction was released, and the

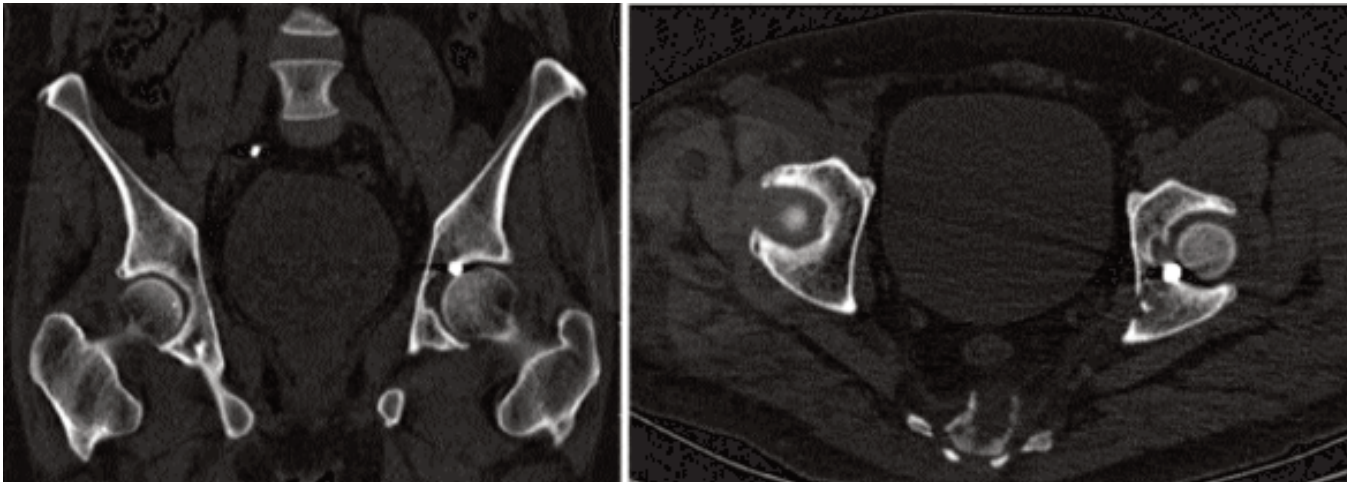


Figure-1: CT images of intra-articular bullet in the hip joint.

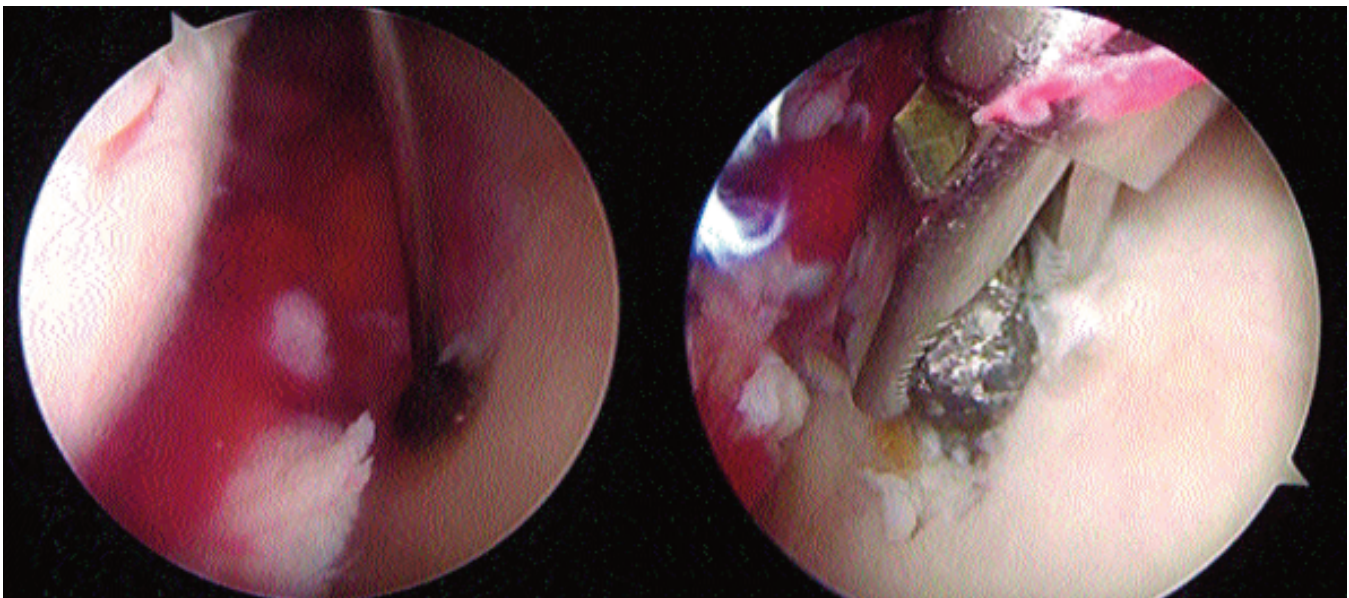


Figure-2: Arthroscopic view of embedded bullet and extraction from the joint.

portals were closed. The postoperative X-ray showed that the entire bullet was removed. After the surgery, a first-generation cephalosporin was administered, full weight-bearing was permitted. No complications were encountered. After a few weeks of follow up patient was sent back to his country.

Discussion

Intraarticular bullet fragments may dissolve in the synovial fluid over time which increases serum lead levels and can cause chronic lead poisoning. Gastrointestinal and neurologic systems are predominantly affected, and

non-specific symptoms such as abdominal pain, constipation, vomiting, dizziness, headache, and peripheral neuropathy are commonly seen. In further stages, fatal complications such as renal failure, seizures, and lead encephalopathy may occur, and it can be difficult to diagnose without a detailed history of the patient.^{3,4} Furthermore, lead fragments that remain intra-articular may also result in proliferative synovitis and lead arthropathy which can provoke joint destruction.^{4,5} In addition, mechanical influence of intraarticular fragments can damage the articular cartilage and consequently lead to arthrosis of the hip joint.⁵ Since hip arthroscopy is a

demanding procedure and open approaches are prone to major complications, orthopaedic surgeons may be reluctant to operate on these patients. However, surgical removal of intra-articular lead or metallic bullet fragments is crucial to prevent both systemic and local complications.

Compared to open surgeries, arthroscopic approach prevents extensive soft tissue dissection, causes less morbidity and gives a better cosmetic appearance and shorter rehabilitation time. Furthermore, open surgery has major complications such as avascular necrosis, femoral head-neck fracture, loss of fixation resulting in reoperation, trochanteric non-union, deep infection, and symptomatic heterotopic ossification. Ganz et al. reported 3.3% major complication rate in over 200 open approaches.⁶ This rate is reasonable in such a major surgery, but on the other hand, a recent systematic review on 6962 hip arthroscopies showed that hip arthroscopy has only 0.2% major complication rate. The most common major complication encountered in hip arthroscopy is intra-abdominal fluid extravasation.⁷ In our case, hip joint and acetabulum were traumatized by a bullet, so it is probably more vulnerable to fluid leakage and intraabdominal fluid extravasations. Hence, we believe that care should be taken to maintain low intra-articular pressure to avoid fluid extravasation particularly in traumatized hips and prolonged cases.

Regarding common complications, the literature states that traction injuries and neuropraxia are the most common ones, but they are usually associated with prolonged traction time or improper positioning. Foreign body extractions are typically simpler cases compared to other complicated procedures of hip arthroscopy, and these patients relatively have normal anatomic hips, so that duration of traction is expected to be shorter. In similar fashion, our traction time was 46 minutes, and this is reasonably shorter than recommended maximal traction times.

Sporadic cases of bullet removal from the hip joint have been reported in the literature. However, only a few of these cases have been performed exclusively arthroscopically as our case.⁸⁻¹⁰ We preferred standard

portals, but depending on the localization of the foreign body the direction of the second portal can be adjusted, or different portals can be established. In this patient, we could easily reach almost the entire joint, so in our opinion when performed meticulously, arthroscopic extraction of foreign bodies such as bullets is a reproducible and efficient treatment option.

Conclusion

The consequences of ignored or neglected intra-articular bullet fragments can be catastrophic. Arthroscopic removal of these fragments is a safe method which prevents possible local damages and systemic toxicity.

Disclaimer: None.

Conflict of Interest: None.

Funding Sources: None.

References

1. Burman MS. Arthroscopy or the direct visualization of joints: an experimental cadaver study. *Clin Orthop Relat Res.* 2001; 390:5-9.
2. Stevens MS, Legay DA, Glazebrook MA, Amirault D. The evidence for hip arthroscopy: grading the current indications. *Arthroscopy.* 2010; 26: 1370-83.
3. Begly JP, Lajam CM. Systemic Lead Toxicity Secondary to Retained Intraosseous Bullet A Case Report and Review of Literature. *Bull Hosp Jt Dis (2013).* 2016; 74: 229-33.
4. DeMartini J, Wilson A, Powell JS, Powell CS. Lead arthropathy and systemic lead poisoning from an intraarticular bullet. *AJR Am J Roentgenol.* 2001; 176: 1144.
5. Rehman MA, Umer M, Sepah YJ, Wajid MA. Bullet-induced synovitis as a cause of secondary osteoarthritis of the hip joint: A case report and review of literature. *J Med Case Rep.* 2007; 1: 171.
6. Ganz R, Gill TJ, Gautier E, Ganz K, Krügel N, Berlemann U. Surgical dislocation of the adult hip a technique with full access to the femoral head and acetabulum without the risk of avascular necrosis. *J Bone Joint Surg Br.* 2001; 83: 1119-24.
7. Kowalczyk M, Bhandari M, Farrokhyar F, Wong I, Chahal M, Neely S, et al. Complications following hip arthroscopy: a systematic review and meta-analysis. *Knee Surg Sports Traumatol Arthrosc.* 2013; 21: 1669-75.
8. Howse EA, Rogers JP, Stone AV, Mannava S, Stubbs AJ. Arthroscopic Bullet Removal From the Central and Peripheral Compartments of the Hip Joint. *Arthrosc Tech.* 2016; 5: e217-21.
9. Kaya I, Ugras A, Saglam N, Sungur I, Cetinus E. Bullet in hip joint. *Eurasian J Med.* 2013; 45: 141-2.
10. Sozen YV, Polat G, Kadioglu B, Dikici F, Ozkan K, Unay K. Arthroscopic bullet extraction from the hip in the lateral decubitus position. *Hip Int.* 2010; 20: 265-8.