

## Localized Injection of Streptomycin, Kenacort and Lidocaine combination for Symptomatic Pain Management of Knee Osteoarthritis

Muhammad Hamza,<sup>1</sup> Irfan Ahmed Nadeem,<sup>2</sup> Noor Fatima<sup>3</sup>

### Abstract

**Objective:** To determine the frequency of reduction of pain in symptomatic knee osteoarthritis by using combination injections.

**Methods:** The experimental study was conducted from January 1, 2010, to December 31, 2016, at Al-Noor Surgery Hospital, Chakwal, Pakistan, and comprised patients suffering from symptomatic knee osteoarthritis. All patients were injected intra-articularly and peri-articularly with a combination of streptomycin, kenacort and lidocaine. The effects of this injection were recorded immediately after injection, after a month and after a year. Data was analyzed using SPSS 21.

**Results:** Of the 169 patients, there were 70(41.40%) males and 99(58.60%) females. The overall mean age and pain duration was  $59.27 \pm 7.79$  years and  $10.5 \pm 5.1$  years respectively. No patient had pain immediately after the injection and after a month of follow-up. After a year, 145(86%) had a complete loss of pain compared to the baseline. Three (1.77%) patients required repetition of injection after a year. None of the patients suffered from septic arthritis or localised flare-ups and no one opted for knee joint arthroplasty.

**Conclusion:** Combination of streptomycin, low-dose corticosteroids and lidocaine had immediate and prolonged effect in reducing pain in patients with knee osteoarthritis.

**Keywords:** Knee, Osteoarthritis, Corticosteroid injections, Streptomycin, Lignocaine. (JPMA 68: 1316; 2018)

### Introduction

Knee osteoarthritis (KOA) is a common joint disorder with worldwide prevalence of 24% among general adult population. Its prevalence increases with age and is more common in females.<sup>1,2</sup> KOA is also common in the Asia-Pacific region.<sup>3-6</sup> Being a common disease, it has significantly increased the healthcare cost.<sup>2</sup> Osteoarthritis is described as an inflammatory and degenerative joint disorder.<sup>4,7,8</sup> It clinically presents as mono-articular or oligo-articular joint involvement with knee, hips, spine and hands being commonly involved.<sup>4,7</sup> Therefore, it is logical to consider localised treatment modalities to avoid undue systemic adverse effects.<sup>7,9</sup> Moreover, severe pain caused by osteoarthritis can limit mobility of these joints.<sup>7,8,10,11</sup> Symptomatic relief of pain can restore mobility and is, therefore, the main desired outcome of treatment.<sup>9,12</sup>

Among the different treatment modalities which are being used around the world, like non-pharmacological, pharmacological, stem cell therapy and surgery, intra-articular corticosteroid therapy is the most commonly

used in clinical practice in the management of osteoarthritis.<sup>7-9,12,13</sup> Many pharmacological therapies are directed at controlling pain, which will restore mobility of joints.<sup>1,14</sup> Osteoarthritis being a localised low-grade inflammatory disease, intra-articular corticosteroid injections have shown to have most beneficial effects, but their effect is limited to a short span, from a week to 4 weeks.<sup>7,12</sup> Ultimate cure is joint replacement, but prosthetic joints can have severe and life-threatening complications.<sup>15</sup> Moreover, a recent study has shown that the current prevailing practice of knee arthroplasty in KOA does not substantially affect quality of life considering increase in the healthcare cost.<sup>16</sup>

The current study was planned to determine the frequency of reduction of pain in symptomatic KOA by using multi-drug combination injections. It was hypothesised that intra-articular and peri-articular injection containing anti-inflammatory agent, analgesia and antibiotics will reduce pain immediately with long-term effects and will also protect against joint infection.

### Patients and Methods

The single-centre, experimental study was conducted from January 1, 2010, to December 31, 2016, at Al-Noor Surgery Hospital, Chakwal, Pakistan. The hospital caters to patients from the lower middle socioeconomic status.

.....  
<sup>1</sup>Rawalpindi Medical University and Allied Hospitals, Rawalpindi, <sup>2</sup>Al-Noor Surgery Hospital, Hospital Road, Chakwal, <sup>3</sup>Rawalpindi Medical University, Rawalpindi, Pakistan.

**Correspondence:** Muhammad Hamza. Email: mhamza7593@gmail.com

Sample size was calculated using power and sample size calculator.<sup>17</sup> The target was to show 15% more improvement in pain intensity compared to results of previous study i.e. 47% reduction in current knee pain intensity determined by electronic visual analogue scale (VAS).<sup>8</sup> Based on 80% power and 5% type 1 error ( $\alpha$ ), the calculated sample size was 83. Considering the dropouts and new interventional combination, it was doubled and the subjects were enrolled using convenient sampling. All participants gave written informed consent. Those included were aged 40-75 years with body mass index <35, who were clinically diagnosed of symptomatic KOA with confirmation by standardised posterior-anterior knee X-ray. All participants had knee pain. In all the participants, we chose the most symptomatic knee as the target knee for treatment. All participants had haemoglobin (Hb) > 12g/dl and total serum calcium concentration >8.5mg/dL. Those who were taking oral corticosteroids or non-steroidal anti-inflammatory drugs (NSAIDs) within the preceding 1 month or had received previous corticosteroid injections, contraindications to corticosteroids or allergic response to agents or contrast material, blood coagulopathy or patients on anticoagulant therapy, lower limb fracture, varus and valgus knee joint deformity, history of knee arthroplasty and lower backache were excluded.

The patient's knee was prepared with a solution of pyodine, which was allowed to dry for 1-2 minutes. The area was draped with sterile towels, and disposable sterile gloves, syringes and needles were used. The skin and peri-articular soft tissue were injected with 2% lidocaine using an insulin syringe. Aspiration of the joint effusion was performed in all the patients who had knee effusion with osteoarthritis. The joint was injected with a combination of 250mg of streptomycin, 10mg of triamcinolone acetone and 2.5ml of lignocaine (2%) added to distilled water so that the maximum volume of fluid injected was 5cc with 2cc intra-articular and 3cc peri-articular deposition, especially at the pain trigger spot around the knee joint. The intra-synovial space was entered with a 23-gauge (38mm), 1-inch needle, and a 5ml Luer-lock syringe and aspiration of the joint was attempted by an experienced surgeon to ensure correct bolus

deposition in the joint cavity. Full flexion and extension of knee joint were performed immediately after the injection and the patients were not instructed to rest, but were asked to perform routine activity of their life immediately without any medicines like corticosteroids, acetaminophen or NSAIDs during the follow-up period of 1 year. Outcomes were measured at baseline (before injection), immediately after the injection, after a month and at the end of the 1-year follow-up period. Patients' files were maintained and information was recorded in a structured proforma.

Data analysis was carried out using SPSS 21. All categorical variables were presented as frequencies and percentages, whereas means along with standard deviations (SDs) were calculated for numerical data.

## Results

Of the 169 patients, there were 70(41.40%) males and 99(58.60%) females. The overall mean age was  $59.27 \pm 7.79$  years (Figure-1). The mean duration of symptoms was  $10.5 \pm 5.1$  years. Besides, 61(36.1%) patients had knee effusion.

None of the patients had any pain immediately after the injection and after a month's follow-up. The perceived loss of pain at rest and after movement in knee at 1 year follow-up 100% in 145(86%) cases (Figure-2). Only 3(1.78%) patients required repetition of injection after the 1-year follow-up, while rest of the patient didn't opt for

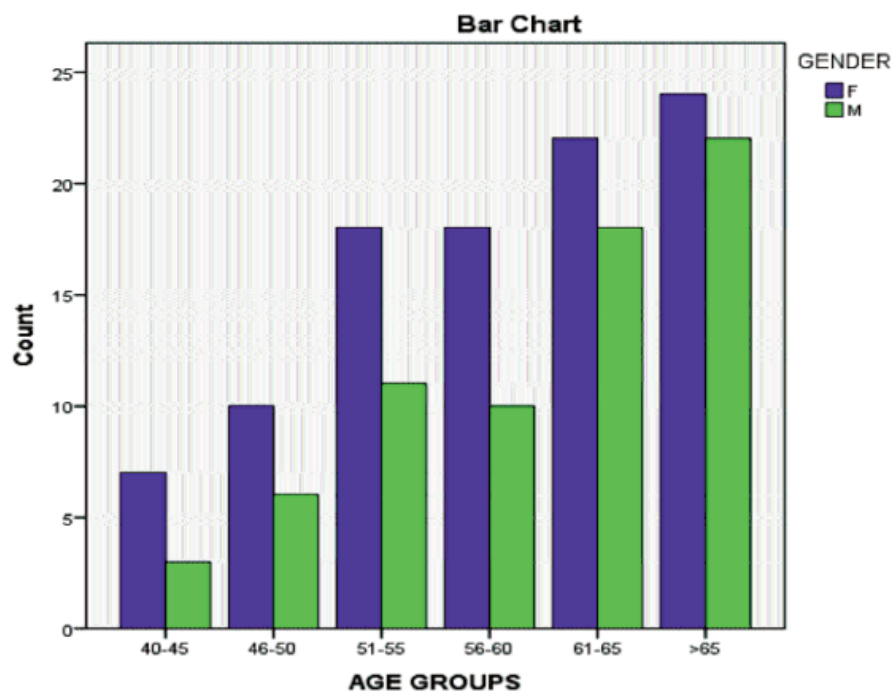


Figure-1: Disease distribution among different age groups in respective gender.

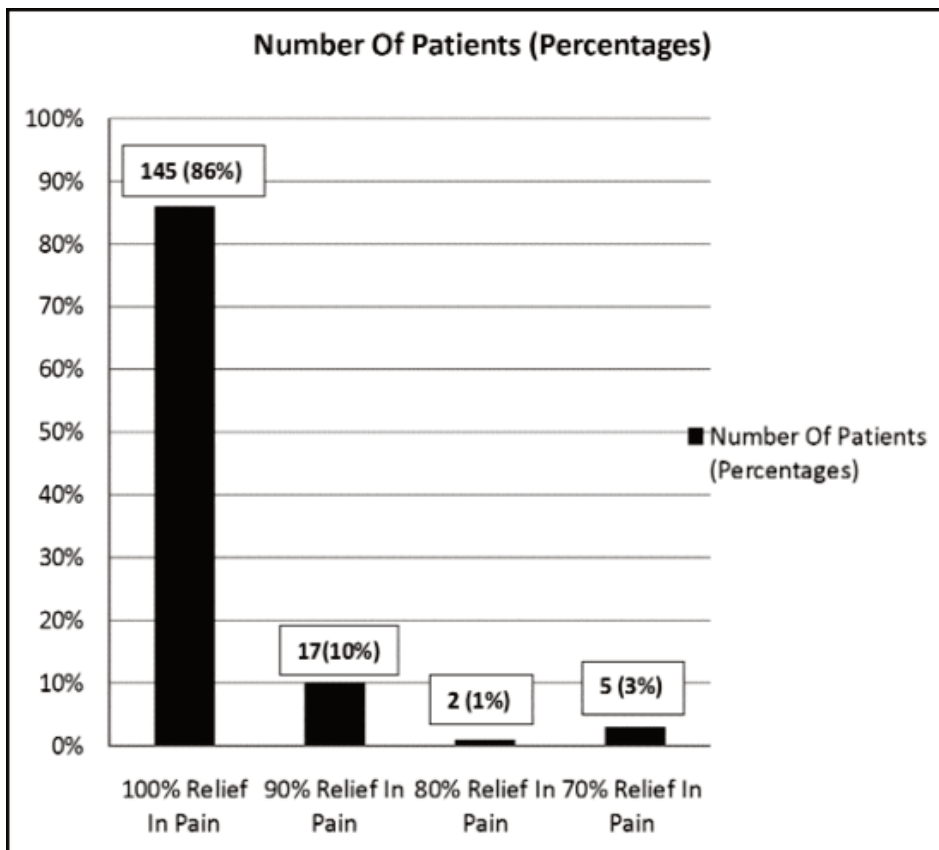


Figure-2: The perceived loss of pain at rest and after movement in knee joint at 1-year follow-up.

more injections as they were satisfied with the treatment.

None of the patients suffered from septic arthritis. None of the patients opted for joint replacement after the injection therapy. No localised flare-ups were seen in any patient. No loss of joint position and proprioception sensations were reported by any patient.

### Discussion

Intra-articular corticosteroid therapy is a common clinical practice used in the management of osteoarthritis.<sup>7,8,12,13</sup> This therapy is also part of the recommendations made by the American College of Rheumatology (ACR) for the treatment of osteoarthritis, and of the Knee and Osteoarthritis Research Society International(OARSI) guidelines for the non-surgical management of KOA.<sup>13,18</sup> But its effects are limited for only 1-4 week.<sup>2,7,8,11,12</sup> Intra-articular injection of a combination of local anaesthetic and corticosteroids in KOA is also mentioned in literature. Jørgensen et al injected a combination of local anaesthetic and corticosteroids intra-articularly for KOA and found that pain sensitivity was reduced immediately but for only 2 weeks.<sup>8</sup> Hence, to have a long-time effect, frequent repetition of injections is required,

but this is not a safe option as weight-bearing joints should not be injected more than once per month.<sup>2</sup> In our study, we used combination of local analgesia, anti-inflammatory and streptomycin, an antibiotic, in patients with KOA. To our knowledge, this is the first study to use this combination for the management of KOA. The effect of this combination was an immediate decrease in patients' perception of pain immediately after the injection therapy. Moreover, 145(86%) had no pain after a 1-year follow-up compared to the pain in knee at the baseline. Hence, the majority (98.22%) of patients did not require repetition of injection therapy, which is a major problem associated with the short-term effect of corticosteroids.<sup>2,7,8,11,12</sup> Only 1.78% required repetition of injection once after a duration of 1 year, which is safer as stated before and proposes that effects of this management can be long lasting.

Streptomycin is an antibiotic which is also very effective in treating painful conditions. In literature, streptomycin has been described for relief of facial pain. Sokolovic et al, Stajcic et al and Kriener published papers showing effectiveness of this antibiotic for relieving pain associated with idiopathic trigeminal neuralgia.<sup>19-21</sup> Similarly, Waghay et al. reported three cases of post-herpetic neuralgia getting benefit from streptomycin-lidocaine injections.<sup>22</sup> These beneficial effects of streptomycin are due to inhibition of release of acetylcholine at the nerve endings and neuronal stabilisation.<sup>21,22</sup> Moreover, side effect of streptomycin injection is minimal and pain caused by solution deposition is decreased by adding local anaesthetic to solve.<sup>22</sup> This led us to believe that streptomycin should be used with corticosteroids and lignocaine to effectively relieve symptomatic painful conditions. We propose that there might be a synergistic effect of these three agents when they are used together, an effect which can relieve pain immediately and for prolonged time compared to using only intra-articular analgesia and anti-inflammatory agents. However, further research is

required on understanding the role of streptomycin as a pain-relieving agent.

Corticosteroids are linked to many complications, especially related to their high dose.<sup>23</sup> However, increasing the dose of corticosteroids has shown to increase response time (16-24 weeks), particularly at 50mg equivalent of the corticosteroids dose.<sup>2</sup> But we only used 10mg of triamcinolone Acetonide, which is one-fourth of the recommended corticosteroid dose (40mg of triamcinolone acetonide) by ACR for the knee joint.<sup>(12)</sup> This combination not only relieves symptomatic pain for a long time, but it also decreases the required dose of corticosteroids, and, hence, complications associated with corticosteroids overdose will not be seen in this injection therapy. Intra-articular injection of steroids are thought to be linked to the destruction of the knee, but there is no strong evidence which supports the progression of knee disease by steroid injections.<sup>7,12</sup> Triamcinolone is chondro-protective and doesn't allow osteophyte formation to take place.<sup>7,12</sup> Overall, steroids are safer and better compared to alternative strategies such as NSAIDs, because this disease is common in old age where NSAIDs are linked to many complications.<sup>2,7</sup> Hence, this lack of toxicity is the main factor responsible for making intra-articular corticosteroid injections one of the main treatment options for KOA.<sup>7</sup>

Corticosteroid injection for osteoarthritis can cause crystal-induced arthritis or post-injection flares, but symptoms are usually milder and rarely last more than 48 hours.<sup>2</sup> There was no report of flare-up when local anaesthetic was used with corticosteroids which shows that this combination could prevent possible symptomatic flare-up associated with a corticosteroid injection.<sup>23</sup> Similarly, none of our patients had these complications when combination of streptomycin, low-dose corticosteroids and lidocaine was used.

Septic arthritis, although rare (1:50,000), is a known complication of intra-articular injections, but we did not encounter this complication in any of our cases.

Most patients develop pain as the principal clinical problem of OA.<sup>6,8</sup> Inflammation not only in the joint but also in the peri-articular tissue is equally responsible for causing this principal clinical problem of OA.<sup>8</sup> Hence, in order to effectively relieve joint pain in these patients, a small peri-articular dose along with intra-articular dose is essential which is also practised at our centre and has shown to be effective. Our results suggest that intra-articular and peri-articular anti-inflammatory treatment is essential in controlling pain in patients with KOA, but this has to be confirmed in controlled trials.

Our study is a single-group experimental study which might be one of the limiting factors. In order to compare our results properly, it is required that three groups are made: only corticosteroids injection therapy group, a combination of local anaesthetic and corticosteroids injection therapy group, and combination of local anaesthetic, corticosteroids and streptomycin injection therapy group. Their results need to be compared with each other in the same timeframe in a single centre. The other limitation of our study was that the results of a single-center study could not be generalised to the other medical care centres around the world. For this purpose, we need to have a large multi-center trial, large study sample, multiple resources and a long post-injection follow-up period to study its long-term effects. However, due to limited resources, we were unable to perform such a trial. But nevertheless, our data is the first of its kind and will provide important information for future researches.

## Conclusion

Intra-articular and peri-articular injection of a combination of anti-inflammatory agent, analgesia and antibiotics for the treatment of KOA was more effective in controlling pain than the use of corticosteroids and local anaesthetics only. This combination produced immediate and long-lasting effects with early restoration of patients without increasing the healthcare cost.

**Disclaimer:** None.

**Conflict of Interest:** None.

**Source of Funding:** None.

## References

1. Fernandes L, Hagen KB, Bijlsma JWJ, Andreassen O, Christensen P, Conaghan PG, et al. EULAR recommendations for the non-pharmacological core management of hip and knee osteoarthritis. *Ann Rheum Dis.* 2013; 72:1125-35.
2. Lambert RGW, Hutchings EJ, Grace MGA, Jhangri GS, Conner-Spady B, Maksymowych WP. Steroid injection for osteoarthritis of the hip: a randomized, double-blind, placebo-controlled trial. *Arthritis Rheumatol.* 2007; 56: 2278-87.
3. Tang X, Wang S, Zhan S, Niu J, Tao K, Zhang Y, et al. The prevalence of symptomatic knee osteoarthritis in China: results from the China health and retirement longitudinal study. *Arthritis Rheumatol.* 2016; 68:648-53.
4. Pal CP, Singh P, Chaturvedi S, Pruthi KK, Vij A. Epidemiology of knee osteoarthritis in India and related factors. *Indian J Orthop.* 2016; 50:518-22.
5. Davatchi F, Sandoughi M, Moghimi N, Jamshidi AR, Tehrani Banihashemi A, Zakeri Z, et al. Epidemiology of rheumatic diseases in Iran from analysis of four COPCORD studies. *Int J Rheum Dis.* 2016; 19:1056-62.
6. Iqbal MN, Haidri FR, Motiani B, Mannan A. Frequency of factors associated with knee osteoarthritis. *J Pak Med Assoc.* 2011; 61:786-9.
7. Uthman I, Raynauld JP, Haraoui B. Intra-articular therapy in osteoarthritis. *Postgrad Med J* 2003; 79:449-53.
8. Jorgensen TS, Graven-Nielsen T, Ellegaard K, Danneskiold-Samsøe

- B, Bliddal H, Henriksen M. Intra-articular analgesia and steroid reduce pain sensitivity in knee OA patients: an interventional cohort study. *Pain Res Treat.* 2014; 2014:710490.
9. Wehling P, Moser C, Maixner W. How does surgery compare with advanced intra-articular therapies in knee osteoarthritis: current thoughts. *Ther Adv Musculoskelet Dis.* 2016; 8:72-85.
  10. Rosemann T, Wensing M, Joest K, Backenstrass M, Mahler C, Szecsenyi J. Problems and needs for improving primary care of osteoarthritis patients: the views of patients, general practitioners and practice nurses. *BMC Musculoskelet Disord.* 2006; 7:48.
  11. Jüni P, Hari R, Rutjes AW, Fischer R, Silleta MG, Reichenbach S, et al. Intra-articular corticosteroid for knee osteoarthritis. *Cochrane Database Syst Rev.* 2015; 10:CD005328.
  12. Arroll B, Goodyear-Smith F. Corticosteroid injections for osteoarthritis of the knee: meta-analysis. *BMJ.* 2004; 328:869.
  13. McAlindon TE, Bannuru RR, Sullivan MC, Arden NK, Berenbaum F, Bierma-Zeinstra SM, et al. OARSI guidelines for the non-surgical management of knee osteoarthritis. *Osteoarthritis Cartilage.* 2014; 22:363-88.
  14. Henriksen M, Klokke L, Graven-Nielsen T, Bartholdy C, Schjødt Jørgensen T, Bandak E, et al. Association of exercise therapy and reduction of pain sensitivity in patients with knee Osteoarthritis: a randomized controlled trial. *Arthritis Care Res.* 2014; 66:1836-43.
  15. Cross MJ. Complications of total knee arthroplasty: background, complications, long-term problems. [Online] 2015 [Cited 2015 Dec 21]. Available from URL: <http://emedicine.medscape.com/article/1250540-overview>
  16. Ferket BS, Feldman Z, Zhou J, Oei EH, Bierma-Zeinstra SMA, Mazumdar M. Impact of total knee replacement practice: cost effectiveness analysis of data from the Osteoarthritis Initiative. *BMJ.* 2017; 356:j1131.
  17. HyLown Consulting LLC G. Test 1 Proportion 1-Sample, 2-Sided Equality | Power and Sample Size Calculators | HyLown. Powerandsamplesize.com.[Online] [Cited 2016 Sep 11]. Available from: URL: <http://powerandsamplesize.com/Calculators/Test-1-Proportion/1-Sample-Equality>
  18. Hochberg MC, Altman RD, April KT, Benkhalti M, Guyatt G, McGowan J, et al. American college of rheumatology 2012 recommendations for the use of nonpharmacologic and pharmacologic therapies in osteoarthritis of the hand, hip, and knee. *Arthritis Care Res (Hoboken).* 2012; 64:465-74.
  19. Sokolovic M, Todorovi? L, Stajcic Z, Petrovic V. Peripheral streptomycin/lidocaine injections in the treatment of idiopathic trigeminal neuralgia. A preliminary report. *J Maxillofac Surg.* 1986;14:8-9.
  20. Stajcic Z, Juniper RP, Todorovic L. Peripheral streptomycin/lidocaine injections versus lidocaine alone in the treatment of idiopathic trigeminal neuralgia. A double blind controlled trial. *J Craniomaxillofac Surg.* 1990;18:243-6.
  21. Kreiner M. Use of streptomycin-lidocaine injections in the treatment of the cluster-tic syndrome. Clinical perspectives and a case report. *J Craniomaxillofac Surg.* 1996; 24:289-92.
  22. Waghray S, Asif SM, Duddu MK, Arakeri G. Streptomycin-lidocaine injections for the treatment of postherpetic neuralgia: report of three cases with literature review. *Eur J Dent.* 2013; 7:S105-10.
  23. Henriksen M, Christensen R, Klokke L, Bartholdy C, Bandak E, Ellegaard K, et al. Evaluation of the benefit of corticosteroid injection before exercise therapy in patients with osteoarthritis of the knee: a randomized clinical trial. *JAMA Intern Med.* 2015; 175:923-30.
-