

## Ectopic cervical thymic cyst in a seven year old: a diagnostic challenge

Haissan Iftikhar, Shabbir Akhtar

### Abstract

Cervical thymus cyst is a rare entity and resembles lymphangioma or branchial cleft cyst therefore, presents as a diagnostic challenge. It has a slight male predominance and presents on the left side of the neck in up to 70% of cases. It is a painless mass that progressively increases. We present a case of a seven year old child with a right sided neck swelling that would increase on phonation therefore, adding to the complexity of the case. Surgical excision was performed and final histopathology revealed an ectopic thymic cyst.

**Keywords:** Thymus, Head and neck neoplasms, Pediatrics.

### Introduction

Cervical thymic cyst is a rare entity with just over a 100 cases reported.<sup>1</sup> It presents as a diagnostic challenge as it mimics lymphangioma and branchial cleft cyst which are relatively more common in the paediatric age group.

The thymus arises from the third and the fourth pharyngeal pouch during the sixth week of gestation; it descends from near the pyriform sinus, adherent to the carotid sheath and the pericardium, to the anterosuperior mediastinum which is its final resting place during the seventh and the eighth gestational week.<sup>1,2</sup> The remnant tissue can however deposit anywhere along the tract of descent from the angle of the mandible to the manubrium sternum.<sup>1</sup>

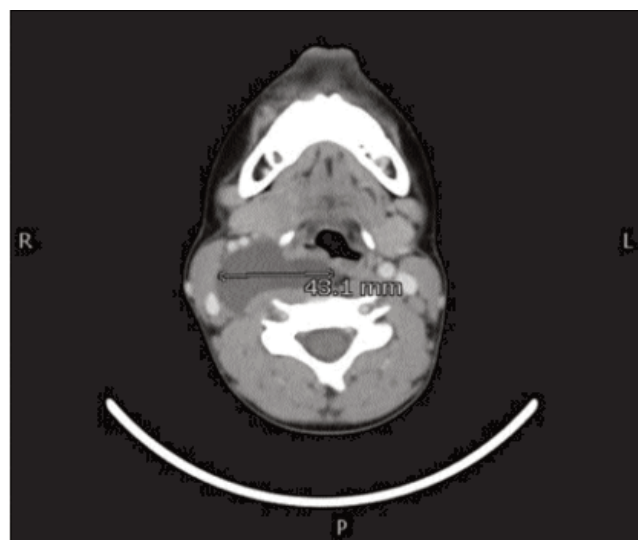
The other theories explaining the presence of ectopic thymic tissue in the neck include failure of the thymic tissue to descend, persistence of thymopharyngeal duct and presence of degenerating Hassell's corpuscles.<sup>2,3</sup>

### Case Report

Patient was a seven year old male child who presented to the out-patient clinic of the Aga Khan University Hospital, Karachi in May 2016 with parents complaining of a right sided neck swelling that would increase in size when the patient would speak and it would subside during rest. The parents first noticed this swelling 4 months ago and it slightly increased in size over time. It was not associated

.....  
Aga Khan University Hospital, Karachi.

**Correspondence:** Shabbir Akhtar. Email: shabbir.akhtar@aku.edu



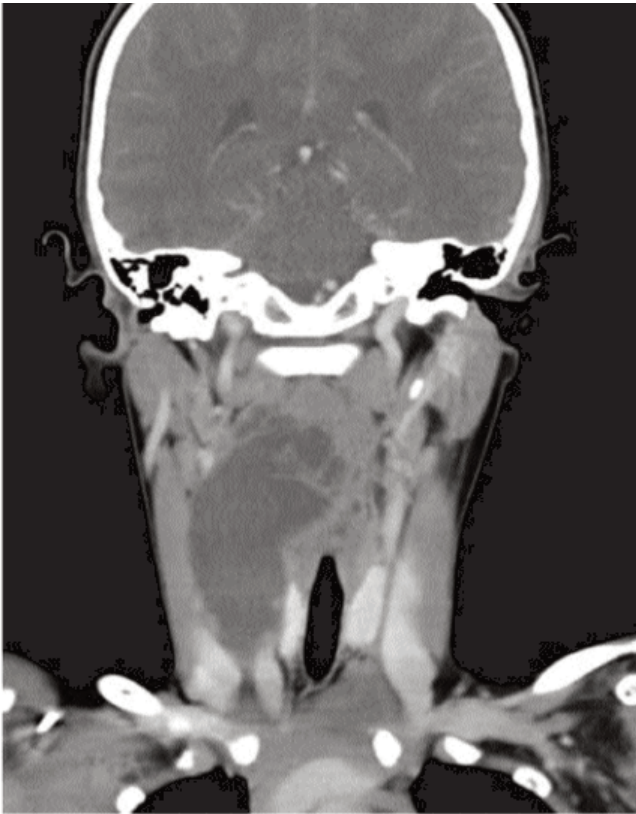**Figure-1:** CT-Scan axial cut showing a non-enhancing image involving the parapharyngeal space.

with any other complaint, neither compressive symptoms nor any cranial nerve deficit.

On examination the swelling was not very prominent however the neck was slightly asymmetric with fullness on the right side when the patient would start shouting or straining. It was around 2 x 3cm, ill defined and non-mobile. It did not involve the skin but did seem to be tethered to the under lying structures. There were no signs of inflammation and no cervical lymphadenopathy.

The patient had no prior medical or surgical history and was otherwise in good health and had no prior history of treatment.

CT scan neck was advised which revealed a multiseptated non-enhancing low attenuating lesion arising in the right cervical region approximately measuring 25.7 x 43.1 x 86.2 mm in AP, transverse and craniocaudal dimensions. (Figure-1, 2) Superomedially it was extending up to the right parapharyngeal space slightly displacing the trachea. Inferiorly it was extending to the lower border of the right thyroid lobe. Laterally it was displacing and splaying the right internal jugular vein and common carotid artery. CT-scan was chosen owing to its cost effectiveness over MRI.



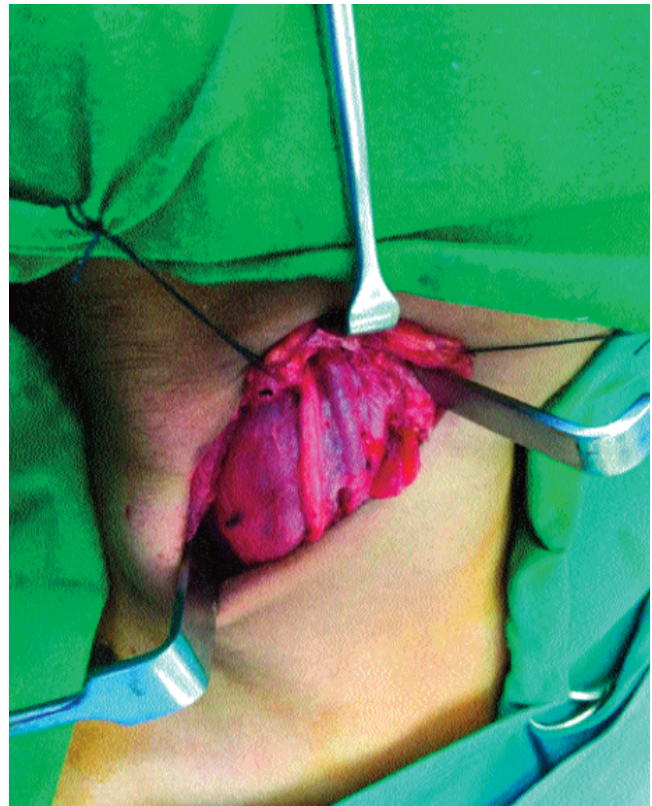**Figure-2:** CT-Scan coronal cut showing the medial extent of the mass.

Complete blood count was essentially normal with the haemoglobin of 12.7g/dl (11.5-15.5g/dl), White blood count of 6.0 K/ $\mu$ L (5.0-13.0K/ $\mu$ L) with 46.5mm<sup>3</sup> neutrophils and 44.0 mm<sup>3</sup> lymphocytes.

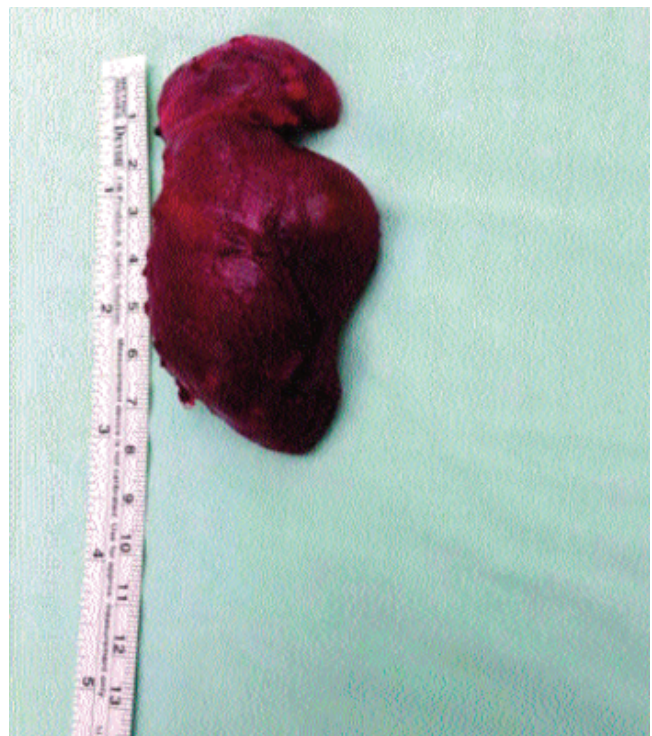Patient was electively taken for surgery. Cervical skin crease incision was given on the right side, intra-operatively the cystic mass was seen deep to the sternocleidomastoid muscle extending superiorly in the para-pharyngeal space and displacing the great vessels, although the mass was not adherent to the surrounding structures but its removal was difficult as it was deep to the carotid, vagus and internal jugular vein (Figure-3).

Final histopathological specimen to our surprise revealed it to have scattered Hassall's corpuscles which are pathognomonic for thymus<sup>2</sup> (Figure-4,5), in our case the mass had both the solid and a cystic component. The walls exhibited marked fibrinous debris with foreign body type giant cell reaction and formation of numerous cholesterol clefts.

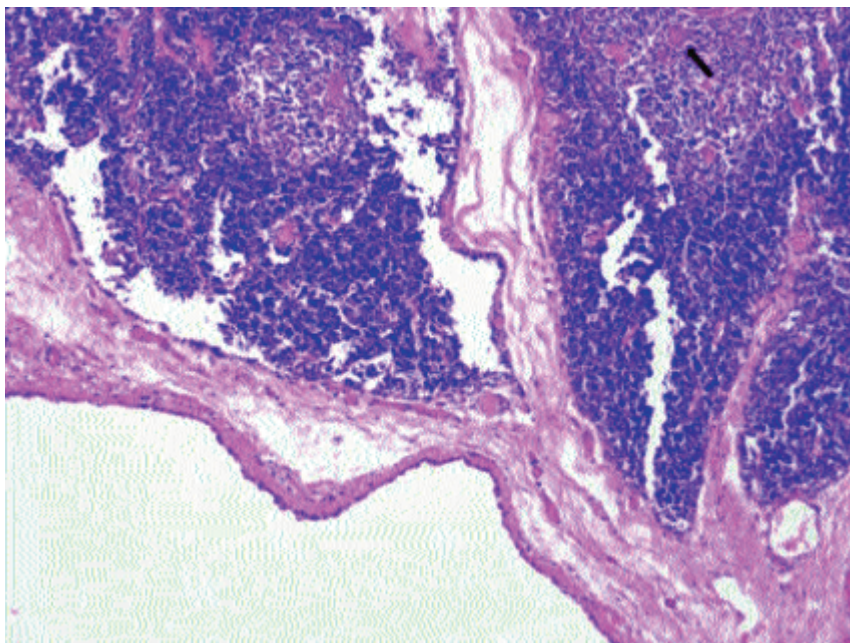
Post-operatively the patient remained stable. Neck drain was removed the following day and the patient discharged. Patient was assessed for cranial nerve



**Figure-3:** Intra-operative view of the lesion deep to the great vessels and nerve.



**Figure-4:** Final specimen post excision.



**Figure-5:** H&E stained section showing cyst wall with underlying thymic tissue showing hassall's corpuscles (arrow) (H&E x 400).

functions, swallowing, voice changes and shoulder function and they were normal post-operatively. Subsequent follow-ups were unremarkable and no further treatment was given to the patient. The apprehensive parents were reassured of the benign nature of the disease and for no further work-up as the patient did not exhibit any other symptom. Ethical review committee exemption and parents consent was taken prior to writing this case report.

## Discussion

Ectopic thymic cyst was first described by Pollosona and Piery in 1901 when an attempt at partial excision was made.<sup>4</sup> Ectopic cervical thymic tissue can present in three forms: Solid thymic tissue, thymic cyst and mixed lesion.<sup>1</sup>

The ectopic cervical thymic cysts usually present as a painless mass in the age group of 2-13, slight male predominance and for unknown reasons on the left up to 70%.<sup>1,2</sup> In our case the cystic swelling was on the right side which is in contrast to the literature. Ectopic thymic tissue is rarely seen in infancy and comprises of less than 10% of cases,<sup>1</sup> when they do they are generally symptomatic and solid in consistency. It is difficult to explain this embryological difference between solid and cystic however some authors suggest cystic degeneration in the later stage of the process.<sup>5</sup>

The differential diagnosis includes branchial cyst (3rd) as

it is found lower in the neck anterior to the sternocleidomastoid and is congenitally present. Lymphangiomas are soft but not cystic as was this lesion. Laryngocele appears on straining as was seen in our case but the lack of air on CT-Scan was against this differential.

Investigations include FNAC of the lesion which may reveal Hassell's corpuscles which is an identifiable feature in light microscopy.<sup>3</sup> In our case FNAC was not performed as it is not a useful tool for cystic masses in general. Imaging modalities include ultrasound neck which would differentiate a solid from a cystic mass.<sup>3</sup> MRI is the imaging of choice which shows an isointense signal on both T1 and T2 and the solid thymic tissue to have the same signal intensity as the mediastinal thymus.<sup>3</sup> We suggested CT-scan in our case owing to its lesser cost as the patient has to bear the charges in our setup. Histopathology of the final specimen is otherwise the Gold standard though it has been shown

that morphologic and flowcytometric evaluation of specimen collected during FNAC can accurately identify ectopic thymic tissue.<sup>3</sup>

Thymic tissue starts to involute towards puberty (where some say after the age of 1 year) thereby advocating a conservative approach, on the other hand there are rare case reports of malignant transformation that advocate complete surgical excision of the mass,<sup>2,6</sup> also with an increasing size compressive symptoms start to develop which warrant a surgical excision. In our case the neck swelling was noted around the age of seven and was progressively increasing for the past couple of months. There has been no report yet of any immunological deficiency or recurrence following the removal of cervical thymic tissue.<sup>1</sup> Thymic hyperplasia may result following an infection or post vaccination which would resolve by an antibiotic therapy or steroid treatment.<sup>3</sup> There is lack of data on the natural history of the disease as most of the cases were diagnosed after the excision of the neck mass.<sup>3</sup>

We report this case to accent the importance of keeping thymic cyst as a differential while evaluating a child with cystic lateral neck mass, also what makes our case interesting is its unusual presentation of increasing swelling while phonating. In conclusion, though an ectopic thymic cyst in the neck is a benign condition but

Careful evaluation is mandatory to make the decision between surgical excision and conservative "wait and watch" approach. In our case the decision in favour of conservative approach was taken because the patient had no other symptoms and the cyst did not reveal any malignant transformation.

### Conclusion

We suggest that thymic cyst should be considered as a differential when operating for a neck mass in the paediatric age group. Though a benign lesion but the enlarging mass may cause compressive symptoms. FNAC of the neck mass in children not resolving with empirical antibiotic therapy may prove to be diagnostic.

**Disclaimer:** None to declare.

**Financial Disclosure:** This study was not funded by any authority or institute.

**Conflict of Interest:** None.

### References

1. Oztürk H, Karnak I, Deveci S, Süreç I, Cetinkursun S. Multilocular cervical thymic cyst: an unusual neck mass in children. *Int J Pediatr Otorhinolaryngol.* 2001; 61: 249-52.
2. Neslihan Yaprak, Pınar Güzel, Havva Serap Toru, Abdullah Erdoğan, Alper Tunga Derin, et al. Multilocular Cervical Thymic Cyst: Rare Cervical Lesion should kept in Mind in Differential Diagnosis of Pediatric Cervical Masses. *J Otol Rhinol.* 2015; 2: 2-12.
3. Schloegel LJ, Gottschall JA. Ectopic cervical thymus: is empiric surgical excision necessary? *Int J Pediatr Otorhinolaryngol.* 2009; 73: 475-9.
4. Pollosson A, Piery M. Un cas d'epithelioma primitif du thymus. *Prov Med Lyons.* 1901; 15: 1-4.
5. Loney DA, Bauman NM. Ectopic cervical thymic masses in infants: a case report and review of the literature. *Int J Pediatr Otorhinolaryngol.* 1998; 43: 77-84.
6. Yamashita S, Yamazaki H, Kato T, Yokota T, Matsumoto N, Matsukura S. Thymic carcinoma which developed in a thymic cyst. *Intern Med.* 1996; 35: 215-8.