

Prognostic significance of optic nerve sheath diameter on computed tomography scan with severity of blunt traumatic brain injury in the emergency department

Shahan Waheed,¹ Muhammad Akbar Baig,² Emaduddin Siddiqui,³ Danyal Jamil,⁴ Masharib Bashir,⁵ Asher Feroze⁶

Abstract

Optic nerve sheath diameter measurement (ONSD) has been associated with identifying the prognosis of traumatic brain injury (TBI) patients. The study was planned to evaluate the prognostic value of ONSD measured on the initial brain computed tomography (CT) scan performed on patients with blunt TBI in the emergency department (ED). This retrospective cross-sectional study was conducted at the Aga Khan University Hospital, Karachi, and comprised data of moderate and severe TBI patients from January to December 2014. ONSD for each eye on the initial CT scan and Glasgow Coma Scale (GCS) was measured upon patient presentation. Correlation between presentation GCS and ONSD was done through Pearson's correlation. Receiver operator curve (ROC) analysis was done to measure the predictive values of ONSD for mortality. Of the 276 patients, 211 (76%) were males and 65 (23%) females. ONSD was measured on 160 (58%) patients. The mean ONSD measured on CT scan was 3.8 ± 1 . The Pearson's correlation between the severity of brain injury as per GCS at presentation and ONSD was not significant (-0.182). We concluded that ONSD measured on the initial CT brain scan had good association with the severity of blunt TBI in patients presenting to the ED.

Keywords: Traumatic brain injury, Head injury, Optic nerve sheath diameter, Computed tomography.

Introduction

Traumatic brain injury (TBI) is considered as a leading cause of morbidity, mortality and economic loss around the world. The World Health Organisation (WHO) has estimated the incidence of more than 600 per 100,000 people.¹ The incidence is on the rise in Pakistan with annual incidence equal to 50 per 100,000.² Disability following a TBI is a major concern and it is important to provide optimistic care to TBI patients.³ There are numerous factors that influence

the prognosis of TBI patients, including gender, age, severity of injury, anticoagulant use, comorbidities, arrival Glasgow Coma Scale (GCS), and the region of affected brain on computed tomography (CT) scan. The International Mission for Prognosis and Analysis of Clinical Trials (IMPACT) and the Corticosteroid Randomisation After Significant Head injury (CRASH) prognostic scores are not meant for the emergency department (ED) estimation for TBI severity.⁴ Optic nerve is the most easily accessible part of the brain meninges and there are studies demonstrating the effectiveness of the optic nerve sheath diameter (ONSD) on CT scans with the intracranial pressure (ICP) and the severity of the brain injury.⁵ Literature review has shown no such study having been conducted in an ED of Pakistan. The current study was planned to highlight the significance of the ONSD on the presentation brain CT scan in the ED and to correlate with the mortality.

Methods and Results

This retrospective, cross-sectional study was conducted at the Department of Emergency Medicine, Aga Khan University Hospital, Karachi, and comprised records of patients with TBI from January 1 to December 31, 2014. The ethics review committee approved the study protocol. As the study was non-interventional, informed consent from the participants was not required. The subjects were enrolled using purposive convenient sampling.

Patients presenting to the ED with ages 16 years and above and having moderate to severe TBI were included.

We excluded patients having facial trauma affecting the eye balls, pre-existing orbital disease affecting the orbital nerve, exophthalmia, hyperthyroidism, incomplete medical records, unavailable CT brain scans or absent millimetre-scale sequences.

On arrival of the patients to the ED, Advanced Trauma Life Support (ATLS) management principles were applied and the patients were divided into three groups on the basis of GCS to mild, moderate and severe. The patients who had moderate to severe TBI were enrolled. Medical

¹⁻³Department of Emergency Medicine, Aga Khan University Hospital, ^{4,5}Dow University of Health Sciences, ⁶Aman Foundation, Karachi.

Correspondence: Muhammad Akbar Baig. Email: dr_akbar2007@hotmail.com

Table: The emergency department presentation clinical characteristics between those with moderate to severe traumatic brain injury and those who died.

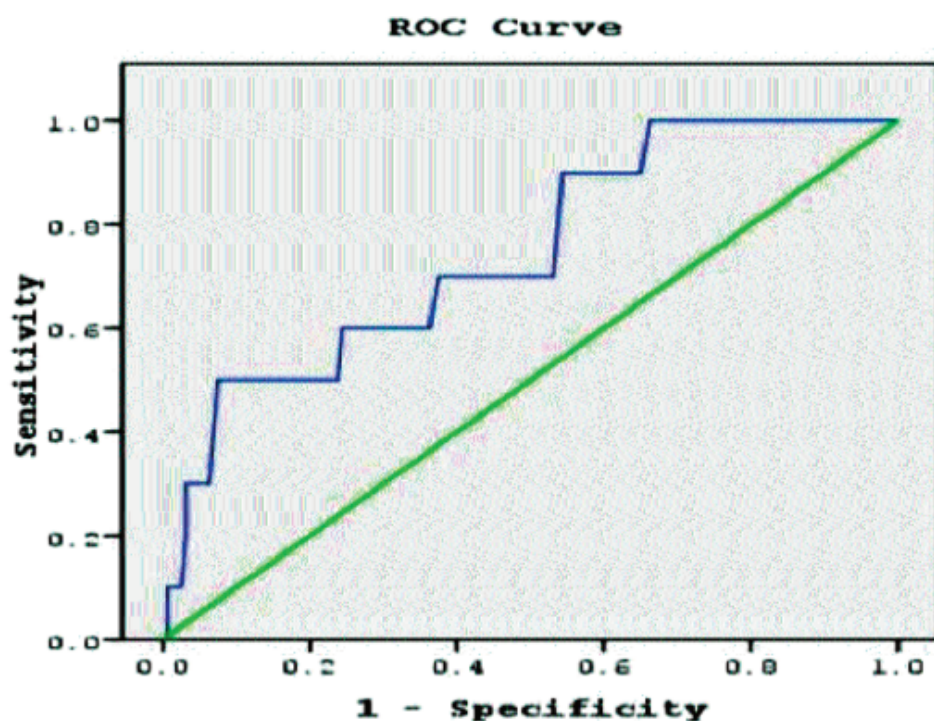
Variables	Moderate to Severe Traumatic Brain Injury (Mean \pm SD)	Death (Mean \pm SD)	P-Value
Age (months)	55.6 (57)	77.9 (62)	0.150
ISS	30(13)	38 (32)	0.41
GCS (at presentation)	12 (3.6)	6.5 (3.6)	<0.001
Pupil size	3 (1)	4 (3)	<0.01
MAP (mmHg)	90 (19)	◆ 89 (35)	◆ 0.8
◆ Heart Rate	◆ 113 (27)	◆ 116 (37)	◆ 0.630
◆ Length of stay (days)	◆ 20 \pm 15	◆ 6 \pm 4	◆ 0.002

SD: Standard deviation.

ISS: injury severity score.

GCS: Glasgow Coma Scale.

MAP: Mean arterial pressure.

**Figure:** Receiver-operator characteristic (ROC) curves of the performance of optical nerve sheath diameter to predict mortality.

records of patients were reviewed according to a pretested pro forma. All CT images were analysed utilising the hospital system of image archives. Information regarding surgical intervention and intensive care unit (ICU)/high dependency unit (HDU) stay were obtained from review of operating room (OR) and post-operative records.

The physician who filled up the questionnaire measured the ONSD. The history paper was removed blinding the physician to the circumstances of TBI at the time of ONSD measurement. Only the initial presentation CT scans of patients with moderate to severe TBI were reviewed by

the physician and counter-checked by the radiologist. The ONSD was recorded as per previous published literature which is 3mm behind the eyeball, immediately below the sclera. The diameter was measured from one side of the optic nerve sheath to the other. The diameter of both eyes' optic nerve sheaths was averaged. The inter-observer variability was 6% \pm 5% (Cronbach's alpha coefficient = 0.893) and the intra-observer variability was 2% \pm 2% (Cronbach's alpha coefficient = 0.996).

Data was analysed using SPSS 19. Descriptive analysis was performed to calculate percentages and proportions. T test and analysis of variance (ANOVA) were used to compare means of two or more groups, respectively. Chi-square test

was used to compare qualitative data for level of significance.

Of the 276 patients, 19(6.9%) died; of them, CT brain scans on 10(52.6%) patients were not done because they had presented dead. Of these patients, 5(50%) had facial fractures, 3(30%) had possible globe rupture and 2(20%) had open head injury. Of all the participants, 211(76%) were males and 65(23%) females.

ONSD was measured on 160(58%) patients. The remaining 116(42%) patients' optic nerve sheath was either of only one eye, the medical record were

incomplete or the measurement was not calibrated. The overall mean age of patients was 55 ± 2 years. The time interval between trauma and the first brain CT scan was < 4 hours. The mean injury severity score (ISS) was 32 ± 16 . The initial GCS score was 12 ± 3 . Moreover, 80(29%) patients underwent neurosurgical intervention on hospital admission. The most common injury mechanism was road traffic accident in which the patient was the pedestrian 110(40%). The CT brain scan revealed traumatic subarachnoid haemorrhage in 80(29%) patients, followed by subdural haematoma in 70(25%), epidural haematoma in 30(13%), intracranial bleeding in 40(14%) and skull fracture in 50(18%), with a mean Marshall score of 4 ± 2.2 . Invasive ICP monitoring was not initiated during the ED stay of the aforementioned patients (Table).

There was a strong relationship between ONSD measured in patients who were alive 3.7 ± 1 compared to those who died 4.7 ± 1.1 ($p < 0.01$). We also found a significant positive correlation between the ONSD and Marshall score ($p = 0.001$). In case of pupil size, patients who were alive had a pupil size of 3 ± 1 mm compared to dead 4.5 ± 4 mm ($p < 0.01$). We cannot find any relationship between the CT findings of the elevated ICP with the ONSD.

A receiver operator characteristic (ROC) curve was plotted to assess the prognostic value of ONSD (Figure). The area under the curve was 0.746 with a 95% confidence interval of 0.593 to 0.898. A cut-off > 7 mm had a sensitivity of 85% and a specificity of 74%, a positive predictive value of 58%, a negative predictive value of 92%, a positive likelihood ratio of 3.2 and a negative likelihood ratio of 0.3. A statistically significant association was observed between mortality and ED presentation ONSD measurement ($p < 0.01$).

Discussion

Our study demonstrates a strong relationship of the ONSD measurement with the severity of TBI in patients presenting to ED. A clear relationship exists between ONSD measurement and raised intracranial hypertension as reported by an experimental study conducted in cadaveric models.⁶ This has led many researchers to investigate the significance and applicability of ONSD measurement as a means of detecting increased intracranial hypertension in patients with TBI, thereby allowing rapid assessment in the ED.⁷

Various modalities have been utilised for ONSD measurement. It has been more frequently measured

with ultrasound in TBI patients with raised ICP.⁸ Magnetic resonance imaging (MRI) has also been proposed to measure ONSD,⁹ however, the limited accuracy and thicker brain slices may underestimate the ONSD value.¹⁰ The ONSD values measured by CT and MRI are higher than those reported with ultrasonography; however, a much better correlation exists between ONSD measurement on CT scan with ultrasonography in healthy subjects.¹¹ In the emergency department, an US evaluation of ONSD ≥ 5.0 mm was associated with CT findings of elevated ICP.¹²

There is a well-documented relationship between intracranial hypertension and patient prognosis.¹³

Conclusion

The initial measurement of ONSD may be clinically useful in the earlier diagnosis and aggressive treatment of raised ICP. ONSD measurement is much easier to determine on CT than with ultrasonography due to good reproducibility and lack for need of detailed training.

Limitations

The current study had a few limitations as well. It was a cross-sectional single-centre study and needs to be validated on a larger patient cohort in a multicentre setting. Few of our patients had invasive ICP monitoring that can be done for better correlation of ONSD measurement and clinical outcome.

Disclaimer: None.

Conflict of Interest: None.

Source of Funding: None.

References

1. Coronado VG, Xu L, Basavaraju SV, McGuire LC, Wald MM, Faul MD, et al. Surveillance for traumatic brain injury-related deaths: United States, 1997-2007: US Department of Health and Human Services, Centers for Disease Control and Prevention Atlanta; 2011.
2. Umerani MS, Abbas A, Sharif S. Traumatic brain injuries: experience from a tertiary care centre in Pakistan. *Turk Neurosurg* 2013; 24: 19-24.
3. Rudehill A, Bellander BM, Weitzberg E, Bredbacka S, Backheden M, Gordon E. Outcome of traumatic brain injuries in 1,508 patients: impact of prehospital care. *J Neurotrauma* 2002; 19: 855-68.
4. Steyerberg EW, Mushkudiani N, Perel P, Butcher I, Lu J, McHugh GS, et al. Predicting outcome after traumatic brain injury: development and international validation of prognostic scores based on admission characteristics. *PLoS Med* 2008; 5: e165.
5. Geeraerts T, Launey Y, Martin L, Pottecher J, Vigué B, Duranteau J, et al. Ultrasonography of the optic nerve sheath may be useful for detecting raised intracranial pressure after severe brain injury. *Intensive Care Med* 2007; 33: 1704-11.
6. Hansen HC, Lagrèze W, Krueger O, Helmke K. Dependence of

- the optic nerve sheath diameter on acutely applied subarachnoidal pressure-an experimental ultrasound study. *Acta Ophthalmol* 2011; 89: e528-32.
7. Blaivas M, Theodoro D, Sierzenski PR. Elevated intracranial pressure detected by bedside emergency ultrasonography of the optic nerve sheath. *Acad Emerg Med* 2003; 10: 376-81.
 8. Cammarata G, Ristagno G, Cammarata A, Mannanici G, Denaro C, Gullo A. Ocular ultrasound to detect intracranial hypertension in trauma patients. *J Trauma* 2011; 71: 779-81.
 9. Geeraerts T, Newcombe VF, Coles JP, Abate MG, Perkes IE, Hutchinson PJ, et al. Use of T2-weighted magnetic resonance imaging of the optic nerve sheath to detect raised intracranial pressure. *Crit Care* 2008; 12: R114.
 10. Watanabe Y, Lee CK, Gerbi BJ. Geometrical accuracy of a 3-tesla magnetic resonance imaging unit in Gamma Knife surgery. *J Neurosurg.* 2006;105 Suppl:190-3.
 11. Boles Carenini B, Tettoni E, Brogliatti B. CT and a echography of optic nerve in glaucoma. *Acta Ophthalmol Scand Suppl* 2002; 80: 40-1.
 12. Tayal VS, Neulander M, Norton HJ, Foster T, Saunders T, Blaivas M. Emergency department sonographic measurement of optic nerve sheath diameter to detect findings of increased intracranial pressure in adult head injury patients. *Ann Emerg Med* 2007; 49: 508-14.
 13. Utomo WK, Gabbe BJ, Simpson PM, Cameron PA. Predictors of in-hospital mortality and 6-month functional outcomes in older adults after moderate to severe traumatic brain injury. *Injury* 2009; 40: 973-7.
-