

## A case of Vogt Koyanagi Harada disease in a 16 year old girl

Fahimullah Khan,<sup>1</sup> Salman Zahid,<sup>2</sup> Syed Shahmeer Raza,<sup>3</sup> Mustafa Iqbal<sup>4</sup>

### Abstract

Vogt Koyanagi Harada (VKH) is an autoimmune disease with widespread systemic manifestations. It typically presents with bilateral sudden painless loss of vision. It is mainly characterized by serous retinal detachment, iridocyclitis and choroidal swelling. The disease is more common in females and maximum incidence occurs in the age group of 30 to 40 years. We present a case of a 16-year-old girl who presented with sudden bilateral painless loss of vision. Fundus examination and OCT scanning confirmed bilateral serous retinal detachment. Patient was started on IV methylprednisolone and the patient showed excellent response with marked improvement in visual acuity. VKH is very uncommon in children and is usually missed. It is important for general practitioners and ophthalmologists to know about this rare cause of painless loss of vision so that it could be managed adequately.

**Keywords:** VKH, Painless loss of vision, OCT & Steroids.

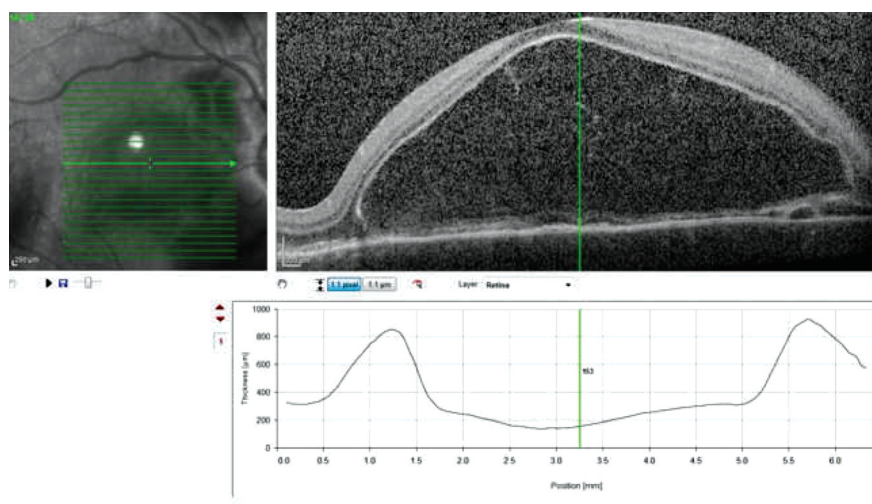
### Introduction

Vogt Koyanagi Harada (VKH) disease is an autoimmune, multisystemic disorder. It is characterized by serous retinal detachment, iridocyclitis and choroidal swelling. Neurological and cutaneous manifestations are also seen occasionally.<sup>1</sup> VKH typically progressed through four stages which include a prodromal, acute uveitis, convalescent and chronic/recurrent uveitis.<sup>2,3</sup> VKH disease is not very common, but is seen in Asian (more commonly from eastern and southeastern Asia), Middle Eastern, Hispanic, and Native American populations. The disease is not often seen in whites.<sup>4,5</sup> VKH is most commonly seen in females with a male to female ratio of 2:1. The age of onset of VKH

has been reported to be in the age range of 3-89 years, but the maximum incidence is in the 30s. VKH is usually missed in children.<sup>6</sup> We present the case of a young girl with sudden loss of vision diagnosed as VKH.

### Case Report

A 16 year old girl presented with bilateral sudden loss of vision. Rest of the history was unremarkable except for an occasional headache. On examination, the visual acuity of the right eye was counting finger at ½ meter, and in the left eye was counting finger close to the eye with no improvement with pin hole. Pupillary response was



**Figure-1:** Right eye before treatment.

sluggish, and IOP was 10mm Hg in both eyes. The lids and orbit on exam were normal. The conjunctiva was injected bilaterally, both corneas were clear, anterior chamber of both the eyes showed flare and white cells. Vitreous cells were seen bilaterally. On fundus examination, there was bilateral optic disc swelling and elevated nerve fiber layer. Fundus examination confirmed bilateral serous retinal detachment. Optic Coherence Tomography scanning showed serous retinal detachment (Figure-1 & 2). Systemic investigations included a Full blood count (FBC), Erythrocyte Sedimentation Rate (ESR), C-Reaction Protein (CRP), Liver Function Tests (LFTs), Renal Function Tests (RFTs), Mantoux Test, Angiotensin converting enzyme

<sup>1</sup>Eye Department, <sup>4</sup>Department of Ophthalmology, Medical Teaching Institution, Khyber Teaching Hospital, <sup>2,3</sup>Final Year Medical Student, Khyber Medical College, Peshawar, Pakistan.

**Correspondence:** Fahimullah Khan. Email: Fahim\_wazir1@yahoo.com

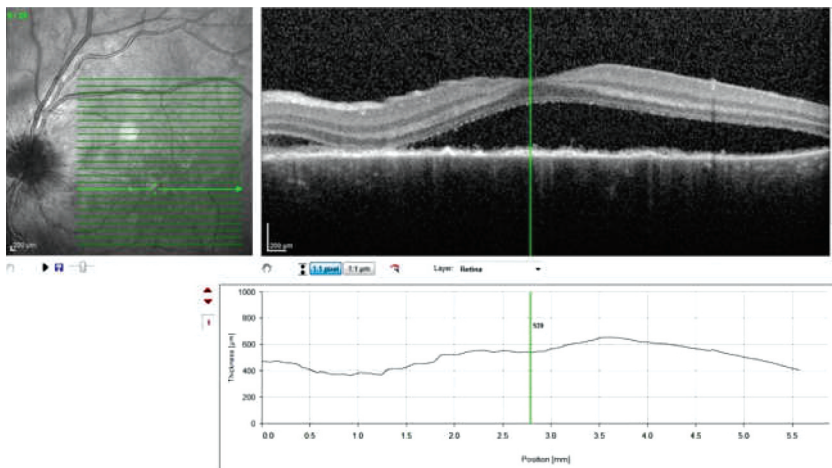


Figure-2: Left eye before treatment.

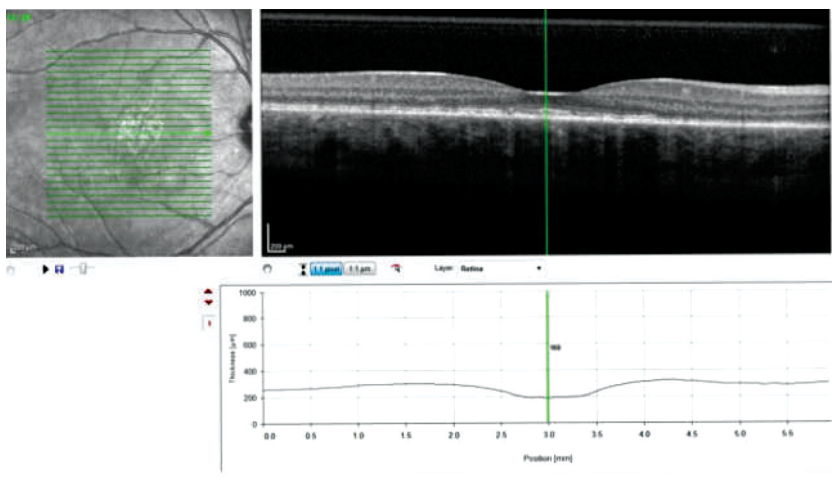


Figure-3: Right eye after treatment.

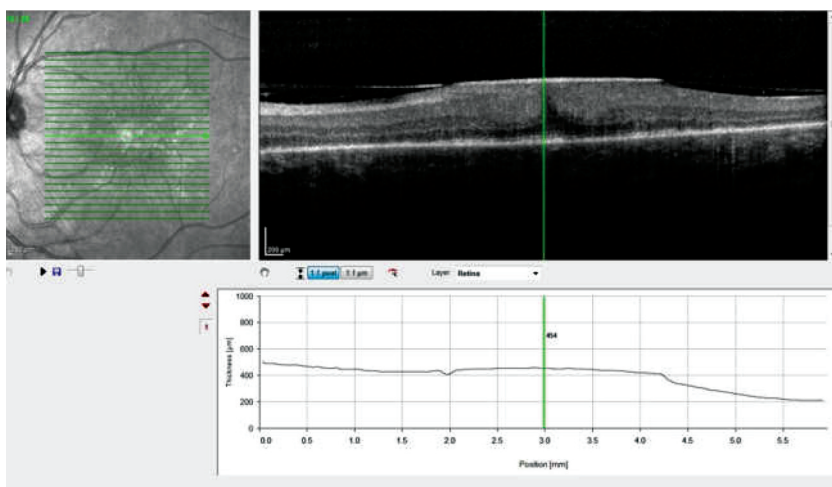


Figure-4: Left eye after treatment.

(ACE) level, Toxoplasma test, Anti Nuclear Antibodies (ANA), Rheumatoid Factor (RF), and Venereal Disease Research Laboratory test (VDRL). All of the systemic investigations were normal and unremarkable. Radiological investigations included a chest X-ray which was normal. Injection methylprednisolone 1gm I/V In 100 ml Dextrose saline was started for 3 days and was later converted to oral steroids. After 5 days on steroid therapy, visual acuity in the right eye improved to counting finger 5 meter and 6/12 with pin hole, in the left eye visual acuity was 6/24 and 6/12 with pin hole. The patient was discharged and sent home on oral steroids. Follow up visit after one month, showed significant improvement in visual acuity. Visual acuity in right eye was 6/6 and left eye was 6/9, serous retinal detachment had resolved on OCT scanning and fundus examination (Figure-3 & 4). The case was seen on 21st March 2016 and consent was taken prior to writing of the manuscript.

## Discussion

VKH has a wide spectrum of manifestations and a typical presentation is not common. There are three categories of VKH Complete, incomplete and probable VKH, however common to all VKH are the following requirements: Patient has bilateral ocular involvement, no history of ocular trauma or surgery and there should be no clinical or laboratory evidence of any other ocular disease.<sup>7,8</sup> In our case the criteria for diagnosing the case as VKH was met. It is very important not to misdiagnose VKH, as the results could be disastrous. Infectious Uveitis, tuberculosis or syphilis misdiagnosed as VKH and treated with steroids can deteriorate the patient's condition. Hence it is very important to exclude uveitis, ocular lymphoma, sympathetic ophthalmia etc. before coming to the diagnosis of VKH.<sup>9</sup> Our patient did not develop any dermatologic manifestation of the disease. These findings are consistent with the previous data which shows that patients with VKH disease, who are diagnosed early and

treated appropriately never develop any dermatologic manifestation of the disorder.<sup>10</sup> Our patient showed excellent response to steroid treatment, studies done on the same topics have shown that systemic steroids control active inflammation, prevent recurrence and minimize the incidence of dermatological and neurological manifestation of the disease.<sup>11</sup> In our case, the patient presented with bilateral loss of vision, however cases of VKH with unilateral loss of vision have also been reported. VKH should be considered in cases of unilateral sudden painless loss of vision.

## Conclusion

VKH is a rare but important cause of bilateral painless loss of vision, although rare in children and in people with age less than 20 years, general practitioners and ophthalmologists should be aware of this rare disease so that adequate referral and treatment could be done immediately.

**Disclaimer:** None to declare.

**Conflict of Interest:** Prof. Mustafa Iqbal has signed the ethical review statement for this manuscript and is also the co-author of this manuscript.

**Funding Disclosure:** None to declare.

## Reference

1. Neves A, Cardoso A, Almeida M, Campos J, Campos A, Castro Sousa JP. Castro Sousa Unilateral Vogt-Koyanagi-Harada Disease: Case Rep Ophthalmol. 2015; 6: 361-5.
2. Sakata VM, da Silva FT, Hirata CE, de Carvalho JF, Yamamoto JH. Diagnosis and classification of Vogt-Koyanagi-Harada disease. Autoimmun Rev. 2014; 13: 550-5.
3. American Academy of Ophthalmology - The Eye MD Association (2014) Vogt-Koyanagi-Harada syndrome; in Basic and Clinical Science Course, Section 9: Intraocular Inflammation and Uveitis, chapter 6: Noninfectious (Autoimmune) Ocular Inflammatory Disease. San Francisco: AAO, 2014; pp. 183-90.
4. Chee SP, Jap A, Bacsal K. Prognostic factors of Vogt-Koyanagi-Harada disease in Singapore. Am J Ophthalmol. 2009; 147: 154-61.e1.
5. Ostergaard J, Goldschmidt E, Andersen N. Vogt-Koyanagi-Harada syndrome in a Greenlandic Inuit. Acta Ophthalmol. 2008; 86: 576-8.
6. Berker N, Ozdamar Y, Soykan E, Ozdal P, Ozkan SS. Vogt-Koyanagi-Harada syndrome in children: report of a case and review of the literature. Ocul Immunol Inflamm. 2007; 15: 351-7.
7. Read RW, Holland GN, Rao NA, Tabbara KF, Ohno S, Arellanes-Garcia L, et al. Revised diagnostic criteria for Vogt-Koyanagi-Harada disease: report of an international committee on nomenclature. Am J Ophthalmol. 2001; 131: 647-52.
8. Nordlund JJ, Albert D, Forget B, Lerner AB. Halo nevi and the Vogt-Koyanagi-Harada syndrome. Manifestations of vitiligo. Arch Dermatol. 1980; 116: 690-2.
9. Pakh PJ, Todd DJ, Blaha GR, Soukiasian SH, Landmann DS, Craven DE, et al. Intravascular lymphoma masquerading as Vogt-Koyanagi-Harada syndrome Ocul Immunol Inflamm. 2008; 16: 123-6.
10. Cunningham ET Jr, Rathinam SR, Tugal Tutkun I, Muccioli C, Zierhut M. Vogt Koyanagi Harada disease Ocul Immunol Inflamm. 2014; 22: 249-52.
11. Forster DJ, Green RL, Rao NA. Unilateral manifestation of Vogt Koyanagi Harada syndrome in a 7 year old child. Am J Ophthalmol. 1991; 111: 380-2.