

## Role of posterior sub-tenon triamcinolone acetonide in patients of refractory macular oedema

Rana Fahad Ibraheem, Waseem Iqbal, Fawad-ur-Rehman

### Abstract

**Objective:** To evaluate the results of posterior sub-tenon triamcinolone acetonide in patients of refractory macular oedema suffering with retinal vascular disorders.

**Methods:** This quasi-experimental study was conducted at Layton Rahmatulla Benevolent Trust, Lahore, Pakistan, from October 2014 to March 2015, and comprised eyes of patients with refractory macular oedema. The central macular thickness of all patients was determined with ocular coherence tomography before giving injection of 40mg/ml posterior sub-tenon triamcinolone acetonide. After the injection, central macular thickness of each eye was measured in follow-ups at 1st week, 1st month and 2nd month with ocular coherence tomography.

**Results:** Of the 40 participants, 26(65%) were men and 14(35%) women. The mean age was  $61.80 \pm 7.20$  years. The mean central macular thickness before injection was  $488.70 \pm 34.93$ , while it was  $337.60 \pm 146$  after 1st week of injection,  $420.60 \pm 76.13$  after 1st month and  $477.98 \pm 72.30$  after two months. Comparisons of central macular thickness at various follow-ups showed a significant difference from the baseline to the last follow-up ( $p < 0.001$ ). Moreover, 4(14%) subjects showed consistent improvement in central macular thickness.

**Conclusion:** Posterior sub-tenon triamcinolone acetonide can be considered a short-term treatment option in cases of refractory macular oedema.

**Keywords:** Posterior sub-tenon (PST), Triamcinolone acetonide(TA), Central macular thickness(CMT), Ocular coherence tomography(OCT). (JPMA 66: 1602; 2016)

### Introduction

Macular oedema is the main cause of decreased visual acuity in patients suffering with retinal vascular disorders like diabetic retinopathy, hypertensive retinopathy, retinal vein occlusion and uveitis, both intermediate and posterior uveitis.<sup>1,2</sup> Several mechanisms have been proposed to explain how macular oedema develops. However, a breakdown in the inner blood-retinal barrier (BRB) that allows for fluid to accumulate in cystoid spaces within the retina is considered to be the cause of developing macular oedema in patients suffering with retinal vascular disorders.<sup>3</sup> Treatment options available for such cases include intra-vitreous anti-vascular endothelial growth factors(anti-VEGFs) like bevacizumab or argon laser, such as focal or grid.<sup>4</sup> Most of these patients respond well to one or both of these treatment options, but in some patients macular oedema failed to respond to these treatments where it is labelled as refractory macular oedema.

Posterior sub-tenon (PST) triamcinolone acetonide (TA) has been shown to be highly effective for the treatment of macular oedema, refractory to traditional laser

photocoagulation and intra-vitreous anti-VEGFs in patients suffering with Retinal Vascular Disorders.<sup>5</sup>

Triamcinolone acetonide (TA) is a synthetic corticosteroid that helps in treating macular oedema by inhibiting the prostaglandin synthesis and down-regulating the production of VEGF.<sup>6</sup> Thus stabilisation of BRB introduces a rationale for corticosteroid treatment of macular oedema.<sup>7</sup>

Triamcinolone acetonide (TA) can be given through intra vitreous route and in posterior sub-tenon space. Despite prompt response from treatment with intravitreal steroid injections, this modality was associated with many severe vision-threatening ocular complications such as endophthalmitis and glaucoma.<sup>8</sup> TA delivered via the posterior sub-tenon route is equally effective in treating macular oedema because of localisation of drug at the macula.<sup>9</sup>

The main advantage of posterior sub-tenon steroid injection is a prolonged effect due to a maximal local concentration of the drug that causes minimal systemic side effects.<sup>10</sup> A clinical trial was done in Iran to assess the effects of sub-tenon injection of methylprednisolone acetate, another synthetic corticosteroid in the management of persistent and refractory clinically significant diabetic macular oedema. It was found that

.....  
Vitreoretina, LRBT Eye Hospital, Lahore, Pakistan.

**Correspondence:** Rana Fahad Ibraheem. Email: dr.ranafahadscorpio@gmail.com

posterior sub-tenon methylprednisolone acetate was helpful in improving early visual outcome in diffuse diabetic macular oedema that fails to respond to conventional laser photocoagulation and intra-vitreous anti-VEGFs.<sup>11</sup>

The current study was planned to assess the effects of sub-tenon injection of TA in the management of refractory macular oedema in patients suffering with retinal vascular disorders like diabetic retinopathy, hypertensive retinopathy and retinal vein occlusion.

## Patients and Methods

This quasi-experimental study was conducted at Layton Rahmatulla Benevolent Trust (LRBT), Lahore, Pakistan, from October 2014 to March 2015, and comprised eyes of patients with refractory macular oedema. Approval was obtained from the institutional ethics committee and informed written consent was obtained from the patients. Eyes with refractory macular oedema of different patients were selected after ruling out their steroid responsiveness and complete clinical evaluation and assessment from available medical records. Patients with persistent macular oedema suffering with retinal vascular disorders like diabetic retinopathy, hypertensive retinopathy and retinal vein occlusion, three months after at least 1 session of macular laser photocoagulation or 2 injections of intra-vitreous anti-VEGFs, like bevacizumab, were included. Eyes with history of glaucoma, cataract extraction or other intraocular surgery were excluded. Eyes with macular oedema because of macular epiretinal membrane, posterior hyaloids traction or ischaemic maculopathy were also excluded. The risks and benefits of the procedure were discussed with each patient before injection.

Baseline parameters were documented in a pre-designed proforma including best corrected visual acuity, central macular thickness (CMT), intraocular pressure (IOP) before giving an injection of PST TA (40mg/ml). CMT was measured by optical coherence tomography and intraocular pressure was measured by applanation tonometer. Systemic condition of the patients was under control (blood glucose, blood pressure and general

condition).

After taking aseptic measures, all patients underwent PST injection of TA 40mg/ml. First topical proparacaine hydrochloride was applied to the ocular surface and then a cotton-tipped applicator soaked in lidocaine was placed over the superotemporal quadrant for 2 minutes as the patient looked inferonasally. The PST TA suspension was then shaken and 1cc (40 mg) was drawn into a tuberculin syringe using a 25-gauge, 0.5-inch needle. The upper eyelid was lifted and as the patient looked inferonasally, the needle was used to penetrate the PST space. Before injection of TA, the needle was moved from side to side to check that the sclera was not engaged in the needle tip. A 40mg injection of TA was then injected in the PST space.

After giving PST TA (40mg/ml), CMT of each eye and IOP was measured in follow-ups at 1st week, 1st month and 2nd month after PST TA with optical coherence tomography (OCT) and applanation tonometry, respectively.

SPSS 20 was used for data analysis. Quantitative data like age, CMT (microns) at different follow-ups was presented in the form of mean  $\pm$  standard deviation (SD) while categorical data like gender and improvement in CMT was presented in the form of frequency (%). Normality of data was checked using one-sample Kolmogorov-Smirnov test. As data was not normal ( $p$ -value  $>$  0.05), we applied Friedman test (between all follow-ups), and Wilcoxon signed-rank test to compare CMT in pair-wise follow-ups (pre-injection CMT vs. 1st week CMT, pre-injection CMT vs. 1st month CMT, pre-injection CMT vs. 2nd month CMT, 1st week CMT vs. 1st month CMT, 1st month CMT vs. 2nd month CMT).  $P \leq 0.05$  was considered significant.

## Results

Of the 40 participants, 26(65%) were men and 14(35%) women. The overall mean age was  $61.8 \pm 7.2$  years. The mean CMT was  $488.70 \pm 34.93$  before injection,  $337.60 \pm 146$  at 1st week of injection,  $420.60 \pm 76.13$  at 1st month and  $477.98 \pm 72.30$  after 2 months of injection (Table-1).

**Table-1:** Descriptive statistics of age and CMT (microns) at various follow ups.

|         | Age (years)      | Pre Inj CMT (M)    | CMT 1st week        | CMT 1st month      | CMT 2nd month      |
|---------|------------------|--------------------|---------------------|--------------------|--------------------|
| Mean    | 61.80 $\pm$ 7.20 | 488.70 $\pm$ 34.93 | 337.60 $\pm$ 146.00 | 420.60 $\pm$ 76.13 | 477.98 $\pm$ 72.30 |
| Range   | 27.00            | 130.00             | 372.00              | 354.00             | 366.00             |
| Minimum | 48.00            | 420.00             | 188.00              | 196.00             | 194.00             |
| Maximum | 75.00            | 550.00             | 560.00              | 550.00             | 560.00             |

Pre Inj: Pre-Injection

CMT: Central macular thickness.

**Table-2:** Comparison of CMT (microns) at various follow-ups.

|  | p-value |
|--|---------|
| Pre Inj CMT vs. 1st week CMT #             | <0.011  |
| Pre Inj CMT vs. 1st month CMT #            | <0.011  |
| Pre Inj CMT vs. 2nd month CMT #            | 0.51    |
| CMT 1st week vs. 1st month CMT #           | 0.002   |
| CMT 1st month vs. CMT 2nd month CMT #      | <0.011  |
| Overall comparison [Within all follow ups] | <0.011  |

Pre Inj: Pre-Injection.

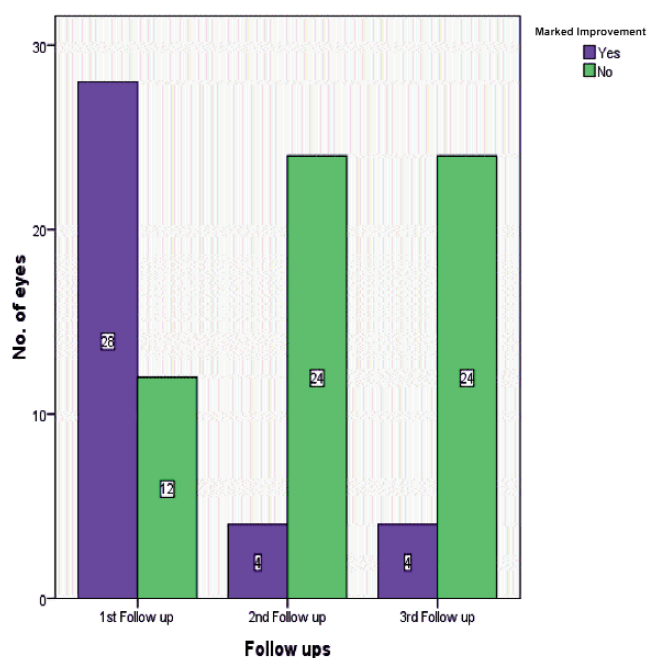
CMT: Central macular thickness.

#p-values were calculated using Wilcoxon signed-ran

§ Fried man test was applied.

Comparisons of CMT at various follow-ups showed significant difference for pre-injection vs. 1st week, pre-injection vs. 1st month, and 1st month vs. 2nd month follow-ups ( $p < 0.011$ ). However, the difference was insignificant ( $p = 0.51$ ) for pre-injection vs. 2nd month CMT, and significant ( $p = 0.002$ ) for 1st week vs. 2nd month follow-ups (Table-2).

Out of 40 patients, 28 (70%) showed marked improvement and 12 (30%) eyes showed no improvement in CMT at first follow up (after 1st week of injection). Out of 28 eyes which showed improvement, CMT of 24 (85.7%) eyes increased to previous or higher level at 2nd (at 1st month) and 3rd follow up (after 2 months of injection). However only 4(14%) eyes out of 28 eyes showed consistent improvement (Figure).

**Figure:** Comparison of Improvement after injection at different follow-ups.

## Discussion

Macular oedema is the most frequent cause of visual impairment in patients suffering with diabetic retinopathy and retinal vascular occlusive disorders.

Most of these patients got relieved after receiving treatment but in some patients macular oedema failed to respond to these treatment options where it is labelled as refractory macular oedema.

Corticosteroids have been used to inhibit the prostaglandin synthesis and down-regulate production of VEGF leading to stabilisation of BRB.

Several studies showed the efficacy of intravitreal injection of corticosteroids in the management of diabetic macular oedema.<sup>12,13</sup> Intravitreal injection is associated with rapid drug delivery to action site with maximal bioavailability, but has its complications. Trans-tenon's retrobulbar infusion and sub-tenon's injection of corticosteroids have been shown to be effective in the treatment of cystoid macular oedema in patients with uveitis.<sup>14,15</sup>

Sub-tenon injection of steroids in the treatment of uveitis was first reported in 1998 by Tanner et al.<sup>16</sup> It is a standard drug delivery method (with maximum concentration of drug in macula), which is used for treatment of chronic uveitis of posterior segment.

In retrospective, interventional case series, Chieh et al.<sup>17</sup> treated 210 eyes with 1 or 4 mg of intravitreal triamcinolone acetonide for treatment of diffuse diabetic macular oedema. They found a mean improvement in visual acuity from a median of 20/200 (mean logarithm of the minimum angle of resolution [logMAR], 0.92) at baseline to 20/80 (mean logMAR, 0.82) at 6 months. Mean intraocular pressure  $\pm$  SD increased from  $15.4 \pm 3.4$  mmHg to a maximum of  $20.4 \pm 6.2$  mmHg during the follow-up period.

The present study was conducted to assess the effect of PST TA in patients of refractory macular oedema suffering with retinal vascular disorders. About 70 percent of these patients showed marked improvement in CMT during their follow-up at 1st week but the rest of 30 per cent patients remained refractory to the PST TA and showed no improvement in their CMT. But among those patients who showed great improvement in their first follow-up, about 85 percent came back to their previous level in follow-ups at 1st and 2nd month. This showed that effect of PST TA in patients of refractory macular oedema is transient and lasted until its peak concentration in the vitreous cavity.

A study conducted on intraocular and systemic

pharmacokinetics of TA after a single 40mg PST application found that the TA concentration time profile in vitreous consisted of an absorption phase during the first 24 hours followed by a slow elimination phase.

Its terminal elimination half-life - the time it takes to lower the amount of TA in vitreous after a single 40-mg in PST space to its half (divide it by two) - is 17.1 days.<sup>18</sup> Thus this explains that PST TA remained effective as far as it remained in the vitreous cavity, that is for 1 month, but after its elimination from vitreous completed, that is roughly within 34 days, CMT of patients with refractory macular oedema deteriorated back to previous levels in majority of cases.

In cases where chronic macular oedema is because of retinal vascular disorders in which patients' systemic disease like diabetes and hypertension may also affect the final outcome of chosen treatment modality, PST TA is somehow not found out to be an attractive option as compared to refractory macular oedema because of localised ocular pathology like uveitis where augmentation of immune response with the help of steroids can produce long-lasting effects.

## Conclusion

PST TA can be considered as a short-term treatment option in cases of refractory macular oedema associated with low potential complications related to intravitreal injections where traditional laser photocoagulation and intra-vitreous anti-VEGFs fail to work. However, its therapeutic effect was maximally achieved in the first month, but it did not have any significant role in permanent long-term treatment for cases of refractory macular oedema associated with retinal vascular disorders.

**Disclaimer:** None.

**Conflict of Interest:** None.

**Source of Funding:** Equipment supported by Layton Rehmatulla Benevolent Trust and Cancer Hospital, Township, Lahore.

## References

1. Kanski JJ. In: Jack J Kanski, Ken Nischal, Andrew Pearson ed. Macular oedema a cause of visual impairment in diabetic retinopathy. Clinical Ophthalmology 7th ed. China: 2015; pp 537.
2. Kanski JJ. In: Jack J Kanski, Ken Nischal, Andrew Pearson. Macular oedema a cause of visual impairment in branch retinal vein occlusion. Clinical Ophthalmology 7th ed. China: 2015; 537.
3. Roth DB. Pathophysiology Of Macular Oedema. [Online] [Cited 2015 May 4]. Available from URL: <http://emedicine.medscape.com/article/1225735-overview#a5>.
4. Roth RB. Treatment Of Macular Oedema. [Online] [cited 2015 June 6]. Available from: URL: <http://emedicine.medscape.com/article/1225735-treatment>.
5. Kanski JJ, Nischal K, Pearson A. Periocular steroid in treatment of macular oedema with Branch Retinal Vein Occlusion. Clinical Ophthalmology 7th ed. China: 2015; 555.
6. Javadzadeh A. Mechanism of action of corticosteroid in treating cystoids macular oedema. BMC Ophthalmology. 2006; 6:15.
7. Alireza Javadzadeh. Mechanism of action of corticosteroid in treating cystoids macular oedema. BMC Ophthalmology. 2006; 6:15. (6 & 7 ARE SAME)
8. Jack J Kanski, Ken Nischal, Andrew Pearson. Particular steroid in the treatment of macular oedema with Branch Retinal Vein Occlusion. 7th ed. china: 2015; pp 555. SAME AS 5
9. Dafflon LM, Tran VT, Guex-Crosier Y, Herbort CP. Posterior sub-Tenon's steroid injections for the treatment of posterior ocular inflammation: Indications, efficacy and side effects. Graefes Arch ClinExpOphthalmol. 1999; 237:289-95.
10. Tolentino MJ, Prenner JL, Gendron EK, Maguire AM. Echographic localization of corticosteroid after retrobulbar injection. Br J Ophthalmol. 2001; 85:626-7.
11. Javadzadeh A. The effect of posterior subtenon methylprednisolone acetate in the refractory diabetic macular oedema. BMC Ophthalmology. 2006; 6:15.
12. Martidis A, Duker JS, Greenberg PB, Rogers AH, Puliafito CA, Reichel E, et al. Intravitreal triamcinolone for refractory diabetic macular edema. Ophthalmology. 2002; 109:920-7.
13. Jonas JB, Kreissig I, Sofker A, Degenring RF. Intravitreal injection of triamcinolone for diffuse macular oedema. Arch Ophthalmol. 2003; 121:57-61.
14. American Academy of Ophthalmology: Intraocular inflammation and uveitis. In: Basic and clinical science course. Liesegang TJ ed. San Francisco: American Academy of Ophthalmology; 2001,113-6.
15. Okada AA, Wakabayashi T, Morimura Y, Kavashara S, Kojima E, Asano Y, et al. Trans-tenon'sretrobulbar triamcinolone infusion for the treatment of uveitis. Br J Ophthalmol. 2003; 87:968-71.
16. Tanner V, Kanski JJ, Frith PA. Posterior sub-tenon's triamcinolone injections in the treatment of uveitis. Eye. 1998; 12:679-85.
17. Chieh JJ, Roth DB, Liu M, Belmont J, Nelson M, Regillo C, et al. Intravitreal triamcinolone acetate for diabetic macular oedema. Retina. 2005; 25:828-34.
18. Shen L, You Y, Sun S, Chen Y, Qu J. Intraocular and systemic pharmacokinetics of triamcinolone acetate after a single 40-mg posterior subtenon application. Ophthalmology. 2010; 11:2365-71.