

Fresh garlic amelioration of high-fat-diet induced fatty liver in albino rats

Aisha Qamar,¹ Asma Siddiqui,² Hemant Kumar³

Abstract

Objective: To observe the effect of fresh garlic on high-fat-diet-induced fatty liver changes.

Methods: The experimental study was conducted at the Jinnah Postgraduate Medical Centre, Karachi, from October to November 2008, and comprised adult albino rats weighing 200-240g each. The rats were divided into 5 groups according to dietary regimen for eight weeks each. Group A received control diet; Group B received high saturated fat diet; Group C received high unsaturated fat diet; Group D received high saturated fat diet with fresh garlic; and Group E received high unsaturated fat diet with garlic for 8 weeks. Liver tissue slides were stained with Oil red-O and haematoxylin and Periodic acid-Schiff-haematoxylin.

Results: The 50 rats in the study were divided into five groups of 10(20%) each. There was marked deposition of fat in hepatocyte along with marked decrease in glycogen content in liver of rats in Groups B and C, with Group B showing more marked changes. The changes in fat and glycogen content were reversed and ameliorated close to Group A in rats belonging to Groups D and E.

Conclusion: Fresh garlic minimised the high-fat-diet-induced fatty liver changes in rats.

Keywords: Fatty liver, SFD (saturated fat diet), UFD (unsaturated fat diet), Garlic, Glycogen. (JPMA 65: 1102; 2015)

Introduction

Dietary fat composition has been related to insulin resistance, an increased risk of developing type2 diabetes mellitus (T2DM) and impaired postprandial lipid metabolism.¹ Accumulation of fat results from an imbalance between input/output/oxidation of fatty acids, leading to altered energy metabolism.² It is generally believed that diets based on saturated fatty acids, such as butter and coconut fat, induce the typical high-fat-diet phenotype, whereas diets containing polyunsaturated fatty acids, such as fish oil and corn oil, exert beneficial effects on body composition, weight gain and insulin action.³

Non-alcoholic fatty liver disease (NAFLD) includes a spectrum of liver pathology, from fatty liver (steatosis), to non-alcoholic steatohepatitis (NASH) progressing to cirrhosis, liver failure and hepatocellular carcinoma in the absence of alcohol abuse and other causes.^{4,5} Fatty liver is a reversible condition characterised by massive accumulation of triglyceride (TG) in the liver cells, due to excessive dietary fat.⁶ It is not clear why only a subset of patients showing NAFL may progress to liver fibrosis. A "multi-hit" injury has been suggested. Altered metabolism of free fatty acids is considered the "first-hit", which leads to insulin resistance and fat accumulation in

the liver. Inflammatory response, oxidative stress (OS), apoptosis and even autophagy serve as "following hits" which lead to chronic inflammation.^{7,8}

Garlic, *Allium sativum*, is a member of the lily family that has been cultivated and consumed by humans for over 10,000 years. Ancient Egyptian records mentioned use of garlic as a remedy for a variety of diseases. Recently, it has been found that the sulfur-containing compounds of garlic have anti-mutagenic and anti-carcinogenic effects.⁹ Garlic has also been suggested to have hypolipidaemic, hypoglycaemic, anticoagulant, antihypertensive, antimicrobial, antifungal and hepatoprotective properties.^{10,11}

Administration of garlic has been shown to treat hyperlipidaemia in humans,¹² but the current study was planned was to evaluate the effects of high quantities of butter and corn oil on rat liver, and to observe the possible protective role of fresh, crushed garlic on fatty liver induced by high-fat diet.

Subjects and Methods

The experimental study was conducted at the Department of Anatomy, Basic Medical Sciences Institute (BMSI), Jinnah Postgraduate Medical Centre (JPMC), Karachi, for 8 weeks from October to November 2008 following approval by the institutional ethics committee.

Healthy and active adult albino rats of either gender, 90-120 days old, and weighing from 200-240 gm each were selected and divided into five groups that were fed on different diets (Table).

.....
Department of Anatomy, ¹Bahria University Medical and Dental College, ²Fatima Jinnah Dental College, ³Hamdard College of Medicine and Dentistry, Hamdard University, Karachi.

Correspondence: Asma Siddiqui. Email: dr_asiddiqui@hotmail.com

Saturated fat was used in the form of butter (Lurpak), in a dose of 20gm/100gm (20%) of diet.¹³ Unsaturated fat was used in the form of corn oil (Corolli), in the dose of 20 ml/100gm (20%) of diet.¹⁴ Fresh crushed garlic was obtained from the local market, in the dose of 6gm/100gm (6%) of diet.¹⁵

Group A animals served as control. They were fed normal diet.¹⁶ Group B animals were fed high saturated fat diet (SFD). Group C animals were given high unsaturated fat (UFD) diet. Group D animals received fresh, crushed garlic, along with butter in their diet. Group E animals received fresh, crushed garlic, along with corn oil in their diet (Table-1).

The animals were observed for 01 week for acclimatisation to the environment, assessment of their health status and diet intake before the commencement of study. The animals were housed in separate cages, with 12-hour light and dark cycle, under laboratory environment. Calculated amount of food with respective constituents and water ad libitum was given to them. The animals were sacrificed at the end of 8 weeks. A midline, longitudinal incision was made, extending from manubrium sterni to lower abdomen. Skin, fascia and muscles were carefully cut and retracted to expose abdominal viscera. After exposure, liver was removed from the body and cut into 2 halves. Both halves were fixed in buffered neutral formalin (BNF) for 24 hours.

The liver tissues from the left lobe were processed for frozen sectioning. Ten micron thick sections were obtained on gelatinised glass slides and stained with Oil red-O and haematoxylin to observe the fat content of hepatocytes¹⁷ and it was graded on the basis of zonal distribution. Zone-I was the area of hepatic lobule at its periphery, close to portal triad; zone-III is the area around the central vein and zone-II is the area in between zone-I and zone-III.¹⁸ It was graded as mild, moderate and

marked depending on deposition of fat in zone-I, zone-I +II and zone-I +II +III respectively. The amount of fat in hepatocytes varies inversely with the amount of glycogen.¹⁸

The hepatic tissues from right lobe were processed and embedded in paraffin. Four micron (4µm) thick sections were cut on rotatory microtome and taken on albumenised glass slides. Paraffin embedded tissues were stained with Periodic acid Schiff (PAS) and haematoxylin to observe the glycogen content of the hepatocytes,¹⁷ depending upon the distribution of glycogen containing hepatocytes in a lobule and graded on the basis of zonal distribution.¹⁸ It was designated as mild, moderate and marked depending on glycogen depletion in zone-I, zone-I+II and zone-I+II+III respectively.

Results

Examination of hepatic frozen sections of liver stained with Oil Red-O and Haematoxylin showed occasional distribution of fat globules within peripheral zone of

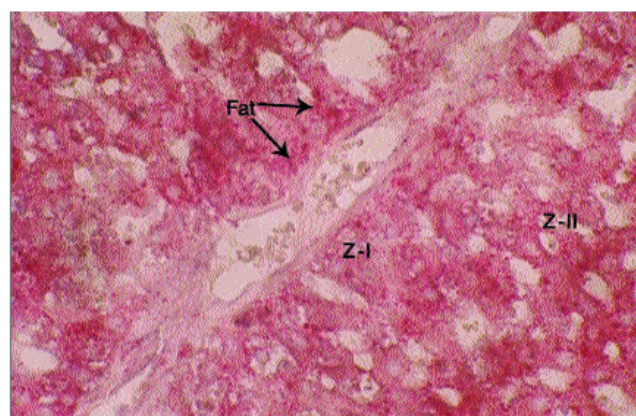


Figure-1: Oil Red-O and Haematoxylin stained, 10µm thick frozen section of control rat liver showing occasional deposition of fat in Zone-I (Z-I) of hepatic lobule (Photomicrograph X400).

Table-1: Diet Scheme for Experimental Study of High-Fat-Diet-induced Fatty Liver in Albino Rats.

Items of Diet	ND Group A	High SFD Group B	High UFD Group C	High SFD + Garlic Group D	High UFD + Garlic Group E
Wheat Flour (G)	11.2	11.2	11.2	11.2	11.2
Milk Powder (G)	2.8	2.8	2.8	2.8	2.8
Chick Peas (G)	2	2	2	2	2
Butter (G)	-	3.2	-	3.2	-
Corn Oil (ml)	-	-	3.2	-	3.2
Garlic (G)	-	-	-	0.96	0.96
Drinking Water	Ad libitum	Ad libitum	Ad libitum	Ad libitum	Ad libitum

ND: Normal Diet
SFD: Saturated Fat Diet
UFD: Unsaturated Fat Diet.

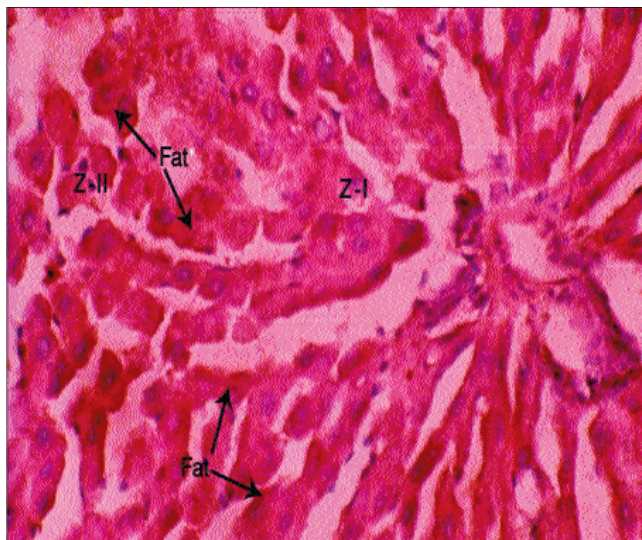


Figure-2: Oil Red-O and Haematoxylin stained, 10µm thick frozen section of butter treated rat liver showing marked fat deposition in Zone-I (Z-I) and Zone-II (Z-II) of hepatic lobule (Photomicrograph X400).

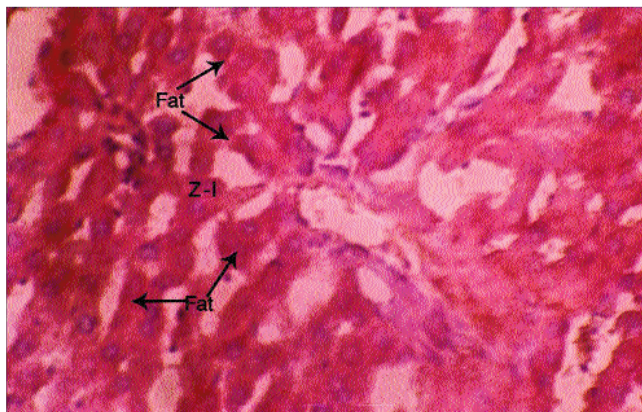


Figure-3: Oil Red-O and Haematoxylin stained, 10µm thick frozen section of corn oil treated rat liver showing moderate deposition of fat in Zone-I (Z-I) and Zone-II (Z-II) of hepatic lobule (Photomicrograph X400).

hepatocytes, close to portal triad in control Group A animals (Figure-1).

Frozen sections stained with Oil red-O and Haematoxylin in Group B animals showed moderate marked lipid infiltration in hepatocytes involving all zones of hepatic lobule compared to control animals (Figure-2). The infiltration was more marked in periportal hepatocytes, where cells were ballooned up with stored lipid laden granules.

In Oil Red-O and Haematoxylin stained frozen sections of Group C animals, there was moderate deposition of lipid

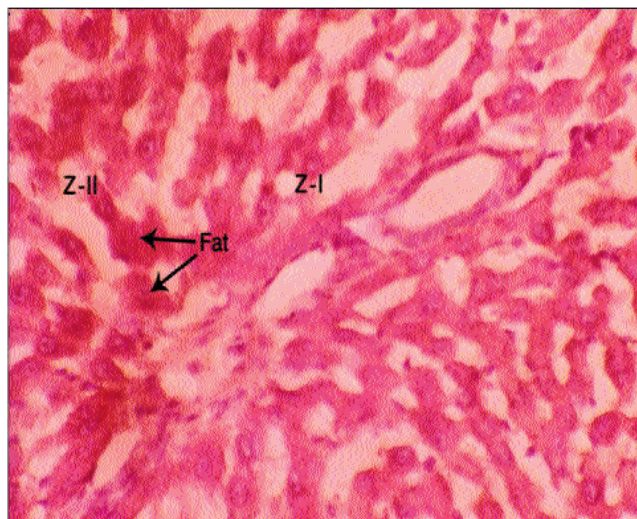


Figure-4: Oil Red-O and Haematoxylin stained, 10µm thick frozen section of butter and garlic treated rat liver showing mild deposition of fat in Zone-I (Z-I) of hepatic lobule (Photomicrograph X400).

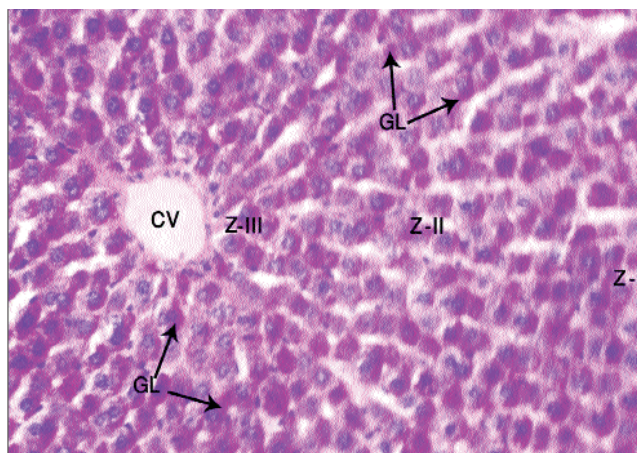


Figure-5: Periodic acid-Schiff (PAS) and Haematoxylin stained, 4µm thick section of control rat liver showing central vein (CV) and glycogen (GL) content in Zone-I (Z-I), Zone-II (Z-II) and Zone-III (Z-III). (Photomicrograph x 400).

granules in zone I and II compared to control (Figure-3).

Animals in butter-and-garlic-treated Group D and corn-oil-and-garlic-treated Group E showed only mild infiltration of lipid granules within hepatocytes in zone-I compared to control (Figure-4).

Examination of hepatic sections in Group A animals stained with PAS and Haematoxylin showed an even distribution of glycogen throughout the lobule. A considerable number of hepatocytes showed slight glycogen content. The glycogen was stored mostly

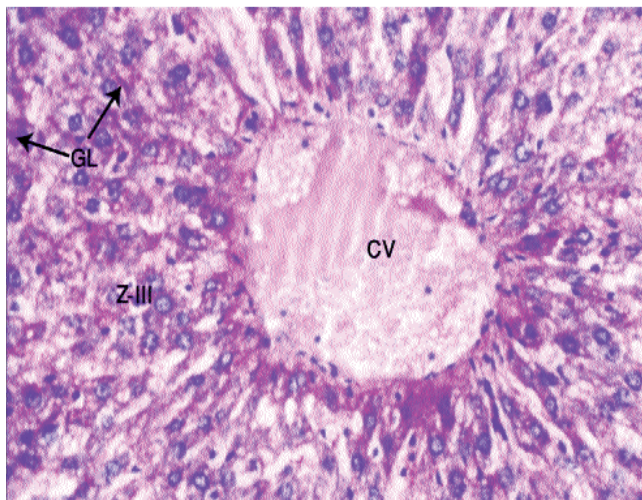


Figure-6: Periodic acid-Schiff (PAS) and Haematoxylin stained, 4 μ m thick section of butter treated rat liver showing dilated central vein (CV) and marked depletion of glycogen (GL) content in Zone-III (Z-III) of hepatic lobule (Photomicrograph x 400).

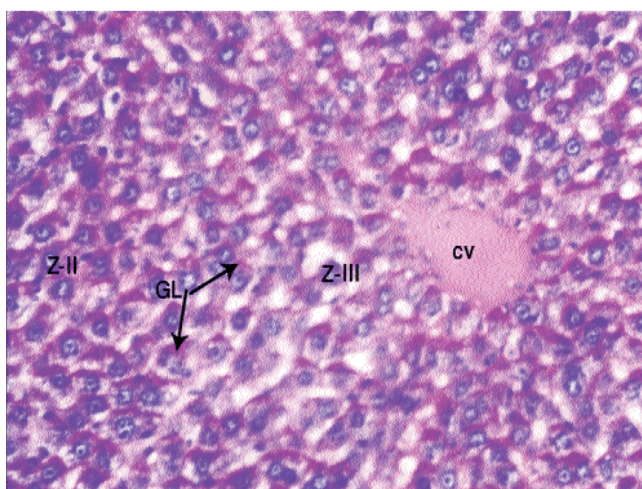


Figure-7: Periodic acid-Schiff (PAS) and Haematoxylin stained, 4 μ m thick section of corn oil treated rat liver showing central vein (CV), Zone-III (Z-III) and moderate depletion of glycogen (GL) in Zone-II (Z-II) of hepatic lobule (Photomicrograph X400).

towards the periphery of hepatocytes (Figure-5). PAS and Haematoxylin stained sections examined in Group B showed marked depletion of glycogen content of hepatocytes in all three zones of hepatic lobule, whereas those of Group C revealed moderate depletion of glycogen in zone I and II compared to control Group A respectively (Figures-6 and 7).

As far as protected groups were concerned, there was mild depletion of glycogen in zone-I in both butter-and-garlic-treated Group D, and corn-oil-with-garlic treated Group E on examination of PAS and Haematoxylin stained

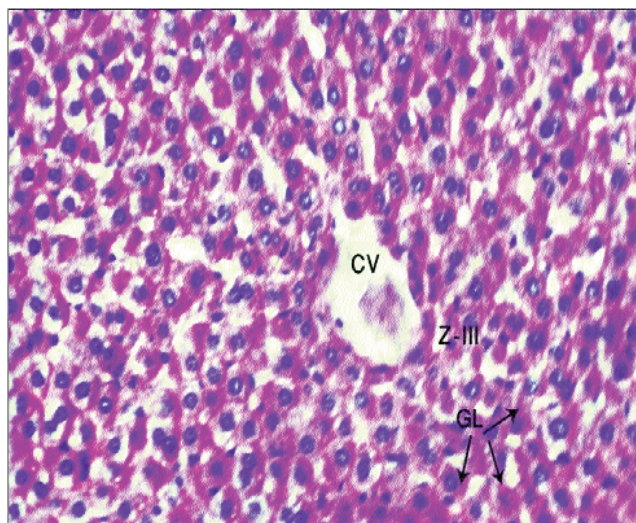


Figure-8: Periodic acid-Schiff (PAS) and Haematoxylin stained, 4 μ m thick section of butter and garlic treated rat liver showing central vein (CV), Zone-III (Z-III) of hepatic lobule and mild depletion of glycogen (GL) content (Photomicrograph X400).

liver sections (Figure-8).

Discussion

Butter and corn oil are commonly used food items. Dietary fat composition is believed to affect body weight regulation independent of the quantity of fat consumed.¹⁹ It is a general belief that unsaturated fats, such as corn oil, are cholesterol-free, so they are often used in large amounts which leads to unwanted metabolic changes. Obesity-related insulin resistance, metabolic syndrome and T2DM are increasing worldwide as the modernisation of diet is taking place even in developing countries. Fatty liver with its subsequent complications, such as NASH, is also showing a steep rise.²⁰ Although various preventive and treatment plans have been improvised in recent years, role of natural food items which can be used on daily basis has been searched for. So this histochemical study was undertaken to evaluate the role of butter as well as corn oil on rat liver, with possible protective effect of garlic.

This study has demonstrated significant deposition of fat in Oil Red-O and Haematoxylin stained frozen sections in butter-treated Group B and corn oil-treated Group C. It is suggested that accumulation of TGs in liver has occurred in response to increased influx of fatty acids to the liver from dietary sources, from adipose tissue and from increased endogenous synthesis of fatty acids. A study²¹ also reported that feeding animals a fat-enriched diet is associated with increased induction of lipogenic enzymes.

Although a high-fat diet may lead to accumulation of fat

in the liver by providing more substrate for TG synthesis, but another important mechanism which may lead to fatty liver is caused by selective insulin resistance. The increased serum insulin fails to suppress hepatic gluconeogenesis, but can promote hepatic lipogenesis.²²

The reduction in the deposition of fat in butter-and-garlic-treated Group D and corn-oil-with-garlic-fed Group E animals can be explained by the fact that garlic inhibits lipogenic enzymes. One study observed substantial reduction of lipid deposition in the hepatocytes of rats which were treated with flaxseed meal compared to rats which received casein diet.²³

In another study, ezetimibe treatment prevented diet-induced hepatic steatosis, weight gain and insulin resistance, which was associated with decreased circulating insulin levels and fatty acid synthesis in the liver, by preventing diet-induced insulin resistance and the associated hyperinsulinaemia.⁵

The butter-treated group showed marked fat deposition compared to corn oil-treated group which had moderate fat deposition in the liver compared to control animals, when both butter and garlic were used in the same amount. This could be explained by the fact that one of the mechanisms responsible for this differential effect of fatty acids is their rate of oxidation. Rats fed saturated fatty acids showed least oxidation and polyunsaturated fatty acids showed higher oxidation rate; fatty acid oxidation rate is inversely related to fat storage, i.e. the higher the oxidation, the lesser the body fat accumulation.²⁴

There was also marked glycogen depletion in tissue sections in rats in butter-treated Group B and moderate glycogen depletion in corn oil-treated Group C, which showed that the distribution of glycogen was inversely proportional to fatty deposition in most of the hepatic lobules. These findings were in accordance with a study²⁵ that observed severe glycogen depletion in PAS-stained liver tissue in ethanol with high fat diet treated rats for 30 days.

The restorative effect of garlic on liver glycogen in butter-with-garlic-treated Group D and corn-oil-and-garlic-treated Group E inhibited deposition of fats within hepatocytes, so glycogen was evenly distributed, but mildly depleted. These findings might be due to blocking enzymes such as 3-hydroxy-3-methyl-glutaryl-CoA reductase (HMGCR), fatty acid synthase and cholesterol 7- α -hydroxylase.²⁶ The reversal of glycogen depletion was seen in another study, as supplementation with black tea extract restored the glycogen content in hepatocytes

in ethanol with high-fat diet-induced hepatotoxicity in male Wistar rats.²⁵

Conclusion

High-fat diet, whether saturated fats or unsaturated fats, produced injury to liver, although the damage was more marked after saturated fat consumption. Concomitant use of fresh crushed garlic ameliorated and protected the damage to liver by restricting the deposition of fat and depletion of glycogen in high-fat diet-induced fatty liver in rats.

Conflict of interest: None

Funding Agency: None

References

1. Assy N, Nassar F, Nasser G, Grosovski M. Olive oil consumption and non-alcoholic fatty liver disease. *World J Gastroenterol* 2009; 15: 1809-15
2. Grasselli E, Canesi L, Voci A, Matteis RD, Demori I, Fugassa E, et al. Effects of 3,5-Diiodo-L-Thyronine Administration on the liver of High Fat Diet-Fed Rats. *J Exp Biol Med* 2007; 233: 549-57
3. Cho Y, Kwon E, Kim H, Jeon S, Lee K, Choi M. Differential effect of corn oil-based low trans structured fat on the plasma and hepatic lipid profile in an atherogenic mouse model: comparison to hydrogenated-trans-fat. *Lipids Health Dis* 2011; 10: 10-5
4. Zafrani ES. Non-alcoholic fatty liver disease: An emerging pathological spectrum. *Virchows Arch* 2004; 444: 3-12
5. Bari O, Neuschwander-Tetri B, Liu M, Portincasa P, Wang D. Ezetimibe: Its Novel Effects on the Prevention and the Treatment of Cholesterol Gallstones and Nonalcoholic Fatty Liver Disease. *J Lipids* 2012; 2012: 302847.
6. DeAngelis R, Markiewski M, Taub R, Lambris J. A High-Fat Diet Impairs Liver Regeneration in C57BL/6 Mice through Over expression of the NF- κ B Inhibitor, I κ B- α . *Hepato* 2005; 42: 1148-57
7. Xiao J, Guo R, Fung M, Liang E, Chang RC, Ching Y, et al. Garlic-Derived S-Allylmercaptocysteine Ameliorates Nonalcoholic Fatty Liver Disease in a Rat Model through Inhibition of Apoptosis and Enhancing Autophagy. *Evid Based Complement Alternat Med* 2013; 2013: 642920
8. Lin H, Chen C, Chen Y, Lin Y, Mersmann H, Ding S. Enhanced amelioration of high-fat diet-induced fatty liver by Docosahexaenoic acid and Lysine supplementations. *Bio Med Res Int* 2014; 2014: 310981
9. Shaarawy SM, Tohamy AA, Elgendy SM, Elmageed Z, BS, Bahnasy A, Mahamed MS, et al. Protective Effects of Garlic and Silymarin on NDEA-Induced Rats Hepatotoxicity. *Int J Biol Sci* 2009; 5: 549-57
10. Mohamed MS, Abdel- Kader MM, Kassem KS. Effect of dietary garlic and onion on liver and tibial mineral concentrations in omega-3 fatty acids rich oil fed rats. *Agric. Biol J N Am* 2011; 2: 745-51.
11. Mahammadi A, Oshaghi EA. Effect of garlic on lipid profile and expression of LXR alpha in intestine and liver of hypercholesterolemic mice. *J Diabetes Metab Disord* 2014; 13: 13-20
12. Adler AJ, Holub BJ. Effect of garlic and fish oil supplementation on serum lipid and lipoprotein concentrations in hypercholesterolemic men. *Ame J Clin Nutr* 1997; 65: 445-50
13. Woods SC, Seeley RJ, Rushing PA, D'Alessio D, Tso P. Controlled High-fat Diet Induces an Obese Syndrome in Rats. *J Nutr* 2003; 133: 1081-7
14. Tannenbaum BM, Brindley DN, Tannenbaum GS, Dallman MF,

- McArthur MD, Meaney MJ. High-fat feeding alters both basal and stress-induced hypothalamic-pituitary-adrenal activity in the rat. *Am J Physiol Endocrinol Metab* 1997; 273: 1168-77
15. Qureshi AA, Abuirmeileh N, Din ZZ. Inhibition of cholesterol and fatty acid biosynthesis in liver enzymes and chicken hepatocytes by polar fractions of garlic. *Lipids* 1983; 18: 343-8
 16. Mahan LK, Arlin MT. *Krause's Food, Nutrition and Diet Therapy*. 8th ed. Philadelphia: W.B. Saunders Company, 1992; 726-7.
 17. Bancroft JD, Gamble M. *Theory and practical of Histological Techniques*. 6th ed. Edinburgh: Elsevier Churchill Livingstone, 2008; 25-7, 134-5, 177-8
 18. Ross M, Pawlina W. *Histology, A text and atlas with correlated molecular biology*. 5th ed. Philadelphia: Lippincott Williams and Wilkins, 2006; 582-3
 19. Rolland V, Roseau S, Fromentin G, Nicolaidis S, Tome D, Even PC. Body weight, body composition, and energy metabolism in lean and obese Zucker rats fed soybean oil or butter. *Am J Clin Nutr* 2002; 75: 21-30
 20. Hamaguchi M, Kojima T, Takeda N, Nakagawa T, Taniguchi H, Fujii K, et al. The metabolic syndrome as a predictor of nonalcoholic fatty liver disease. *Ann Int Med* 2005; 143: 722-8
 21. Rivera CA, Abrams SH, Tchamitchi MH, Allman M, Ziba TT, Finegold MJ, et al. Feeding a corn oil/sucrose enriched diet enhances steatohepatitis in sedentary rats. *Am J Physiol Gastrointest Liver Physiol* 2005; 296: 386-93
 22. Lin J, Betters JL, Yu L. Niemann-pick C1-like 1 (NPC1L1) protein in intestinal and hepatic cholesterol transport. *Ann Rev Physiol* 2011; 73: 239-59
 23. Bhatena SJ, Ali AA, Haundenschild C, Latham P, Ranich T, Mohammad AI, et al. Dietary Flaxseed Meal is More Protective than Soy Protein Concentrate against Hypertriglyceridemia and Steatosis of the Liver in an Animal Model of Obesity. *J Am Coll Nutr* 2003; 22: 157-64
 24. Jen KC, Buisson A, Pellizzon M, Ordiz F, Ana LS, Brown J. Differential effects of Fatty Acids and Exercise on Body Weight Regulation and Metabolism in Female Wistar Rats. *Exp Biol Med* 2003; 228: 843-9
 25. Das D, Mukherjee M, Das AS, Mukherjee S, Mitra C. Aqueous extract of black tea (*Camellia sinensis*) prevents chronic ethanol toxicity. *Curr Sci* 2005; 88: 952-61
 26. Yeh Y, Liu L. Cholesterol-lowering effects of garlic extracts and organosulfur compounds: human and animal studies. *J Nutr* 2001; 131: 9895-38.
-