

Two accidental hanging cases of children

Ertugrul Gok,¹ Selcuk Cetin,² Erol Baduroglu,³ Recep Fedakar,⁴ Okan Akan,⁵ Naile Esra Saka⁶

Abstract

The cases emphasise the implementation of safety measurements which may prevent the occurrence of accidental hanging in children. Two accidental hanging cases were autopsied at The Council of Forensic Medicine, Bursa Group Chairmanship, Morgue Department. The inquest papers written by police were examined and the scenes and autopsy findings are presented. The first case was a four year old girl and the second case was a five year old boy. Their manners of death were determined as an accident. The first accident occurred out of home, but the second accidental hanging occurred at home. It was seen that childhood deaths due to hanging are preventable. Detailed medico-legal investigation in order to elucidate the manner of death is required in similar cases.

Keywords: Accident, Hanging, Death, Autopsy, Children.

Introduction

The vast majority of deaths by hanging are related to suicide.¹⁻³ These hanging deaths are rarely observed in children.^{1,2,4} In addition, accidental and homicidal hangings in the paediatric population are generally considered as very uncommon.⁵ We report two cases, one of a four year old girl and the other of a five year old boy. Police inquest papers were examined and the scenes and autopsy findings were presented. The autopsies of two cases were performed at the Council of Forensic Medicine, Bursa Group Chairmanship, Morgue Department.

Case Reports

Case-1

The information about the hanging accident was obtained by police from the victim's grandmother. There had been nobody near the victim at the time of the accident. According to police inquest paper, the four year old girl was playing with her toys on the balcony of the first floor of their house. There was a skipping rope and

toys on the balcony. One end of the skipping rope was tied to the handle of the balcony door. Probably, the girl was holding the other end of the rope to jump over by herself. It is very interesting how this rope tangled around her neck. While she was playing on the balcony, she probably lost her balance and the skipping rope tangled around her neck. It seems, she fell down and was suspended by this rope in the air, yet her feet failed to touch onto the ground. There was no railing on the balcony of the first floor (Figure-1a). She had been tangled at around 1:15 pm on the 29th of July 2010. Her grandmother immediately came out when she heard her scream. In the shocking scene, her grandmother promptly grabbed a knife and cut the rope, and rapidly took the girl to the nearest primary healthcare centre. Just after her instant medical examination, it was assessed that the girl had expired.

The autopsy was performed at 5.00 pm on the same day. In the external examination, a 0.8 cm wide ligature mark (Figure-1b) was extending upwards superficially, and a 3x0.5 cm ecchymosis was determined at the right side of the neck, beginning from the lower part of the larynx on the front part of the neck, continuing through the nape and stopping there. In addition, cyanosis was determined on the fingernails' folds. In the internal examination, ecchymosis on the right and left thyroid glands and under the arytenoids cartilage was determined. There were no petechial haemorrhages.

Case-2

The victim was a five year old boy. The information about the hanging accident was obtained by police from the victim's mother. According to police inquest paper, his mother laid him in his cradle. When his mother fell asleep in the room, the victim got up and climbed to the rope of a handmade swing made by using a sheet (Figure-2a). Then, he probably lost his balance and the rope of the swing tangled around his neck and he was strangled. When his mother woke up, she saw her child hanging with the rope and immediately called the emergency services and asked for help at around 11.30 am in early September 2010. After the examination made by emergency service personnel, it was reported that the boy had died.

The autopsy was performed at 5.00 pm on the same day.

.....
^{1,4}Department of Forensic Medicine, School of Medicine, Uludag University, Bursa, ²Kayseri Forensic Medicine Unit, ³Rize Forensic Medicine Unit, ⁴⁻⁶The Council of Forensic Medicine of the Ministry of Justice, Bursa Group Chairmanship, Turkey.

Correspondence: Ertugrul Gok. Email: ertugrulgk@gmail.com

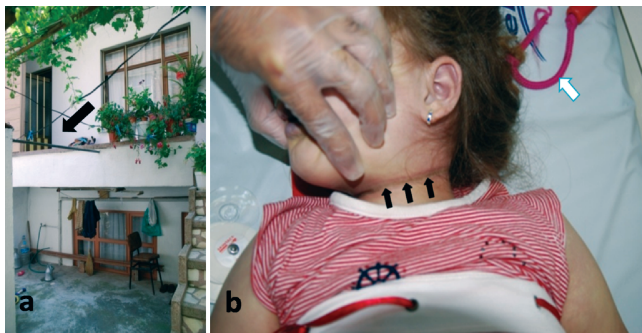


Figure-1: (a) The place of incident (black arrow), (b) Ligature mark on his neck (black arrows) and a part of skipping rope tangled around her hair (white arrow).

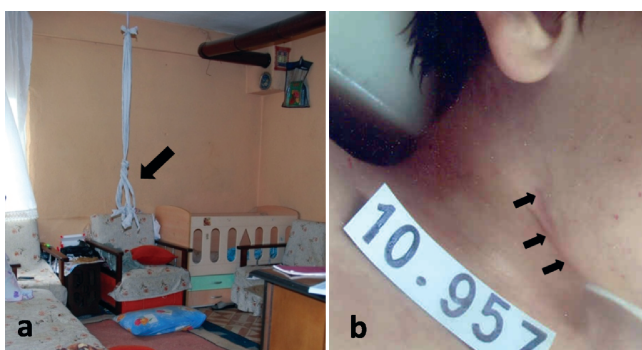


Figure-2: (a) Handmade swing in the living room (black arrow), (b) Ligature mark (black arrows).

The prominent findings of the autopsy were a 0.5 cm wide ligature mark (Figure-2b) beginning from the front side of the neck, and superficially running upwards on both sides of the neck but ending at the ear level, diffuse petechial haemorrhages on the face, an injection mark with ecchymosis on the left elbow internal plica and petechial haemorrhages on the surface of the thymus.

One of the deaths of these children occurred in summer and the other in autumn. According to toxicological analysis, no substance was found and no other traumatic injury was determined. We reported that the deaths of the children occurred as a result of accidental hanging.

Discussion

Accidental deaths due to hanging are usually seen in childhood.⁶ In several reports, the ages of the victims were between 6 months to 14 years.⁷⁻⁹ Most of the paediatric and adolescent strangulation deaths were reported as homicides in Delhi, India.¹⁰ However, half of the deaths have been reported as accidental hanging, and the rest of the deaths have been reported as suicidal hanging in children in Southeast Scotland.⁸ All of the

hanging deaths in children originated from accidents in Konya, Turkey.⁷ Two cases, presented here, are also accidental deaths.

In a study, 12 cases of accidental hangings that involved children and the ages of the cases ranged from 6 months to 11 years have been reported. The deaths of seven cases resulted from entanglement with a ligature (scarf, handmade sash, braid rope) that was wrapped around a handmade swing-like cradle (e.g., hammock), which was intended to prevent the baby from falling down. As the infant leaned out of the cradle, the ligature wrapped around his/her neck and caused asphyxia. Three out of twelve cases involved a rope in the courtyard of the houses. Of the remaining two cases, one involved a rope hanging down from a construction wall and the other occurred when the child's neck was entangled in a tight electrical heater cable while he was crawling on the floor.⁷ Different forms of death related to accidental hangings have been reported in the literature. For example, in five out of six cases, the children appeared to have been engaged in tentative play behaviour involving ligatures around their necks which had gone tragically wrong. In the other case, a child accidentally hung herself while playing unsupervised with a dog's leash on a garden playslide.⁸ Two accidental strangulation deaths, one was due to the entrapment of clothes in the moving cycle-rickshaw and the latter was due to the encircling of the umbilical cord on a newborn, have been reported.⁹ An accidental partial hanging following suspension from a local handmade rocking cradle has been reported. The unattended child woke up and probably started fidgeting in the cradle, and her cloth slipped from the belly up to her neck.¹⁰

In our first case, while the girl was playing with her toys and jumping over the skipping rope on the balcony on her own and the skipping rope had tangled around her neck. In our second case, there was a hand-made rocking cradle and while the boy was trying to swing, the rope of the swing tangled around his neck. Therefore, the skipping rope and hand-made rocking cradle may lead to fatal consequences if the children are not supervised closely. These children are the victims of negligence.

In Turkish Criminal Code, according to article 81.1, any person who unlawfully kills a person is sentenced to life imprisonment. According to article 82.1.d, in case of commission of this offense; against any one of the antecedents or descendants, or spouse or brother/sister, is evaluated as qualified form of felonious homicide. According to article 85.1, any person who causes death of a person by negligent conduct is punished with imprisonment from three years to six years. But according

to article 22.6, no punishment is given if the legal consequence of the negligent offense exclusively results with injury of the offender either in person, rights or reputation in such a way not to require imposition of punishment; in case of intentional negligence, the punishment to be imposed may be abated from one half to one sixth.¹¹ Therefore, a detailed medico-legal investigation in order to elucidate the manner of death should be required.

In the hanging cases, the scene must be protected until the evidences at the scene are determined. The relation between hanging and the items such as desk, chair, footstool found at the scene should be investigated. The statements of the relatives or acquaintances of the victim can provide important clues for the manner of death. The victim's psychiatric illness (particularly depression, psychosis), drug addiction or previous suicide attempt are important in terms of the origin of death. It is important to investigate whether a suicide note has been written. Once the body has been removed from the hanging place, the external examination must be performed at the scene as some artefacts may occur during the transport of the body to the morgue. Hanging cases are accepted as criminal cases. For this reason the autopsy has to be performed.²

Conclusion

In conclusion, close supervision, safe playgrounds or environments and awareness about the dangerous items are very important to prevent accidental hanging in children. Potentially dangerous objects should be removed from play areas. Most of those accidental childhood hanging deaths could have been prevented by adequate parental or nursing supervision, basic

education and restriction of access to ligatures. In addition, a detailed medico-legal investigation is required in order to elucidate the manner of death and correct interpretation of accidental nature of hanging.

Disclosure

This study was presented as a poster at the 9th Symposium on the Forensic Sciences, Trabzon, Turkey, April 28-30, 2011.

References

1. Tirasci Y, Gören S. Deaths due to hanging in Diyarbakir. *Dicle Med J*. 2000; 27:151-8 (in Turkish).
2. Özaslan A. In Asphyxias due to hanging and strangulation. Forensic medicine textbook. Istanbul: Istanbul University Cerrahpasa School of Medicine Publications; 2011, pp 158-84. (in Turkish).
3. Gören S, Tıraşçı Y, Üzün ?. Retrospective evaluation of the deaths due to hanging in Diyarbakir. *Türkiye Klinikleri J Foren Med* 2005; 2:1-4 (in Turkish).
4. Luke JL. Asphyxial deaths by hanging in New York City, 1964-1965. *J Forensic Sci*. 1967; 12: 359-69.
5. Clark MA, Feczko JD, Hawley DA, Pless JE, Tate LR, Fardal PM. Asphyxial deaths due to hanging in children. *J Forensic Sci*. 1993; 38:344-52.
6. Koç S, Özaslan A. In general asphyxias, hanging, strangulation, suffocation, chemical asphyxias. In: Soysal Z, Çakalir C, eds. Forensic Medicine Vol. 1. İstanbul: İstanbul University Cerrahpasa School of Medicine Publications; 1999, pp 405-57 (in Turkish).
7. Dogan KH, Demirci S, Erkol Z, Gulmen MK. Accidental hanging deaths in children in Konya, Turkey between 1998 and 2007. *J Forensic Sci*. 2010; 55:637-41.
8. Wyatt JP, Wyatt PW, Squires TJ, Busuttill A. Hanging deaths in children. *Am J Forensic Med Pathol*. 1998;19:343-6.
9. Verma SK. Pediatric and adolescent strangulation deaths. *J Forensic Leg Med*. 2007; 14:61-4.
10. Saha A, Batra P, Bansal A. Strangulation injury from indigenous rocking cradle. *J Emerg Trauma Shock*. 2010;3:298.
11. Turkish Criminal Code. [online] [cited 2013 Mar 13]; available from: URL:http://www.justice.gov.tr/basiclaws/Criminal_Code.pdf.