

## Metaplastic squamous cell carcinoma of breast. A pathology case report with review of literature

Abdulkader Mohammad Albasri,<sup>1</sup> Akbar Shah Hussainy,<sup>2</sup> Mohamed Aboulmaaty Elkablawy,<sup>3</sup> Ahmed Alhujaily,<sup>4</sup> Abdulaziz Aljohani<sup>5</sup>

### Abstract

Metaplastic Breast Carcinoma (MBC) is a group of rare breast cancers; squamous cell carcinoma (SCC) is its most common member. Due to rarity of the condition, frequent case reports have been published of late. In the last one year alone, there were about a dozen such reports. Here we report a case of primary squamous cell carcinoma in a 62-year-old female, with a 3.5cm mass in the left breast. Biopsy and mastectomy reports confirmed Metaplastic carcinoma, with 21 benign lymph nodes. The tumour was triple negative and cytokeratin 5/6 positive. We are reporting the first case of squamous cell carcinoma of breast from our region, and we recommended large multi centre studies.

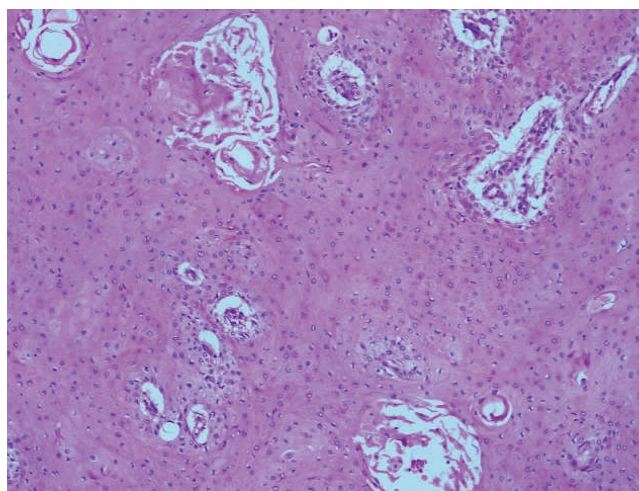
**Keywords:** Metaplastic, Squamous, Carcinoma, Breast, Pathology.

### Introduction

Metaplastic breast carcinomas (MBC) belong to a group of rare breast cancers (BC). Squamous cell carcinoma (SCC) of breast is the most common member of this group. The rarity of MBC has prompted the researchers to report MBC cases quite frequently. In the year 2014 alone, there were about a dozen case reports of MBC in scientific literature, ranging from single cases to short series of 17 cases from Turkey and 18 cases from Poland.<sup>1,2</sup> Recently, SCC of breast has been found to account for a significant proportion within these MBC case reports. Our objective is to report the first case of SCC of breast from Al-Madinah region of the Kingdom of Saudi Arabia (KSA).

### Case Report

A 62-year-old woman presented at the Breast Clinic of King Fahad Hospital, Al-Madinah, KSA, in December 2011. Three weeks earlier, she had discovered a swelling in the upper outer quadrant of left breast. There was neither



**Figure-1:** Low-power photomicrograph of the breast tumour exhibiting diffuse sheets of well-differentiated squamous cells separated by small vascular channels (H&E, x100).

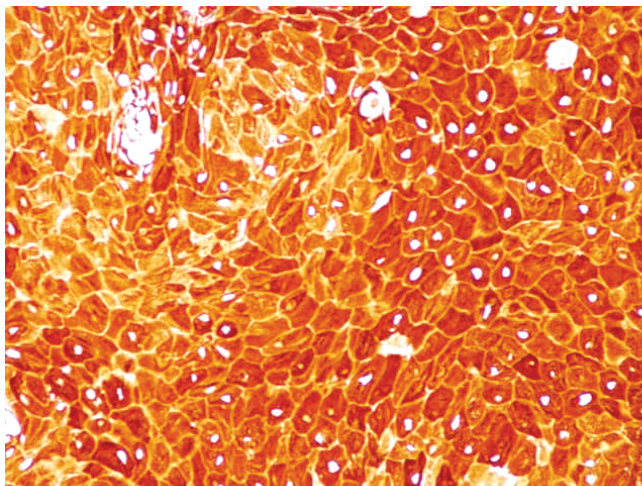
retraction of nipple nor any nipple discharge. Physical examination revealed firm, rubbery, non-tender and mobile lesion in the left breast, measuring 3.5cm across, without fixation to the skin or underlying tissue. No lymph node enlargement was noted. The right breast examination was normal. A mammogram was performed which showed a spherical mass lesion with ill-defined speculated margins. No microcalcifications were seen.

Biopsy report revealed multiple solid areas and cystic spaces lined by atypical squamous cells. Squamous pearls and individual cell keratinisation was also noted. Some solid areas revealed ductal differentiation. Stroma was fibrous with chronic inflammatory cell infiltration. The diagnosis of "Malignant epithelial neoplasm with squamous differentiation, consistent with metaplastic carcinoma" was made.

Left modified radical mastectomy with axillary clearance was performed. The mastectomy specimen on sectioning revealed a central 3.5 x 2.5cm, grayish white mass. On microscopic examination, there was duct papillomatosis along with cystically dilated spaces filled with secretions. Few areas of intraductal papillary carcinoma were also

.....  
<sup>1,2</sup>Department of Pathology, Taibah University, Al Madinah Al Monawwarah, Kingdom of Saudi Arabia, <sup>3</sup>Department of Pathology, Faculty of Medicine, Menoufyia University, Menoufia, Egypt, <sup>4,5</sup>Department of Pathology, King Fahad Hospital, Madinah, Saudi Arabia.

**Correspondence:** Akbar Shah Hussainy. Email: akbar.hussainy@gmail.com



**Figure-2:** High-power photomicrograph of the breast tumour stained with high molecular weight cytokeratins exhibiting strong cytoplasmic positivity (CK 5/6, x200).

present. A number of ducts revealed squamous metaplasia, cellular atypia and foci of well-differentiated SCC (Figure-1). Intraductal papillary carcinoma component was less than 10%. No lymphovascular invasion was seen. There was no connection with surface epithelium. A total of 21 lymph nodes were recovered, exhibiting no evidence of metastatic disease. Immunohistochemical (IHC) evaluation was negative for oestrogen receptor (ER), progesterone receptor (PgR) and human epidermal growth factor receptor 2 (Her2/neu) over expression. The tumour cells were positive for cytokeratin 5/6 (Figure-2). The final diagnosis of left modified radical mastectomy specimen was "Metaplastic SCC, well-differentiated", with intraductal papillary carcinoma (<10%). All surgical margins were tumour free. On the basis of pathology report, the disease was "Stage IIA (T2N0Mx)". She was referred to the Oncology Department of another hospital for further management. The information regarding post-surgical management was not available to the authors, hence this case report is being presented as a Pathology Case Report.

## Discussion

MBC belongs to a group of rare breast cancers with a prevalence of 0.2%. SCC is one of the most common members of this group. A study in 2014 from Poland quoted a figure of 56% SCC in their series of 18 MBC cases.<sup>2</sup> In 2012, a study from Turkey reported 9 cases with squamous component in their 14 cases series of MBC (64%).<sup>3</sup> Whereas in 2010, a study from Morocco concluded that SCC accounted for 68% of all their MBC cases.<sup>4</sup>

In 2003, World Health Organisation (WHO) classified MBCs into pure epithelial and mixed types, but in the 2012 WHO

classification of BC (2012), these have been described as: low-grade adenosquamous carcinoma, fibromatosis-like metaplastic carcinoma, SCC, spindle cell carcinoma, and carcinoma with mesenchymal differentiation (chondroid differentiation, osseous differentiation and other types of mesenchymal differentiation). In the new 2012 update, myoepithelial carcinoma has also been added to the list of MBCs. In an overview of the 2012 WHO classification, a study in Germany advocated a descriptive classification because of the heterogeneity of MBCs.<sup>5</sup>

SCC of breast is considered to originate from the metaplasia of ductal epithelium and is independent of any connection with overlying skin. Moreover, there should be no other primary SCC at any other site in association with it. SCC may occur as a 'pure' or a 'mixed' type. The pure SCC has more than 90% SCC component and does not contain any other neoplastic component. The classical example of 'mixed' SCC type is the adenosquamous carcinoma of breast.

In keeping with these definitions, our case belongs to a mixed type of SCC, as it also contains foci of intraductal papillary carcinoma. In recent literature a study reported 6 cases of SCC in 17 cases of MBC, out of which 4 were mixed adenosquamous and 2 pure SCC.<sup>1</sup> Another study reported 3 cases of SCC out of 7 cases in series of MBC; 01 pure SCC, 01 mixed SCC with glandular differentiation, and 01 mixed SCC with spindle cell sarcoma component.<sup>6</sup>

The age of the patient reported in the present study was 62 years. Historically, SCC of breast is a disease of old age, as cited earlier.<sup>7</sup> A study from Turkey has reported 14 MBC cases, out of which 9 had squamous component, with an age range of 32-76 years (mean: 51 years).<sup>3</sup> A 2014 study from Turkey reported an age range of 38-66 years (mean 52.6 years) in their six cases.<sup>1</sup> In the Jeddah study, 2 out of 3 cases with squamous differentiation were noticeably young (30, 32 and 69 years).<sup>6</sup>

MBCs are considered to be large tumours at the time of presentation. A study from Turkey reported six cases with a size range of 1.5-4.5cm (mean 2.7cm).<sup>1</sup> Another study from Turkey reported 14 MBC cases, out of which 9 had squamous component; tumour sizes ranged 4-8 cm.<sup>3</sup> From Morocco a study of 8 cases of pure SCC reported average tumour size of 7.3cm, with a range of 3.5 to 18cm.<sup>4</sup>

In terms of single case reports, the minimum size of 1cm was reported from Korea in a case of Adeno SCC.<sup>8</sup> The maximum size of SCC breast has been reported to be 10cm from India.<sup>9</sup>

No lymph node metastasis was noted in our patient who underwent axillary clearance node surgery yielding 21 lymph nodes. Two of 3 cases of SCC showed single node metastasis in a study.<sup>6</sup> One study reported lymph node positivity in 6 of 8 patients.<sup>3</sup> Lymph node metastasis was reported from Morocco in only one of 8 cases.<sup>4</sup>

Triple negativity (for ER, PgR and Her2) was found to be consistent in the previous studies as well as in the recent ones, although some reported occasional sample showing positivity of any one of the three markers.<sup>1,3</sup> Cytokeratin positivity was reported in the epithelial component by most recent studies.<sup>4,6</sup>

### Conclusion

MBC is a group of rare heterogeneous cancers, with SCC being its most common member. We reported the first case of SCC from Al-Madinah region, with the demographic and pathological features in keeping with historical and recent literature. Close clinical follow-up, larger multidisciplinary and multicentre studies are recommended to investigate the demographic, pathological and radiological findings of SCC of breast along with treatment options and prognosis.

---

### References

1. Gultekin M, Eren G, Babacan T, Yildiz F, Altundag K, Guler N, et al. Metaplastic breast carcinoma: a heterogeneous disease. *Asian Pac J Cancer Prev* 2014; 15: 2851-6.
2. Nowara E, Drosik A, Samborska-Plewicka M, Nowara EM, Stanek-Widera A. Metaplastic breast carcinomas - analysis of prognostic factors in a case series. *Contemp Oncol* 2014; 18: 116-9.
3. Esbah O, Turkoz FP, Turker I, Durnali A, Ekinci AS, Bal O, et al. Metaplastic breast carcinoma: case series and review of the literature. *Asian Pac J Cancer Prev* 2012; 13: 4645-9.
4. Znati K, Bennis S, Abbas F, Chraibi M, Hammam N, Chahbouni S, et al. Pure Primary Squamous Cell Carcinomas of the Breast: A Report of Eight Cases. *J Med Cases* 2010; 1: 23-6.
5. Sinn H-P, Kreipe H. A Brief Overview of the WHO Classification of Breast Tumors, 4th Edition, Focusing on Issues and Updates from the 3rd Edition. *Breast Care (Basel)* 2013; 8: 149-54.
6. Altaf FJ, Mokhtar GA, Emam E, Bokhary RY, Mahfouz NB, Al Amoudi S, et al. Metaplastic carcinoma of the breast: an immunohistochemical study. *Diagn Pathol* 2014; 9: 139
7. Badge SA, Gangane NM, Shivkumar VB, Sharma SM. Primary squamous cell carcinoma of the breast. *Int J Appl Basic Med Res* 2014; 4: 53-5
8. Cha YJ, Kim GJ, Park BW, Koo JS. Low-Grade Adenosquamous Carcinoma of the Breast with Diverse Expression Patterns of Myoepithelial Cell Markers on Immunohistochemistry: A Case Study. *Korean J Pathol* 2014; 48: 229-33
9. Pujani M, Agarwal S, Jain M. Her 2 neu Positivity in Squamous Cell Carcinoma: A Clue to the Diagnosis of Metaplastic Carcinoma Breast. *Case Reports from the Tropics*. 2013; 1: e5.