

STRESS ELECTROCARDIOGRAPHY IN ANGINA PECTORIS: EVALUATION OF THE TWO STEPS MASTER'S TEST

Muhammad Ilyas, Masood Anwar, Nasir Ali, Nazir Khan and S.M. Husnain Sherazi

Abstract

In a series of 345 consecutive cases of angina pectoris seen in our Unit during a 2 years period (1976-77) ischaemic changes were present at rest in 65 cases (19%). In 280 cases with normal electrocardiogram at rest two-steps Master's test was carried out. Positive electrocardiographic changes were recorded in 89 cases (32%). These consisted mainly of S-T segment depression in the precordial leads V3-6 and/or avL or avF (71%), and with associated T wave changes in 17 cases (19%). Ectopics occurred in 6 cases (6.7%) and P wave changes were recorded in 3 cases (3.3%). No case of acute myocardial infarction or fatal dysrhythmia consequent to stress testing was recorded.

Introduction

The diagnosis of coronary heart disease is based on history, electrocardiography, serum enzymology and coronary angiography and the diagnosis of angina pectoris is made primarily from history of exertional chest pain and ischaemic changes may be present in the electrocardiogram. Stress electrocardiography is used to demonstrate ischaemic changes which are not recorded at rest (Rochmis and Blackburn, 1971). Stress procedures adopted to study ischaemic changes include two steps test, bicycle ergometry, treadmill, right atrial pacing and ambulatory dynamic electrocardiography (Master and Rosenfeld, 1961). This paper describes our experience of stress electrocardiography using Master's Two Steps Test in cases of angina pectoris.

Material and Methods

Three hundred and forty five (345) consecutive out patients of uncomplicated angina pectoris were seen in the Muhammadi Hospital, Peshawar during the period January to December 1977. The diagnosis of coronary heart disease with angina pectoris was made on history of exertional chest pain and response to glyceryl trinitrate tablets. 65 out of 345 cases (19%) showed electrocardiographic evidence of coronary heart diseases at rest; and the remaining 280 cases which showed no abnormality in resting electrocardiogram were included in the study. The series included 187 males and 93 females, age range 34 to 80 years, mean 51 years. Hypertension was present in 87 cases (31%) and diabetes mellitus in 32 cases (11%). Patients of angina pectoris associated with myocardial infarction, congestive cardiac failure and cardiac conduction disturbances were not included in the study. After the physical examination a twelve lead electrocardiogram was obtained. Each patient was then exercised for a definite number of trips in 90 seconds according to the two Steps Master's Test (Master and Rosenfeld, 1961). Immediately after the exercise an electrocardiogram was repeated in the reverse sequence i.e. leads V6-V1, avF, avL, III, II and I were recorded in that order. S-T segment depression of 1 mm or more with a duration of 0.06—0.08 seconds in one or more precordial leads V3-6, or avF or avL was regarded as positive stress test. Similarly T and P waves changes were also observed as being significant and appearance of ectopics was recorded.

Results

Out of a total of 345 cases of angina pectoris 65 cases (19%) showed S-T segment and T wave changes of myocardial ischaemia. In 280 cases with no ischaemic changes at rest exercise testing by the Master's procedure yielded positive result in 89 cases (32%: Table I). This mainly consisted of S-T segment depression in the precordial leads V3-6 and/or in avL or avF in 63 cases (71%). S-T segment and associated T wave changes were present in 17 cases (19%). Ectopic developed in 6 cases (6.7%) after exercise P wave depression was recorded in 3 cases (3.3%). Post exercise S-T segment, T and P waves changes and appearance of ectopics are shown in Figures 1, 2 and 3.

In 12 cases (4%) pronounced episode of angina pectoris developed requiring discontinuation of the test. In no case acute myocardial infarction or fatal dysrhythmia developed consequent to the stress test

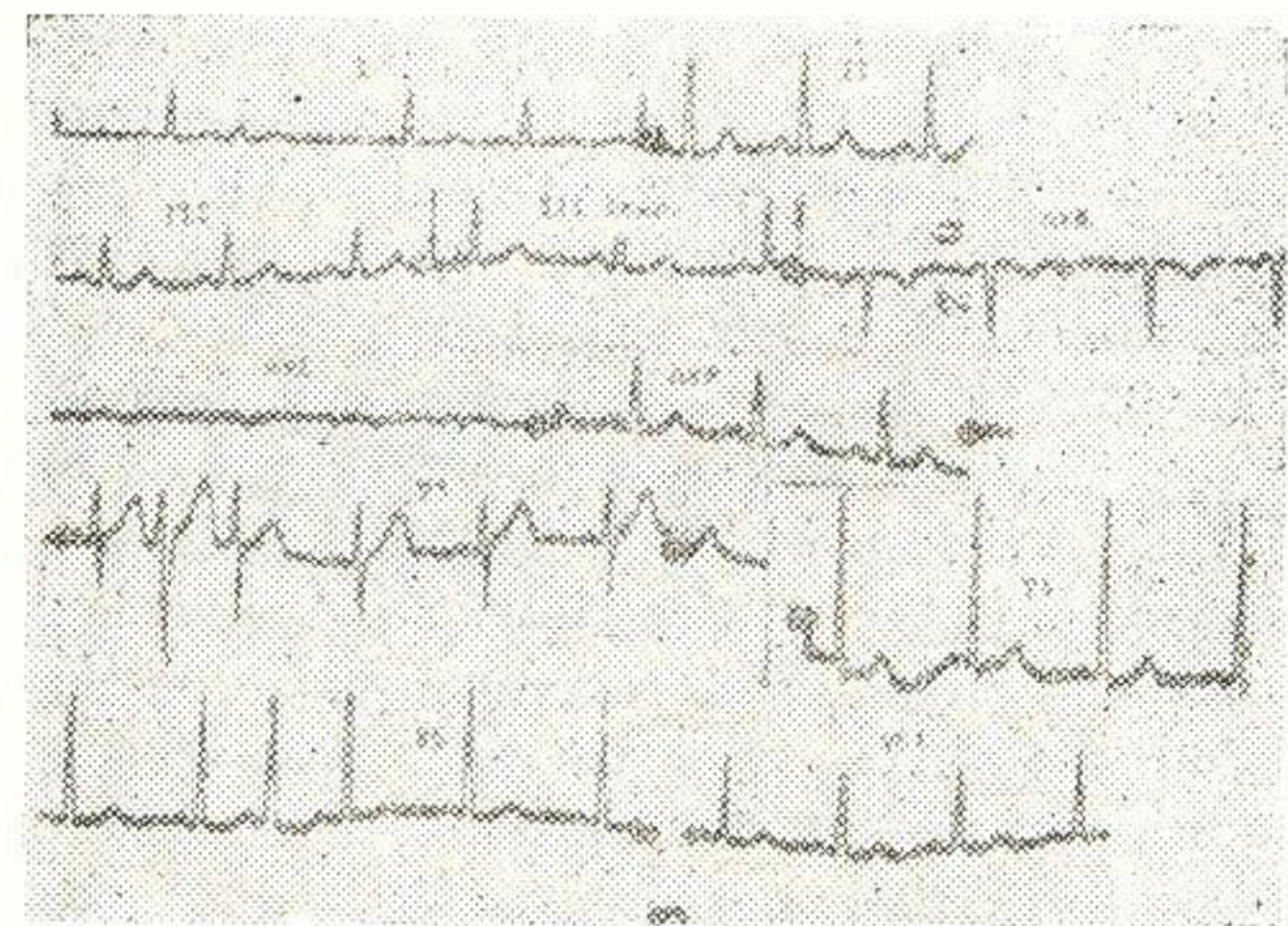
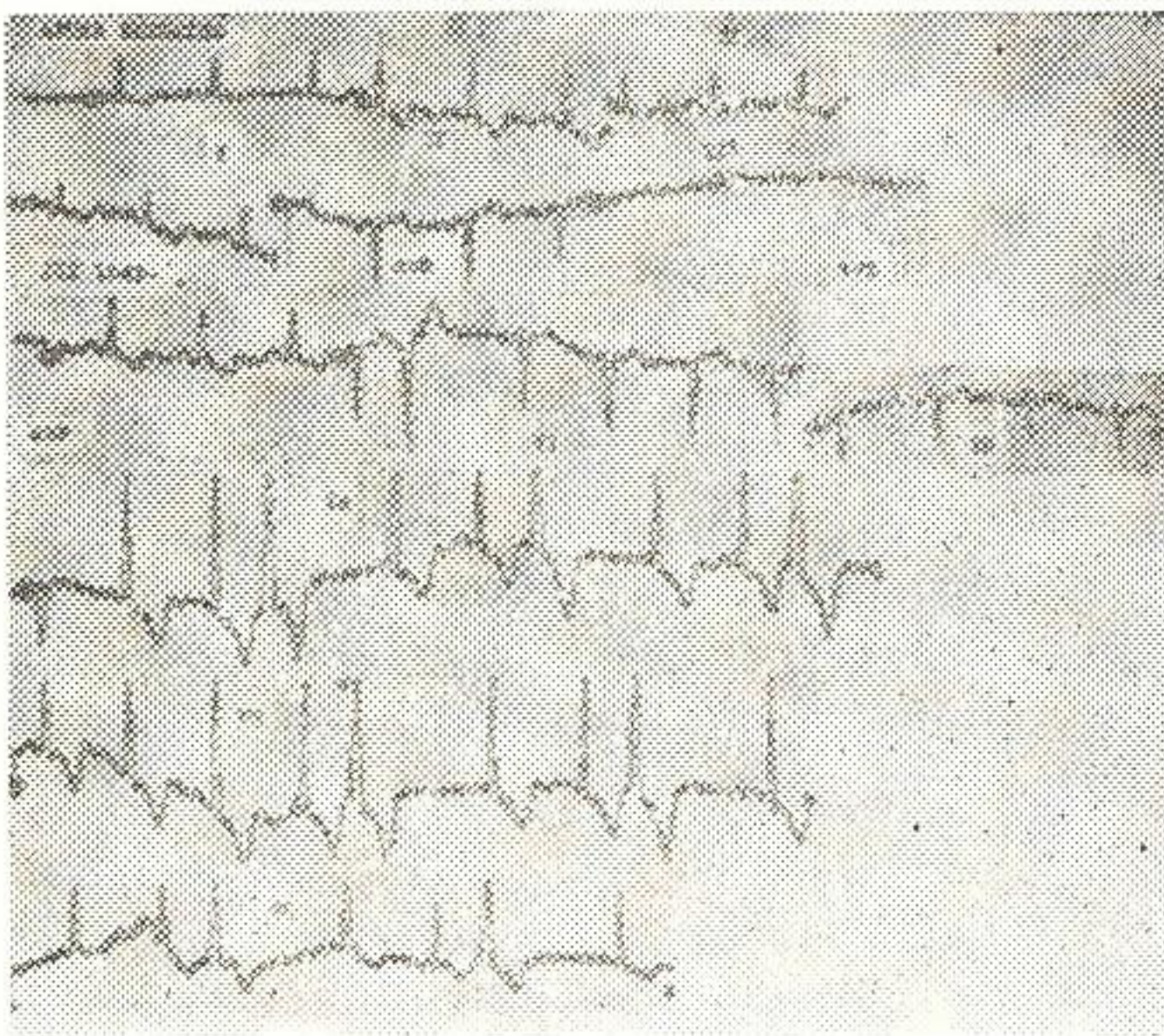
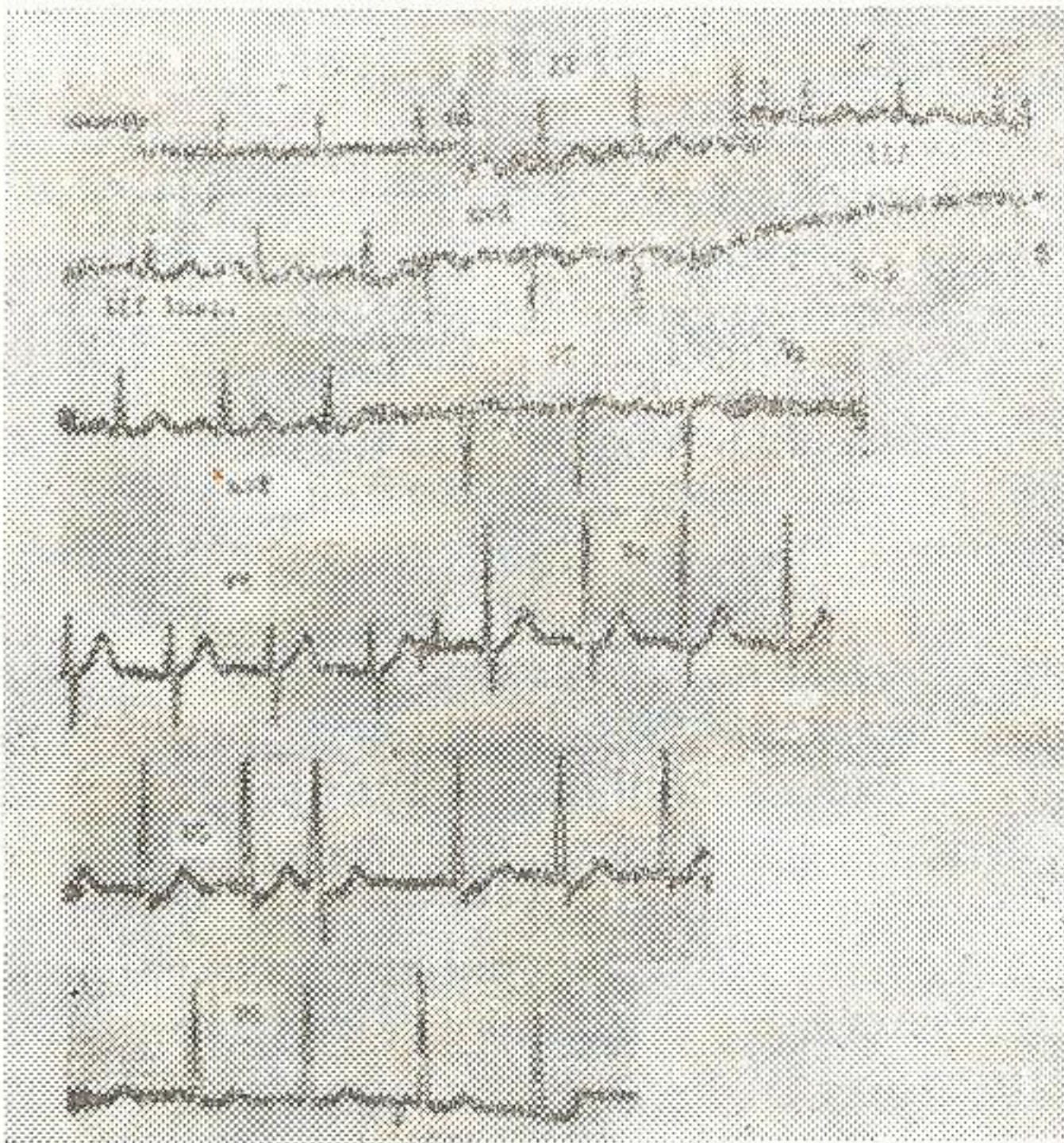


Fig. 1. Mr. A.H. 55 years, a case of angina pectoris: A: E.C.G. at rest with normal S-T and T, B, B: S-T segment depression with T wave inversion after exercise in leads I, II, III, avF, V4-6, and appearance of ventricular extrasystoles, C: E.C.G. taken after 30 minutes rest shows normalization S-T segment and T wave.




Fig. 2: Mrs. S.G. 48 years with angina pectoris: E.C.G. at rest (recording 1, 3, 5): after exercise (recording 2, 4, 6) shows S-T segment depression and T wave changes in leads, I, II, III, avL, avF, V2-6.




Fig. 3: Mr. M.A. 47 years, a patient of angina pectoris: A: E.C.G. at rest, upright P wave in lead VI, B: After exercise, inverted P wave in lead VI, and T wave inversion in avL and $V6$.

Table I: Positive Results of Two-Steps Master's test 89 Cases (32%, N280)

ECG Changes	Cases	%
S-T Depression (V3-6 and/or avL , avF)	63	71
S-T and T Changes	17	19
Ectopics	6	6.7
P Wave Changes	3	3.3

Discussion

The use of stress electrocardiography in the assessment of coronary heart disease is well established. The available stress tests include Master's Two-Step Test (Master and Rosenfeld, 1961), bicycle ergometry, treadmill, right atrial pacing (Sowton 1967); and more recently dynamic

electrocardiography in ambulatory patients has been used (Willhelm and Rinalds, 1968; Wold et al., 1974). In our country, with one or two exceptions, the two-steps test is most widely available. It is really the poor man's best stress test. We have tried to valuate the two steps Master's test in our patient population in Peshawar.

In our series of 345 cases of angina pectoris ischaemic changes were already present at rest in 65(19%) cases and of the remaining 280 cases with normal electrocardiogram at rest stress testing yielded positive results in 89 cases (32%), consisting mainly of S-T segment depression in precordial leads V3-6, avF or avL. In our experience no serious complication occurred.

The co-relation ship of stress electrocardiography with coronary arteriography has been demonstrated (Hagge et al., 1973); 18 out of 158 patients (11%) with coronary heart disease had stress induced electrocardiographic changes and 17 of these cases showed severe obstruction of coronary arteries which was compatible with the zone of ischaemic localization. Redwood and Epstein (1972) have reported that in patients with typical angina pectoris or with chest pain which clearly does not resemble angina pectoris the stress testing is unnecessary as it provides little additional information. Post exercise P wave changes i.e. biphasity or inversion of P wave due to left atrial overloading following stress has also been reported (Wada 1973). Normal S-T variant or Grusin's pattern (Grusin 1954) i.e. S-T segment elevation in various leads which may disappear on exercise. has to be remembered in the differential diagnosis of coronary heart disease in our country, as this has also been reported by Ahmad and co-workers from Karachi (1968).

Stress testing is also utilized for the evaluation of coronary bypass surgery (Dodeck et al., 1973). Stress electrocardiography is regarded as a safe procedure. In a survey of techniques and safety in about 170,000 stress tests, in 73 medical centres in the U.S.A., the combined morbidity was 4/10,000 and mortality 1/10,000 (Rochmis and Blackburn, 1971).

References

- Ahmad N., Beg., M.A., Abbasi, A.S. and Syed, S.A. (1968) Electrocardiogram in healthy individuals-A study of 1388 subjects in Karachi. JPMA., 18:3,
- Grusin, H. (1954) Peculiarities of the African's electrocardiogram and the changes observed in serial studies. Circulation 9:860.
- Dodeck, A., Kasebaum, D.G., Briswold, H.E. (1973) Stress electrocardiography in the evaluation of aortocoronary bypass surgery. Amer. Heart J. 80:292.

Hagge, F. Tuna, N., Burchel, H. (1973). Coronary arteriographic findings in Patients with axis shifts or S-T segment elevation of exercise-stress testing, Amer. Heart J. 86:603.

Master, A.M., Rosenfeld, I. (1961) The two step exercise test brought up to date. New York J. Med., 61:1850.

Rochmis, P., Blackburn, H. (1971) Exercise Tests., A survey of procedures, safety and litigation experience in approximately 170,000 tests. JAMA., 217:1061.

Redwood, D.R., and Epstein, S.E. (1972) Use and limitations of stress testing in the evaluation of ischaemic heart disease. Circulation, 36:1115.

Sowton, Edqar. (1967). Atrial pacing for angina threshold. British Heart Journal 1967, Br. Heart Journal 29:130.

Wilhelm, S.K., Rinaldo, J. A. (1968) 57 Mount Carmal Mercy Hospital Bulletin.

Wold, E., Tzivoni, D., Stern, S. (1974). Comparison of exercise tests and 24 hour ambulatory electrocardiographic monitoring in detection of S-T changes, Br. Heart J. 36.

Wada, Takashi. (1973). Post exercise P wave changes: correlation with S-T Jap. Circulation Journal 37:36.