

Cafe Coronary

Pages with reference to book, From 320 To 321

M. Raza (Department of Medicine New York University Medical Centre, New York U.S.A.)

A.R. Berger (Present Address: 90-A, Depot Lines Guards Avenue, Karachi-3 Pakistan.)

Abstract

Sudden death due to foreign body obstruction of upper airways often termed Cafe Coronary has received considerable attention in the last two decades. However there are no previous reports of Electro Cardiographic records of the Victims or survivors of the condition. The case reported by us is the first with electrocardiographic, observation of the patient. The electrocardiographic changes consisted of rhythm disturbance and ischemia (JPMA 34:320, 1984).

Sudden death due to obstruction of upper airways has been known popularly as Cafe Coronary; a term coined by Haugen in 1963¹. Cafe Coronary, as the name implies points to cardiovascular causes as the cause of death. However a survey of literature shows except for the study of Bendkowski,² the cause of death as revealed by autopsy findings was obstruction of upper airways by food, there was no evidence of myocardial infarction and the cause of death was attributed to "choking and asphyxiation"^{3,4}.

Despite the interest in the pathogenesis of cafe coronary and its emergency treatment⁵ there are no reports of electrocardiographic records of victims or survivors.

We report a patient who had rhythm disturbance, and profound ischaemic changes associated with cafe coronary.

PD. a 70 year old white male a known Diabetic, Right below knee amputee had an emergency code around lunch time. When the CPR team arrived patient was blue, gasping for breath, with barely perceptible pulses. A diagnosis of food asphyxiation was made. The anaesthetist on the team (J.M.) with great difficulty pulled out a piece of stake 2" x 3" (Fig.1)




Fig. 1 Stake 2" X 3" removed from phrynx.

from pharynx. With tracheo-bronchial toilet, oxygen given by nasal catheter, the colour of patient improved. An electrocardiogram taken at the same time showed coupled and frequent P.V.Cs, marked ST depression in precordial leads V2 to V6, and T inversion in leads II AVL (Fig. 2).

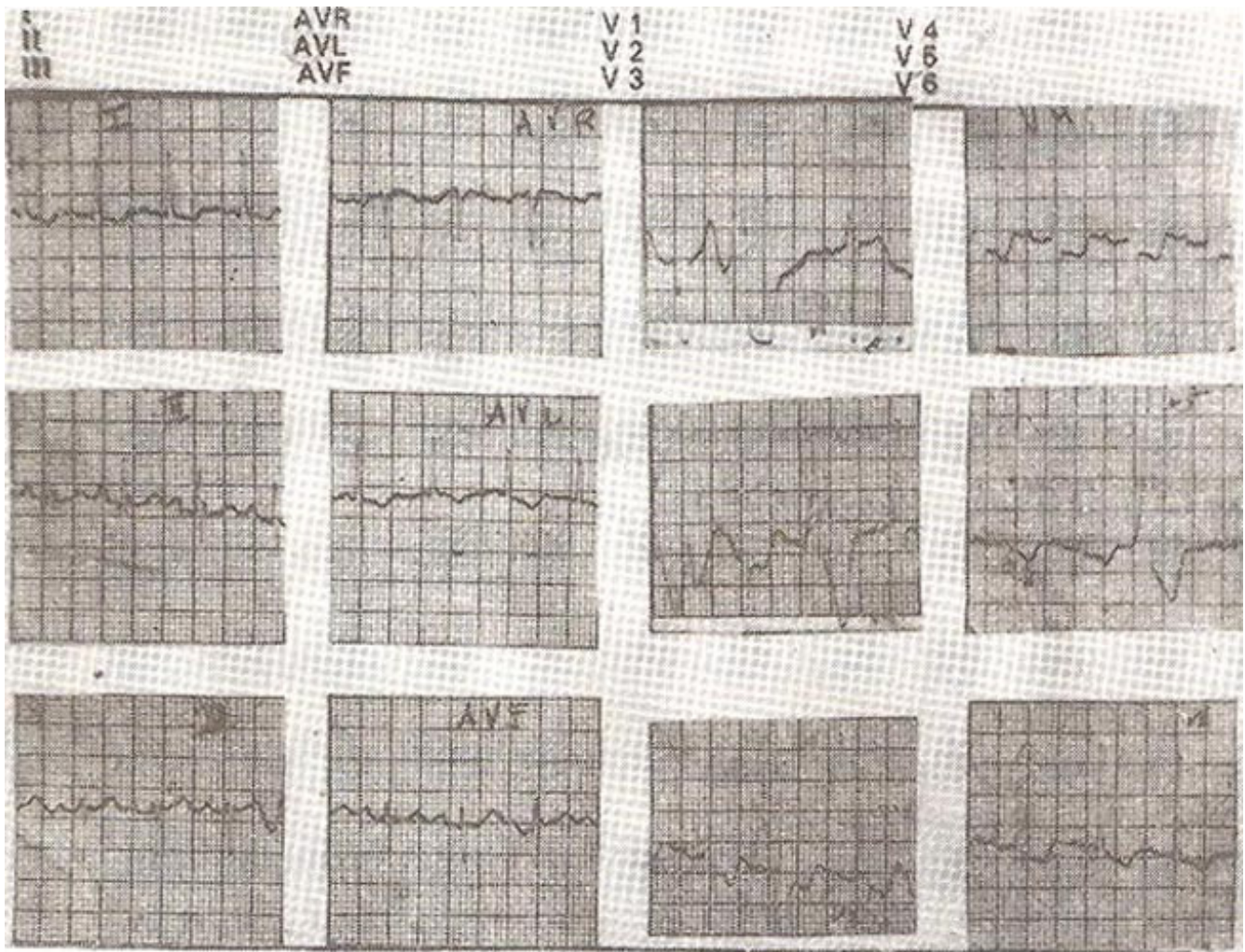


Fig. 2 Electrocardiogram taken immediately after resuscitation showing frequent premature ventricular contractions and ST segment T wave changes.

Patient was immediately given a bolus of 100 mg of lidocaine I.V. and transferred to I.C.U. for further management. Investigations showed Hgb. 12.2 Gm%: Hct. 37%: WBC 14,300 cmm: Neutrophils 83%: Stab 10%: Lymphocytes 5%: Monocytes 2%: BS 140%: Na 137 meq: K 4.3meq: Cl 110meq: C02 26meq: BUN 25mg%: Osmolarity 286 milli osmoles: SGOT, SGPT, LDH done serially for three days were within normal. The CPK was 68 Units on the first day and rose to 95 Units (Normal 0 - 18.8). However, CPK MB fraction was not done and the raised CPK could have been due to cardiopulmonary resuscitative measures. The arterial blood gases on 4 litre oxygen per minutes were normal. (Ph 7.42, P02 106mmHg, PCO2 24 mmHg, HCO3 15meq, O2 saturation 97%). Chest X-Ray showed bilateral pulmonary infiltrates.

During ECG monitoring there was no recurrence of P.V.Cs. An electrocardiogram done 2. the next day showed regression of ST depression and minimal T wave flattening (Fig. 3).

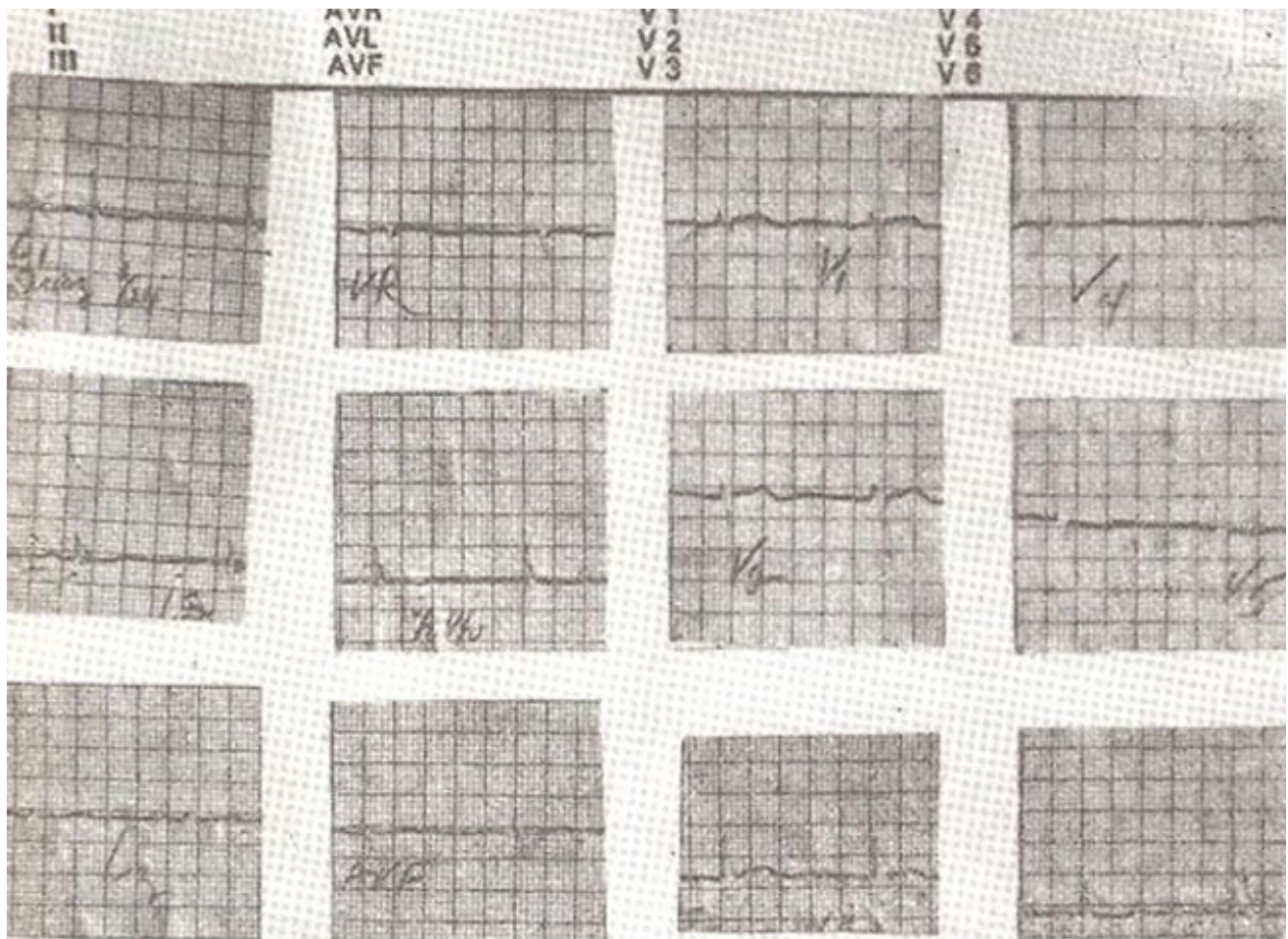


Fig. 3 ECG taken a day after resuscitation showing resolution of ischemic changes and rhythm disturbances.

An Echocardiogram done on the next day of the incident was also normal.

A survey of literature shows that there are no previous reports of electrocardiographic observations of patients with cafe coronary. The case demonstrates, following cafe coronary the patients may suffer from ischaemia and rhythm disturbances. Appropriate management requires all such patients should have electrocardiogram after resuscitation. Prompt detection, treatment of rhythm disturbances and myocardial ischaemia may improve the outlook for the victims of cafe coronary.

Acknowledgement

We gratefully acknowledge the help provided by Dr. J. Maquiran in the management of this patient.

References

1. Haugen, R.K. The cafe coronary; sudden deaths in restaurants. JPM.A., 1963; 186: 142.
2. Bendkowaski, B. Sudden death in the elderly. J.Am. Geriatr. Soc., 1973;21: 405.
3. Gelperin, A. Sudden death in an elderly population from aspiration of food. J. Am. Geriatr. Soc., 1974; 22: 135.
4. Mittleman, R.E. and Wetle, C. V. The fatal cafe coronary; foreign body airway obstruction. JPM.A.,

1982; 247: 1285.

5. Heimlich, H.J. A life-saving maneuver to prevent food-choking. JPMA., 1975; 234: 398.