

# A HISTOLOGICAL STUDY OF THE EFFECTS OF NONSTEROIDAL ANTI-INFLAMMATORY DRUGS (NSAIDs) ON THE GASTRIC AND DUODENAL MUCOSA

Pages with reference to book, From 287 To 290

Naheed Moghal, N.A. Jafarey ( Department of Pathology, Jinnah Postgraduate Medical Centre, Karachi. )

## Abstract

The effect of nonsteroidal anti-inflammatory drugs (NSAIDs) on the gastric and duodenal mucosa was studied in 53 patients. On endoscopic biopsies, 87% patients showed gastritis and 90% duodenitis. Chronic superficial gastritis was the most frequent lesion in the stomach (49%); and mild duodenitis in the duodenum (54%). The antrum was the most frequently involved site in the stomach. An interesting finding in cases of duodenitis was the presence of dilated intestinal glands plugged with mucus (JPMA 39: 287, 1989).

## INTRODUCTION

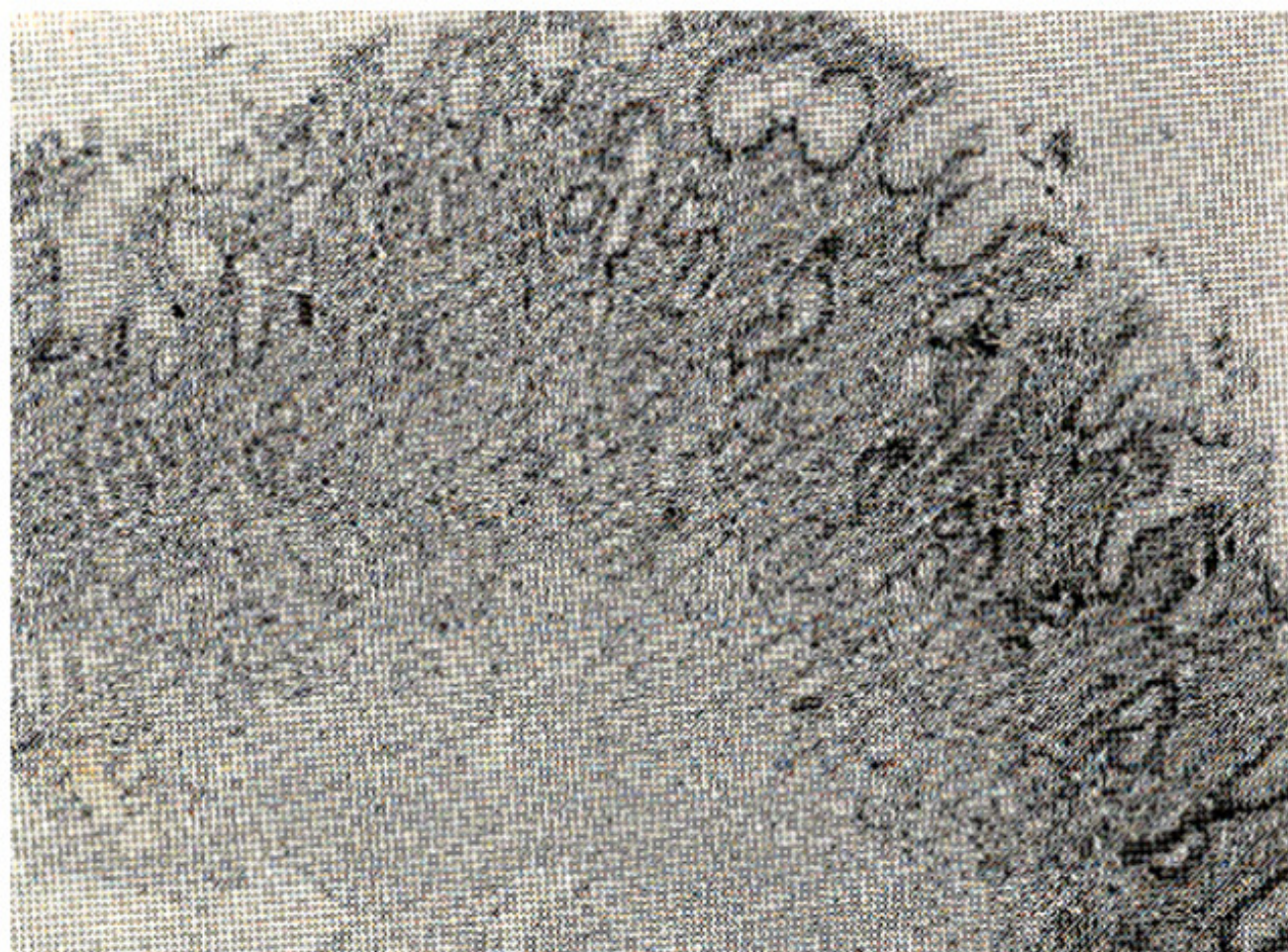
Nonsteroidal anti-inflammatory drugs (NSAIDs) are known to damage the gastro-duodenal mucosa.<sup>1</sup> Most studies until the present time on the gastrointestinal effects of NSAIDs have been confined to symptoms of patients participating in therapeutic trials, and studies of gastrointestinal blood loss.<sup>2</sup> Endoscopic studies have been done, but these have relied on the macroscopic appearance of the mucosa, which may correlate poorly with histological change.<sup>3</sup> Only a few studies have been conducted regarding histological changes produced by NSAIDs using endoscopic biopsies.<sup>4,5</sup> This study was undertaken to see the histological effects of NSAIDs on gastric and duodenal mucosa in our population.

## PATIENTS AND METHODS

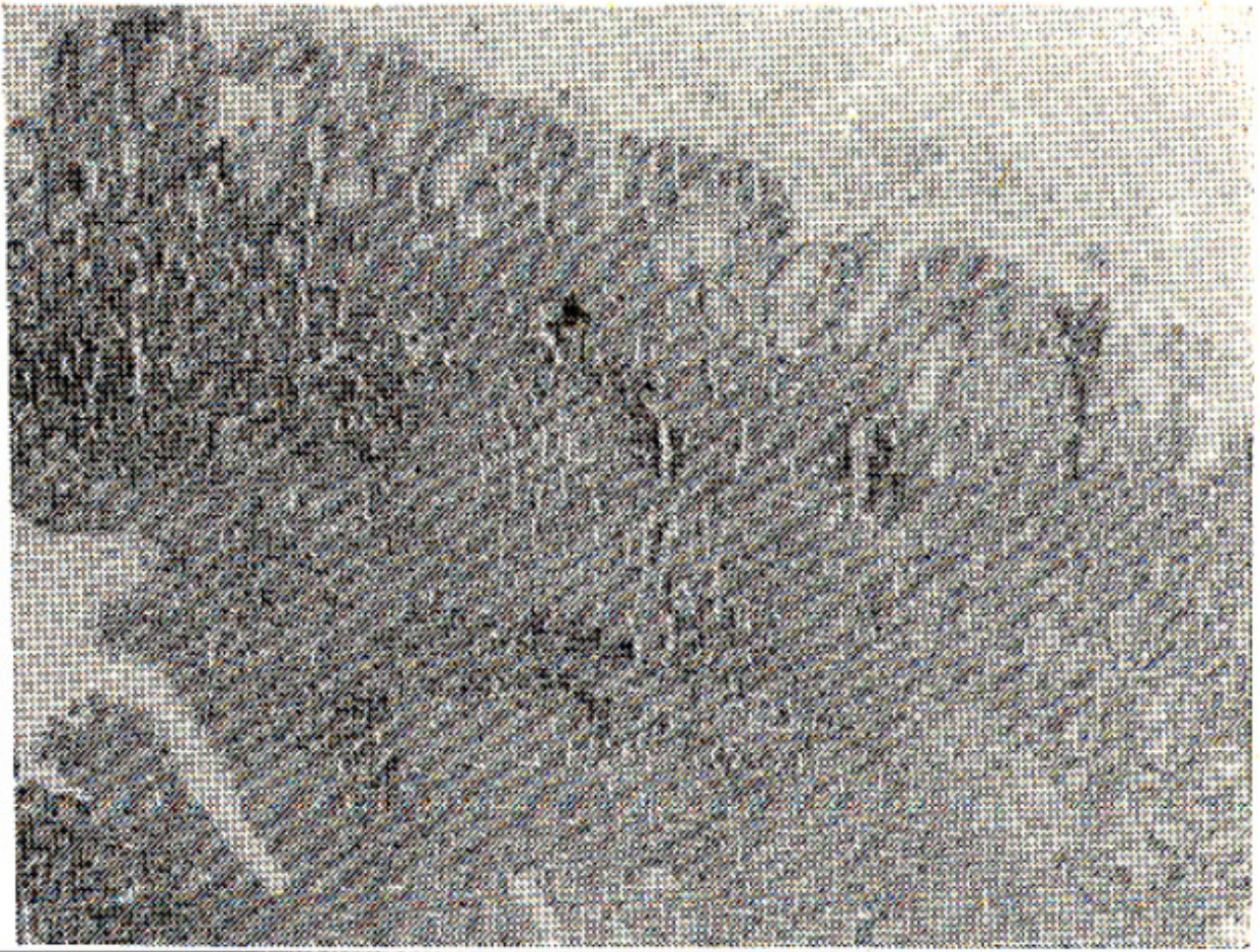
Two hundred and fifty six endoscopic biopsies were taken from 53 patients taking regularly for at least one week NSAIDs in therapeutic doses. Biopsies were obtained from five standard sites in all patients: greater curvature and lesser curvature of stomach, antrum, duodenal bulb, and second part of duodenum. Control biopsies were taken from 25 persons who were not taking NSAIDs and were endoscopically normal. The biopsies were received in 10% neutral buffered formalin and were processed for paraffin embedding. The sections were stained with H&E, reticulin, trichrome and PAS stains. The diagnostic criteria were those described by Whitehead.<sup>6</sup>

## OBSERVATIONS AND RESULTS

The ages of the patients ranged from 13 to 60 years. Forty were females and 13 males. The diseases for which the patients were taking NSAIDs were: rheumatoid arthritis, osteoarthritis, cervical spondylosis, ankylosing spondylitis and backache. In this study 7 different NSAIDs were used as shown in table. No significant change was seen in 6 patients (11.32%); chronic gastritis (Figures 1-4)



**Figure 1. Antrum showing chronic gastritis. Heavy inflammatory infiltrate extending between the pits. H & E x 70.**



**Figure 2. Chronic atrophic gastritis in antral mucosa. Diffuse infiltration with inflammatory cells extending deep into the glandular zone. Loss of glands is seen in the centre. H & E x 70.**

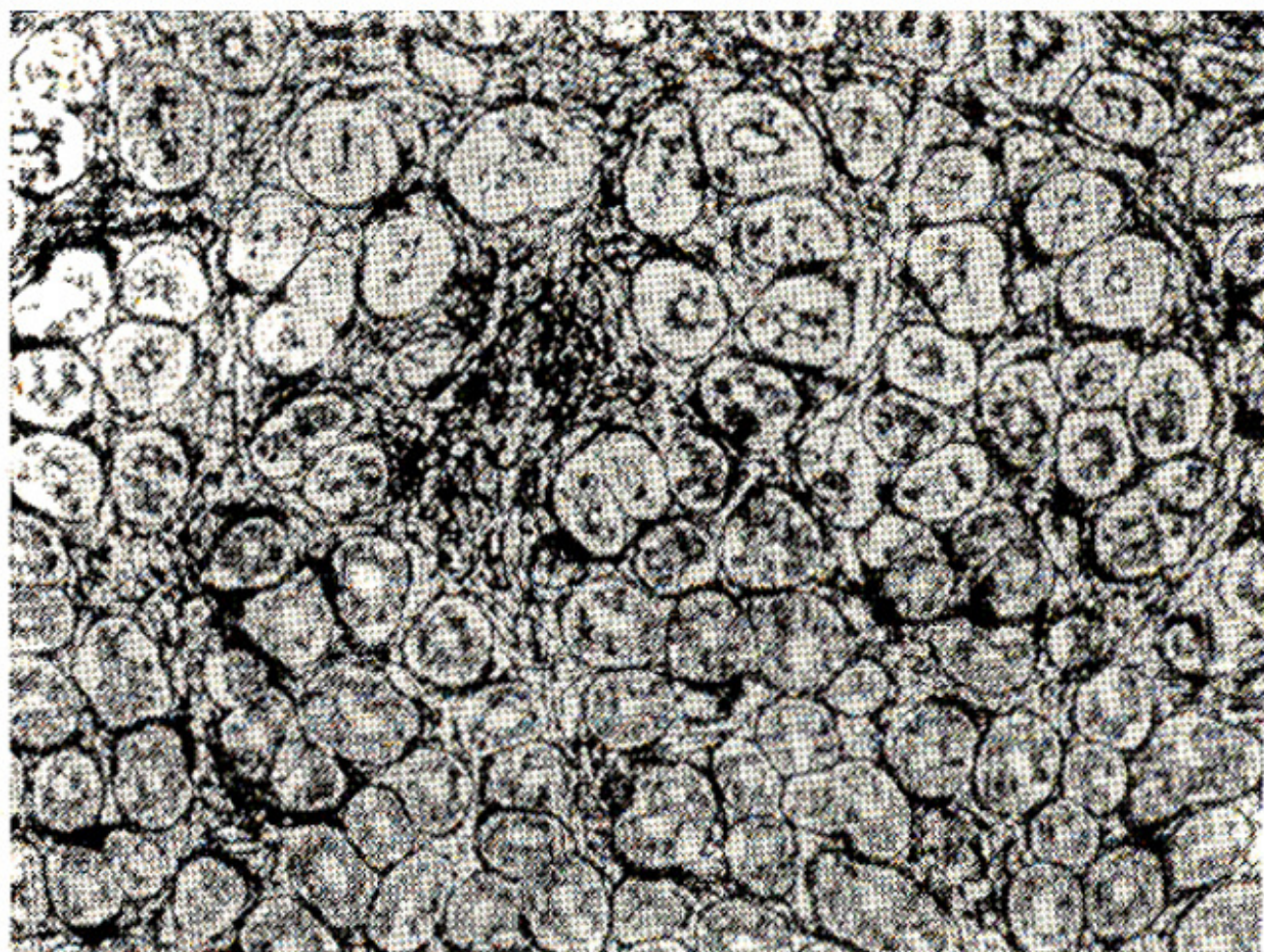
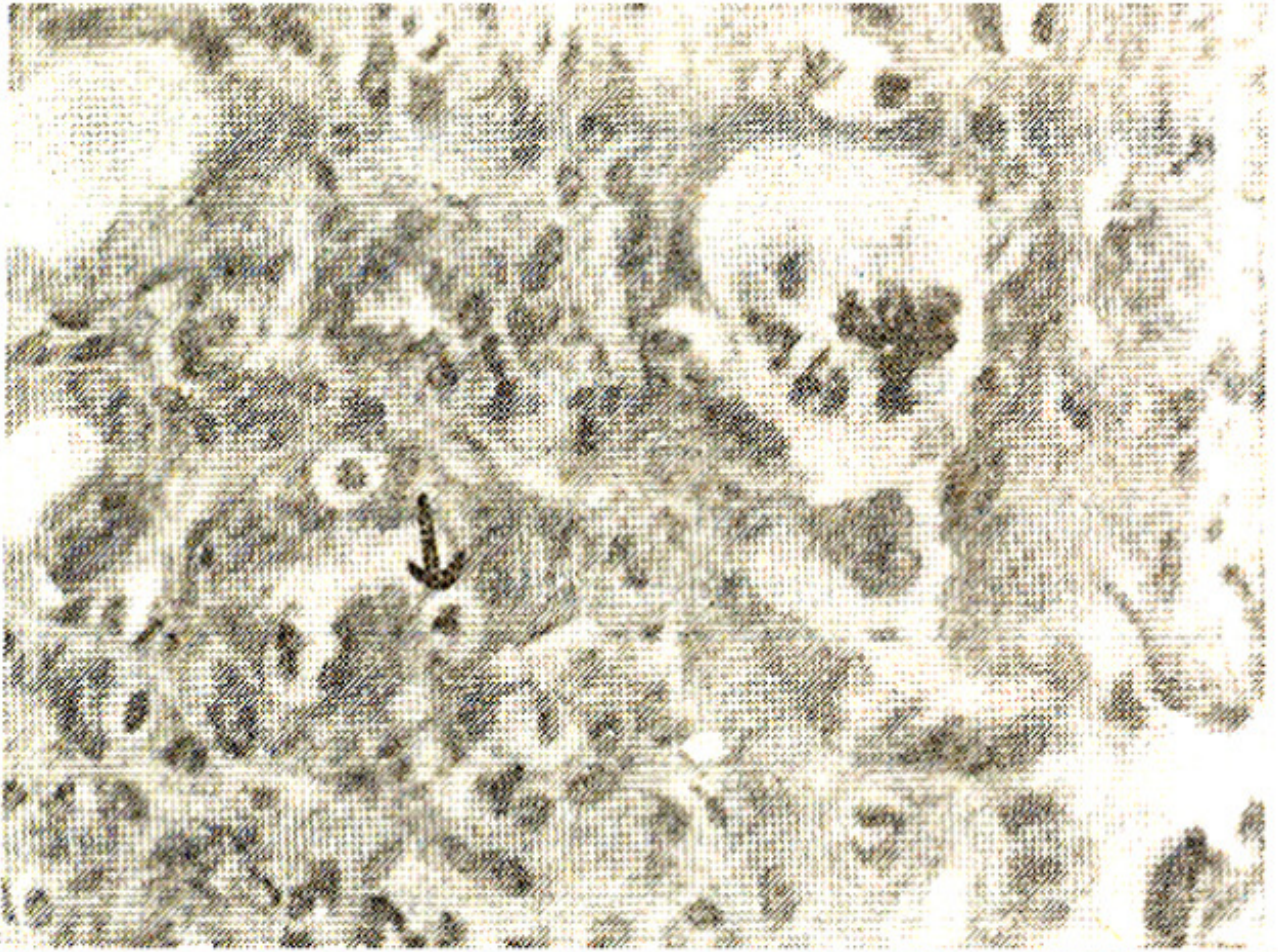
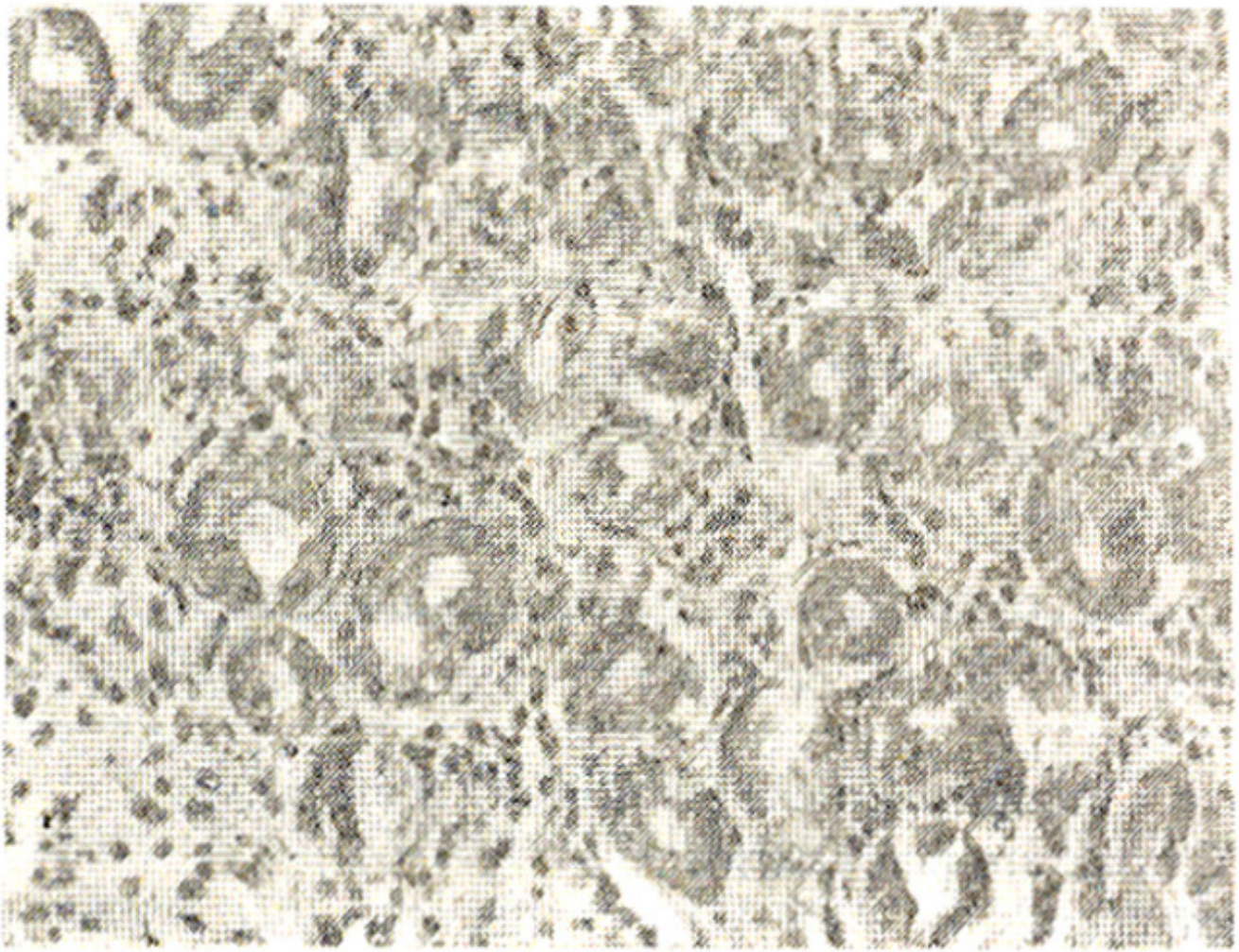


Figure 3. Atrophic gastritis. An area of gland drop out and deposition of increased reticulin. Reticulin stain x 175.



**Figure 4. Activity in superficial gastritis. Invasion of pit epithelium with polymorphs (arrow). Another pit shows collection of neutrophils in the lumen. H & Ex.**

was found in 44 patients (83.11%); while 2 patients showed acute gastritis (3.77%); (Figure 5).



**Figure 5. Acute gastritis showing glands separated by edematous stroma, haemorrhage and infiltration with polymorphs. H & E x 350.**

In one patient (1.8%) focal fibrosis was seen without any evidence of gastritis. Regarding; the type of chronic gastritis, chronic superficial gastritis with acute activity was found to be the commonest lesion (30.18%) as shown in table I. In 42 patients, antral gastritis was seen either alone or along with gastritis at the other sites. In only 5 patients, the antrum showed no change in the presence of gastritis elsewhere in the stomach. The distribution of histological lesions in relation to the NSAIDs used is shown in table I.

**Table I: Distribution of histological lesions according to intake of different NSAIDs.**

Drugs	Stomach						Duodenum					Total
	NSC	Ac.G	CSG AA	CSG	CAG AA	CAG	FF	NSC	Duodenitis			
									Mild	Mode- Severe rate		
Aspirin	1	-	2	-	2	-	-	1	2	1	1	5
Ibuprofen	2	1	1	4	3	4	-	2	8	4	-	15
Indomethacin	1	-	3	3	3	1	1	1	7	2	2	12
Diclofenac	-	-	4	-	-	1	-	1	2	1	1	5
Naproxen	-	-	1	2	2	-	-	-	2	2	-	5
Mefenamic acid	1	-	1	-	-	1	-	-	2	1	-	3
Piroxicam	-	-	-	-	-	1	-	-	1	-	-	1
Aspirin and ibuprofen	-	-	3	-	-	-	-	-	2	1	-	3
Aspirin and indomethacin	1	-	-	-	-	-	-	-	1	-	-	1
Ibuprofen and Indomethacin	-	1	-	-	-	-	-	-	1	-	-	1
Ibuprofen and Naproxen	-	-	1	-	-	-	-	-	-	1	-	1
Indomethacin and Naproxen	-	-	1	-	-	-	-	-	-	1	-	1
<b>Total:</b>	<b>6</b>	<b>2</b>	<b>16</b>	<b>10</b>	<b>10</b>	<b>8</b>	<b>1</b>	<b>5</b>	<b>28</b>	<b>15</b>	<b>4</b>	<b>53</b>

NSC = No significant change

Ac.G = Acute gastritis.

CSG = Chronic superficial gastritis.

CAG, AA = Chronic atrophic gastritis with acute activity.

CSG,AA = Chronic superficial gastritis with acute activity

CAG = Chronic atrophic gastritis.

FF = Focal fibrosis.

In the duodenum, no significant change was found in 5 patients (9.62%), while 47 patients (90.38%) showed duodenitis. Mild duodenitis was the commonest histological lesion, and was found in 28 patients (53.84%). Significant glandular changes were found in 45 out of 86 biopsies with duodenitis (Table II).

**Table II: Frequency of Blocked glands in relation to severity of Duodenitis in 97 duodenal biopsies.**

	No significant change	Duodenitis			Total
		Mild	Moderate	Severe	
<b>Blocked glands</b>	-	37	7	1	45
<b>No blocked glands</b>	11	30	8	3	52
<b>Total:</b>	<b>11</b>	<b>67</b>	<b>15</b>	<b>4</b>	<b>97</b>

The intestinal glands (crypts of Lieberkuhn) became dilated, circular or oval in outline. The lining cells

became cuboidal with loss of columnar and goblet cells and the lumen became distended with mucus similar in appearance to that of Brunner's glands (Figure 6-7).

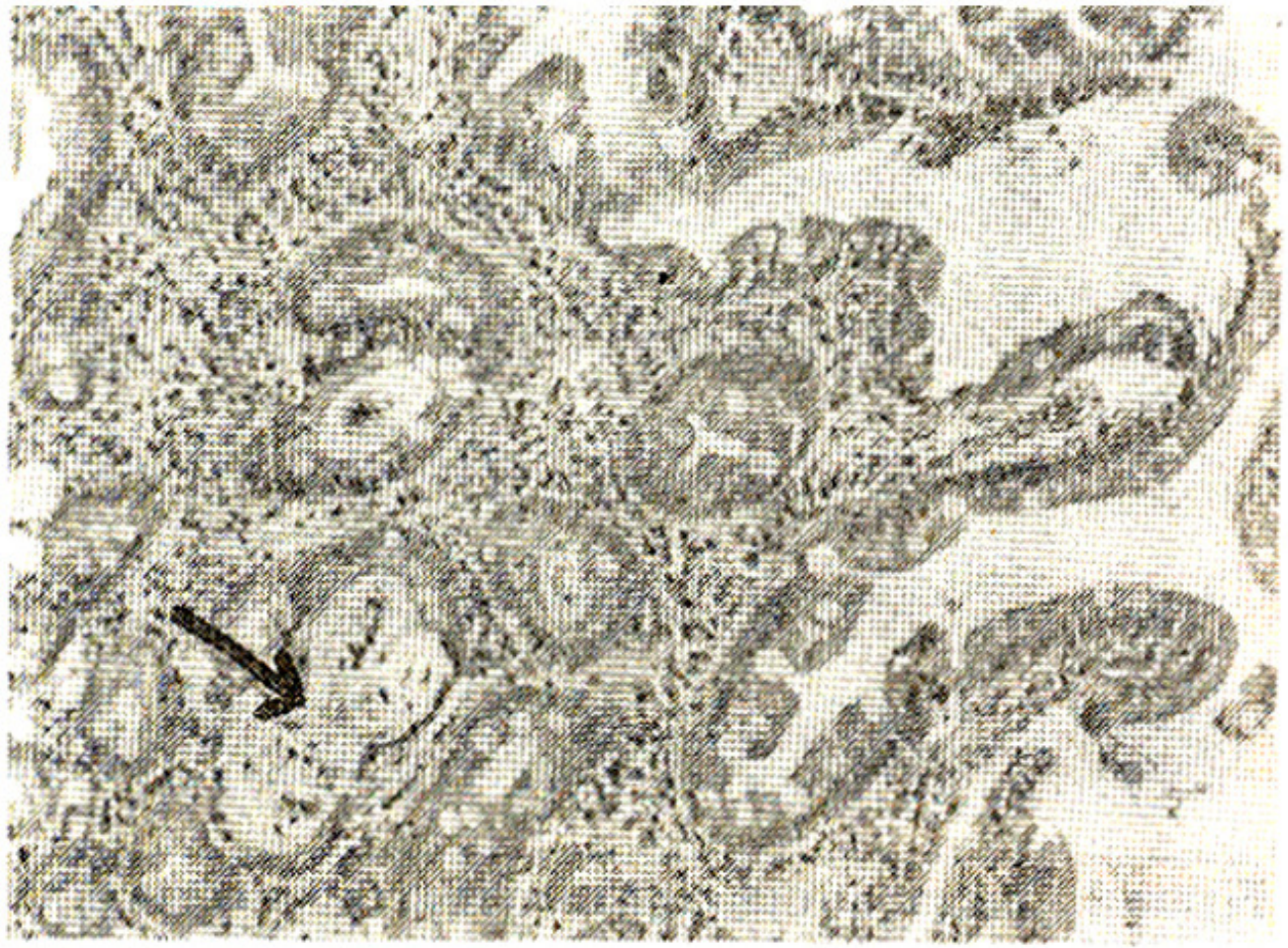
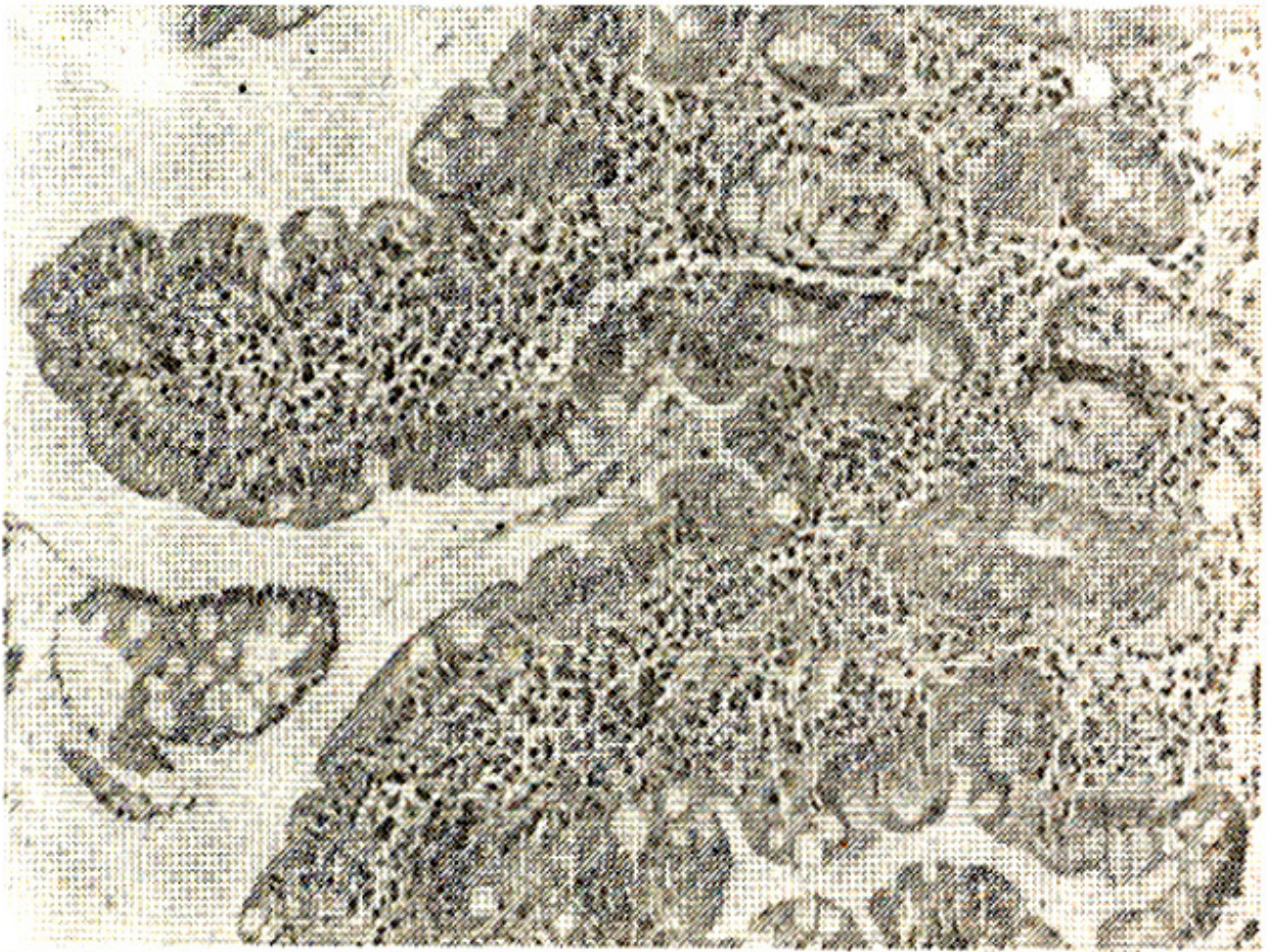


Figure 6. Duodenal mucosa showing distended intestinal glands plugged with mucous (arrow) in a case of duodenitis.  
H & E x 175.



**Figure 7. Mild duodenitis showing intestinal glands plugged with mucous. H & E x 175.**

These blocked glands were interspersed between intestinal glands of normal appearance. In some cases, pools of mucus were seen outside the blocked glands in the lamina propria.

## **DISCUSSION**

In this study, the most frequent lesion in the stomach was chronic superficial gastritis (CSG) (49.04%). Acute gastritis was found in 3.7% patients. In other studies, McIntyre et al. found acute gastritis in 22% patients on Sulindac;<sup>5</sup> and Lehtola and Sipponen reported acute erosive gastritis in 50% patients and chronic superficial gastritis in 33% patients taking diclofenac sodium and naproxen.<sup>4</sup> These differences may be explained on the basis of different NSAIDs, combinations, dosages and length of use. In our series ibuprofen was the commonest drug taken. The antral mucosa was the most frequent site involved in gastritis which is similar to the previously reported series.<sup>4,8,11</sup> Isaac et al. have described severe intestinal damage similar to coeliac disease induced by long term intake (years) of mefenamic acid. Three of our patients who had been on mefenamic acid showed no such change, but they had only taken the drug for a maximum of two weeks. The interesting findings in cases of duodenitis, consisting of dilated intestinal glands plugged with mucus have not been previously reported. Probable causes of this microscopic change may be: increased viscosity of mucus due to a change in its composition; blockage of outlet of crypts due to inflammation; production of excess mucous by

Brunner's glands which cannot be secreted as rapidly as it is produced; or a combination of these factors. It is concluded that NSAIDs intake for as short as a period of one week maybe associated with gastritis and duodenitis. Chronic superficial gastritis and mild duodenitis were the most frequently encountered lesions (Table I). The incidence and severity of the lesions may be related to specific NSAIDs, dosages and duration of use. Further comparative and controlled studies are needed to determine this.

## ACKNOWLEDGEMENTS

We are thankful to Dr. Sarwar Zuberi, Dr. Huma and Dr. Waqar of PMRC for taking endoscopic biopsies for this research.

## REFERENCES

1. Fromm, D. How do non steroidal anti-inflammatory drugs affect gastric mucosal defences? Clin. Invest. Med., 1987; 10:251.
2. Chcrnish, S.M., Rosenak, RD., Brunelle, R.L. and Crabhee, R. Comparison of gastrointestinal effects of aspirin and fenoprofen. Arthritis Rheum., 1979; 22:376.
3. Lanza, F.L., Royer, G.L. Jr., Nelson, R.S., Chen, T.T., Seckman, C.E. and Rack, M.F. A Comparative endoscopic evaluation of the damaging effects of nonsteroidal anti-inflammatory agents on the gastric and duodenal mucosa. Am. J. Gastroenterol., 1981; 75:17.
4. Lehtola, J. and Sipponen, P. A gastroscopic and histological double blind study of the effects of diclofenac sodium and naproxen on the human gastric mucosa. Sc-and. J. Gastroenterol., 1977; 97: 102.
5. McIntyre, R.L., Irani, M.S. and Piris,J. Histological study of the effects of three anti-inflammatorypreparations on the gastric mucosa. J. Clin. Pathol., 1981; 34:836.
6. Whitehead, R., Trulovc, S.C. and Gear, M.W.L. The histological diagnosis of chronic gastritis in fiberoptic gastroscope biopsy specimens. J. Clin. Pathol., 1972; 25:1.
7. Isaacs, P., Sladen, G.E. and Filipo, I. Mefenamic acid entropathy. J. Clin. Pathol., 1987; 40: 122.
8. Silvos, G.R., Ivey, K.J., Butt, J.iI., Lockard, O.O., Holt, S.D., Sisk, Baskin, W.N., Mackercher, P.A. and Hewett, 1979; 91:517.
9. Rees,W.D. and Turnberg, L.A. Reappraisal of the effects of aspirin on the stomach. Lancet, 1980; 2:410.
10. Hoftiezer,J.W., O'Laughlin, J.C. and Ivey, KJ. Effects of 24 hours of aspirin, bufferin, paracetamol and Placebo on normal human gastroduodenal mucosa. Gut, 1982; 23:692.