

## Role of Renal Arterial Resistive Index (RI) in obstructive uropathy

Aneela Azam,<sup>1</sup> Arfan-ul-Haq,<sup>2</sup> Mirza Amanullah Beg<sup>3</sup>

### Abstract

**Objective:** To determine the diagnostic accuracy of renal arterial resistive index on doppler ultrasound in patients with acute renal colic to diagnose obstructive uropathy taking non-enhanced helical computed tomography as the gold standard.

**Methods:** The descriptive study, conducted at the Radiology Department of Pakistan Naval Ship Shifa Hospital, Karachi, from October 10, 2010 to July 17, 2011, comprised 160 patients referred from the Emergency Department with complaint of unilateral renal colic. Ultrasound was carried out. Subsequently, computed tomography scan of kidney, ureter and bladder was performed. Data was collected on prescribed proforma and analysed using SPSS 19.

**Results:** By taking the resistive index value of  $> 0.70$  as a discriminatory level for obstruction, the overall sensitivity of the index was 76.23% and specificity was 88.13%. The positive predictive values of the index in patients with obstructive uropathy was 91.6%, and negative predictive value was calculated to be 68.42%. The diagnostic accuracy of the test was 80%.

**Conclusion:** Duplex Doppler ultrasound can detect acute renal obstruction with sensitivity of approximately 77%. However, ultrasound is an operator-dependent examination, and the results are much affected by patient body habitus.

**Keywords:** Renal colic, Doppler ultrasonography, Obstruction, Resistive index. (JPMA 63: 1511; 2013)

### Introduction

Urolithiasis is the most common urological ailment, and renal colic is among the most common problems met in urology practice.<sup>1</sup> Renal obstruction due to urolithiasis is the most frequent cause.<sup>2,3</sup> This disease is prevalent in our country and 12% of Pakistani population has urolithiasis.<sup>4</sup> A population-based study showed that overall prevalence of kidney stone in Iran is 5.7%, with slightly increased frequency in male 6.1%, while it was 5.3% in females.<sup>5</sup> Early and accurate diagnosis is essential to minimise the devastating effects of obstruction on urinary tract structure and function.<sup>6</sup> Though Intravenous Urography (IVU) is considered the standard investigation, it is not always available and an abdominal X-ray kidney, ureter, bladder (KUB) coupled with ultrasonography of the urinary tract is performed as an alternative method in many hospitals.<sup>2,7</sup>

Plain abdominal radiograph has very low sensitivity for the detection of urolithiasis.<sup>8</sup> Small calculi are usually obscured by bowel gases or faecal matter.<sup>8</sup> In addition, ribs, transverse process and sacrum may obscure the urinary tract calculi.<sup>8</sup> Usually ultrasound (US) is used to diagnose acute renal colic, but unfortunately it fails to

reveal hydronephrosis in acute obstruction of the kidney in 50% of the cases.<sup>6</sup> US has sensitivity of 37% for ureteral calculi (direct visualisation),<sup>9</sup> therefore, non-enhanced helical computed tomography (CT) has become the primary radiological study for the evaluation of urolithiasis and is used as the gold standard for urolithiasis.<sup>10</sup> CT has sensitivity of 95% and specificity of 98%.<sup>11</sup>

Because of high cost, radiation dose and high workload of CT,<sup>12</sup> US should be modified to enhance its diagnostic efficacy to detect obstructive uropathy and Doppler US can be used to overcome this problem. Renal arterial Resistive Index (RI) is most commonly used from among Doppler indices.<sup>13</sup> Doppler US can non-invasively provide useful information about renal haemodynamics and make diagnosis of obstructive uropathy more accurate. When the collecting system is acutely obstructed, the pressure of renal calyces increases with changes in renal blood flow resulting in increased RI (RI  $> 0.7$ ).<sup>2,7,14-16</sup> The RI sensitivity reported in literature is 75.5% and specificity 92.5%.<sup>3</sup>

Similar works has been done at international and national levels previously. Mean RI of obstructed kidney was found to be more than 0.7 by Geavlete et al,<sup>3</sup> Amin et al,<sup>17</sup> Ashraf et al,<sup>18</sup> Platt et al<sup>19</sup> and De Toledo<sup>20</sup> et al. Sauvian et al<sup>21</sup> found it to be 0.7, whereas Hyder et al,<sup>22</sup> Onur et al<sup>1</sup> and Skokeir et al<sup>23</sup> found it to be below 0.7. Sensitivity and specificity of mean RI of more than 0.7 was also calculated by various researchers (Table-1). Platt et al reported RI of

.....  
Department of Radiology, <sup>1</sup>Dow University of Health Sciences, <sup>2</sup>P.N.S. Shifa, <sup>3</sup>The Aga Khan University Hospital, Karachi, Pakistan.

**Correspondence:** Mirza Amanullah Beg. Email: mirza.beg@aku.edu

0.70 to be a good discriminatory level for obstruction with accuracy of 90%.<sup>19</sup>

The aim of the current study was to determine the sensitivity of RI in diagnosis of renal obstruction and to see whether CT scan can be replaced by Doppler US, especially in patients with recurrent renal calculi, paediatric and pregnant patients in view of reducing radiation dose to such patients.

### Patients and Methods

After taking approval from institutional review board and ethics committee, the descriptive study was conducted at the Department of Radiology, PNS Shifa, Karachi, between October 10, 2010 to July 17, 2011. Taking alpha at 5%, power 80%, sensitivity as 92% and specificity of 88% a minimum of 160 patients were required as the sample size.

During the study period, 160 patients referred by the Emergency Department with complaint of unilateral renal colic were enrolled, US was carried out. Subsequently, CT KUB, which was taken as the gold standard,<sup>6,12</sup> was performed. The sampling technique was non-probability, purposive sampling.

Patients of either gender, between 15-50 years of age, who gave informed consent for the study and had unilateral colic, were included. Informed consent from the guardian of patients under 18 years of age was also taken. Those excluded were: children under 15 years of age (because of CT radiation risks), patients older than 50 years (because of increased risk of atherosclerosis that affects Doppler findings), patients having bilateral flank pain, pregnant patients, patients with known renal disease, known case of urolithiasis, patients having solitary kidney, and transplanted kidney.

All patients were examined by single machine Nemio-18 with a curvilinear transducer of 3.5-5 MHz. Doppler waveforms were recorded from interlobar and arcuate arteries at the upper, middle and lower portions first over the obstructed then over the contra lateral kidney. The lowest possible pulse repetition frequency without aliasing and the highest possible gain were used. The Doppler sample width was set at 2-5mm. The renal RI was calculated by subtracting the peak diastolic velocity from the peak systolic velocity and dividing the result by the peak systolic velocity. A renal RI >0.7 was considered diagnostic of obstructive uropathy.

All patients subsequently underwent unenhanced CT KUB examination on the same day within 12 hours of the US examination. Scanning was done on Toshiba Aquillion 16 CT Scanner. A subject was considered negative when no

ureteric calculus was seen, and was considered positive when a hyperdense ureteric calculus was noted. CT scan results were considered the gold standard with which Doppler sonography findings were compared. Data was initially collected on a proforma which was then shifted to SPSS 19. Descriptive statistics were expressed as mean  $\pm$  standard deviation for continuous variables like age, while frequency and percentage were calculated for categorical variables like gender, side of renal colic and presence of ureteric calculus. Age and gender-wise stratification was done to control effect modulation

After analysing the data, sensitivity, specificity, negative and positive predictive values (NPV and PPV) and accuracy of Doppler US for obstructive uropathy was calculated by corresponding with CT KUB examination using 2/2 table.

RI was measured using following formula and taking mean RI of upper, middle and lower segments of kidney; [RI = (peak systolic velocity - end diastolic velocity)/peak systolic velocity]. RI more than 0.7 was taken as indicator of obstructive uropathy.

CT was taken as positive if there was calculus in the ureter.

True Positive was defined as obstructive uropathy diagnosed on Doppler US and also found on CT KUB.

True Negative was defined as obstructive uropathy not diagnosed on Doppler US and also not found on CT KUB.

Obstructive uropathy diagnosed on Doppler US, but not found on CT KUB was taken as False Positive, while obstructive uropathy not diagnosed on Doppler US, but found on CT KUB was defined as False Negative.

Sensitivity was equal to: True Positive/True Positive + False Negative  $\times$  100; while Specificity was equal to: True Negative/False Positive + True Negative  $\times$  100.

True Positive / True Positive + False Positive  $\times$  100, and NPV as, True Negative / False Negative + True Negative  $\times$  100. The Diagnostic Accuracy was calculated by the formula: True Positive + True Negative / True Positive + False Positive + False Negative + True Negative  $\times$  100.

### Results

Overall, the mean age of the 160 patients was 34 $\pm$ 8.5 years (range: 16-50 years). There were 103 (64.4%) males and 57 (35.6%) females. Of the total, 91 patients presented with right-sided pain and 69 with left-sided pain. Calculi were noted predominantly on the right side (n=71; 70.2%), while 30 (29.8%) had them on the left side. Ureteric calculus was noted on CT scan in 101 (63.1%) patients, and it was not present in 59(36.8%) (Table-2). Of

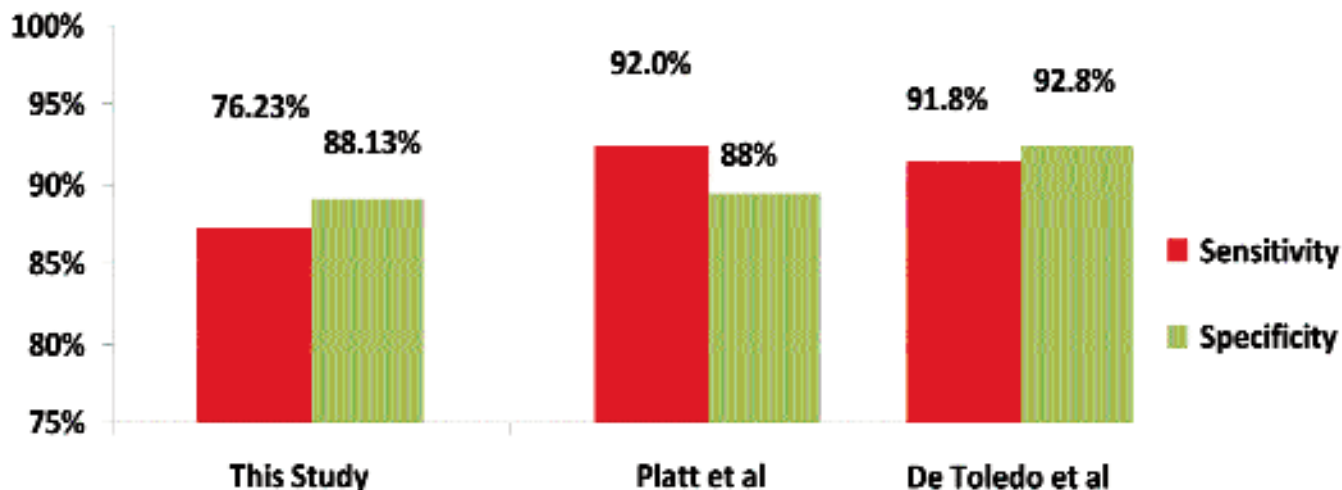


Figure: Comparison of the current study with others.

Table-1: Mean RI along with sensitivity and specificity of RI more than 0.7 of obstructed kidney in literature review.

	RI	Sensitivity	Specificity
Geavlete et al <sup>3</sup>	0.76	75.5%	92.5%
Ashraf et al <sup>18</sup>	>0.70	87.5%	85%
Platt et al <sup>19</sup>	>0.70	92%	88%
De Toledo et al <sup>20</sup>	>0.70	91.8%	92.8%
Amin et al <sup>17</sup>	0.77		
Hyder et al <sup>22</sup>	0.69		
Onur et al <sup>1</sup>	0.69		
Skokeir et al <sup>23</sup>	0.69		
Sauvian et al <sup>21</sup>	0.70		

RI: Resistive Index.

the 103 male patients, calculus was found in 64 (62.1%) patients and of the 57 female patients, ureteric calculus was identified in 37 (64.9%).

RI was found to be >0.70 in 84(52.2%) patients. Calculus was seen on CT scan in 77 (91.6%) of these 84 patients, so these patients were True Positive and constituted 48.1% of the total sample. In the remaining 7 (8.3%) of these 84 patients, calculus was not seen on CT scan. These False Positive patients constituted 4.3% of the total sample.

RI was found to be >0.70 in 76 (47.5%) of the 160 patients. Ureteric calculus was seen on CT scan in 24 (31.5%) of these patients, who were False Negative and constituted 15% of the total sample. In 52 (68.4%) of these 76 patients, ureteric calculus was not seen on CT scan, so they were True Negative and constituted 32.5% of the total sample. Other causes of loin pain seen on CT scan were appendicitis in 17 (10.6%) patients, diverticulitis in 14

Table-2: 2 x 2 table of study.

RI of affected kidney on duplex Doppler ultra sound	Ureteric calculus seen on CT KUB	Ureteric calculus not seen on CT KUB
> 0.7	77 patients (TP)	7 patients (FP)
≤ 0.7	24 patients (FN)	52 patients (TN)

RI: Resistive Index. CT KUB: Computed Tomography of Kidney, Ureter and Bladder. TP: True Positive. FP: False Positive. TN: True Negative. FN: False Negative.

(8.75%), spondylolysis in 8 (5%), while no cause of pain was seen in 13 (8.12%).

By taking RI value of > 0.70 as a discriminatory level for obstruction, the overall sensitivity of RI was 76.23% and specificity was 88.13%. The PPV of RI was 91.6% and NPV was 68.42%. The diagnostic accuracy of the test was 80%.

### Discussion

CT KUB and gray-scale sonography have been the two most common imaging modalities used in patients with acute renal colic to detect calculi and obstruction.<sup>6,7</sup> Although gray-scale US of kidneys can reliably identify collecting system dilatation, it is often not possible to differentiate between obstructive and non-obstructive causes on gray-scale sonography alone. As prolonged renal obstruction induces hormonal alterations and thereby causes diffused vasoconstriction of the vascular bed, the visualisation of different patterns of blood flow is helpful in differentiating the obstructive from the non-obstructive pyelocaliectasis.<sup>1,2,6</sup> The availability of duplex Doppler sonography is apparently an attractive and well-reproducible adjunct to the partly invasive diagnostic procedures commonly used in the radiological assessment of renal obstruction.<sup>21</sup>

In the past two decades, previous investigators have reported somewhat conflicting results regarding the additional information from duplex Doppler sonography over grey-scale sonography, allowing the diagnosis of acute urinary tract obstruction.<sup>3,6</sup> Many researchers have reported an elevated RI in the setting of acute ureteric obstruction.<sup>1,6</sup> Various mean RI values have been reported in obstructed kidneys (Table-1). Our study is comparable with works of Geavlete et al,<sup>3</sup> Amin et al,<sup>17</sup> Ashraf et al,<sup>18</sup> Platt et al<sup>19</sup> and De Toledo et al<sup>20</sup> who found mean RI of above 0.70 in obstructed kidneys. Elevated RI of more than 0.7 was found to be 76.23% sensitive and 88.13% specific in this study which is also comparable with the results of previous studies using RI of more than 0.70 as indicator of obstructed kidney due to ureteric calculus (Table-1, Figure).

In this study we found that disease was most common between age group of 36-45 years which is comparable with an earlier study.<sup>6</sup>

Our study showed that males were more prone to develop acute renal obstruction due to urolithiasis with 64.4% of patients being males and 35.6% patients being females. It is comparable with a study<sup>20</sup> which had 70.4% and 29.6% female patients.

In 24 patients of the study, there was RI of  $\leq 0.70$ . However, ureteric calculus was found on CT scans. These were False Negative sample of our study and could be attributable to the early presentation of the patients to the hospital just after the onset of symptoms. This has been studied earlier<sup>22</sup> and reported that RI was significantly higher in patients with renal colic of duration of  $>24$  hours. This could also be secondary to the effects of non-steroidal anti-inflammatory drugs (NSAIDs) used for the pain management in patients with obstructive uropathy. These medications have been found to reverse vasoconstriction that occurs with acute renal obstruction. A study found that sensitivity of RI decreases from 70% to 50%, 6 hours after the ingestion of 75mg diclofenac.<sup>23</sup> The time-dependence and use of NSAIDs were factors not part of this study, so their effects cannot be defined.

In 7 patients of our study sample, RI was found to be  $>0.70$ . However, ureteric calculus was not seen on CT scan. Several studies have demonstrated that RI is affected by other factors such as vascular compliance, age of the patient, plasma rennin levels,<sup>23</sup> diabetes, hypertension, abnormal heart rates and several other renal diseases. These other factors can explain the elevation of RI without renal obstruction.

Fifty two patients of the study had symptoms of obstructive uropathy, but their RI was  $\leq 0.70$  and no calculus was seen on

CT scan. In these patients, other causes of pain were seen on CT scan. The CT has superiority over other modalities as it helps to reach an answer to the patient's clinical condition. Many mimickers of renal colic have been reported in such patients which include appendicitis, diverticulitis, bowel obstruction or herniation, intra-abdominal fluid collections (abscess/haematoma), tubo-ovarian abscess, aortic aneurysms, pancreatitis and neoplasms.<sup>9</sup>

A possible limitation of this study was that it did not include other causes of raised RI, such as hypertension and diabetes. Time-dependence and NSAID-dependence factors of RI could also not be taken into account. These factors need to be further evaluated in future researches so their effects on RI could be completely understood.

## Conclusion

Gray-scale sonography should be complemented by Doppler US as an adjunctive test in patients presenting with acute renal colic. However, US is an operator-dependent examination and the results are much affected by patient body habitus. As such, it cannot replace CT examination for definitive diagnosis of ureteric calculus, but in special cases where ionising radiations are undesirable, such as in pregnant patients or patients of paediatric age group, Doppler US can be used to reach some conclusion.

## References

1. Onur MR, Cubuk M, Andic C, Kartal M, Arslan G. Role of resistive index in renal colic. *Urol Res.* 2007; 35: 307-12.
2. Pepe P, Motta L, Pennisi M, Aragona F. Functional evaluation of the urinary tract by color-Doppler ultrasonography (CDU) in 100 patients with renal colic. *Eur J Radiol* 2005; 53: 131-5.
3. Geavlete P, Georgescu D, Cauni V, Nita G. Value of duplex doppler ultrasonography in renal colic. *Eur Urol* 2002; 41: 71-8.
4. Rahman A, Danish KF, Zafar A, Ahmad A, Chaudhry ARS. Chemical composition of non-infected upper urinary tract calculi. *Rawal Med J* 2008; 33: 54-5.
5. Safarinejad MR. Adult urolithiasis in a population based study in Iran; prevalence, incidence and associated risk factors. *Urol Res* 2007; 35: 73-82.
6. Haroun A. Duplex Doppler sonography in patients with acute renal colic: prospective study and literature review. *Int Urol Nephrol* 2003; 35: 135-40.
7. Gurel S, Akata D, Gurel K, Ozmen MN, Akhan O. Correlation between the renal resistive index (RI) and nonenhanced computed tomography in acute renal colic: how reliable is the RI in distinguishing obstruction? *J Ultrasound Med* 2006; 25: 1113-20.
8. Gottlieb RH, La TC, Erturk EN, Sotack JL, Voci SL, Holloway RG, et al. CT in detecting urinary tract calculi: influence on patient imaging and clinical outcomes. *Radiology* 2002; 225: 441-9.
9. Tamm EP, Silverman PM, Shuman WP. Evaluation of the patient with flank pain and possible ureteral calculus. *Radiology* 2003; 228: 319-29.
10. Sharma A. Unenhanced helical CT in renal colic. *Internet J Radiol* 2005; 4. doi: 10.5580/ebf
11. Rucker CM, Menias CO, Bhalla S. Mimics of renal colic: alternative diagnoses at unenhanced helical CT. *Radiographics* 2004; 24

- (Suppl 1): S11-S28.
12. Patlas M, Farkas A, Fisher D, Zaghal I, Hadas-Halpern I. Ultrasound vs CT for the detection of ureteric stones in patients with renal colic. *Br J Radiol* 2001; 74: 901-4.
  13. Kim SH. The usefulness of pulsatile flow detection in measuring resistive index in renal doppler US. *Korean J Radiol* 2002; 3: 45-8.
  14. Tseng FF, Bih LI, Tsai SJ, Huang YH, Wu YT, Chen YZ. Application of renal Doppler sonography in the diagnosis of obstructive uropathy in patients with spinal cord injury. *Arch Phys Med Rehabil* 2004 ; 85: 1509-12.
  15. Dwivedi US, Bishoyi SC, Shukla RC, Singh PB, Pal DK. Renal resistive index: differentiation of obstructive from nonobstructive hydronephrosis. *Ind J Urol*. 1998; 14: 17-21.
  16. Dubbins PA. The kidney. In: Allan PA, Dubbins PA, Pozniak MA, Mc Dickens WN (eds.). *Clinical Doppler Ultrasound*. 2nd edition. Edinburg: Churchill Livingstone; 2005; pp 169-201.
  17. Amin MU, Ghaffar A. Intrarenal and intravesical color Doppler sonography in patients with acute renal colic. *J Surg Pakistan* 2004; 9: 40-2.
  18. Ashraf Z, Mansoor T, Ashai M, Ahmad I, Lateef W. Duplex Doppler ultrasonography: an excellent initial investigation in obstructive uropathy. *The Internet Journal of Surgery*. 2009; 20: 11.
  19. Platt JF, Rubin JM, Ellis JH, DiPietro MA. Duplex Doppler US of the kidney; differentiation of obstructive from nonobstructive dilatation. *Radiology* 1989; 171: 515-7.
  20. deToledo LS, Martinez-Berganza AT, Cozcolluela CR, de Gregorio Ariza MA, Cortina PP, Saldias LR. Doppler-duplex ultrasound in renal colic. *Eur J Radiol* 1996 ; 23: 143-8.
  21. Sauvain JL, Pierrat V, Chambers R, Bui Xuan P, Palascak P, Boursheid D, et al.[ Echography and pulsed Doppler of the arteries of the renal parenchyma in obstructive syndromes and dilatation of the excretory cavities of the kidney]. *J Radiol* 1989; 70: 389-98.
  22. Hyder RR, Khan Y, Umar M, Aziz T, Saeed M. The usefulness of inter-renal resistive index difference in diagnosing acute unilateral ureteric obstruction due to calculus. *Pak Armed Forces Med J* 2009; 59: 211-6.
  23. Shokeir AA, Mahran MR, Abdulmaaboud M. Renal colic in pregnant women: role of renal resistive index. *Urology* 2000; 55: 344-7.
-