

LYMPHOMA COMPLICATING ULCERATIVE COLITIS

Pages with reference to book, From 37 To 39

Syed Hasnain Ali Shah, Abdul Haleem Khan, Ashfaqe Ahmed (Departments of Medicine, The Aga Khan University Hospital, Karachi.)

Hizbullah Shaikh (Departments of Pathology, The Aga Khan University Hospital, Karachi.)

Carcinoma of large bowel is a relatively common complication of ulcerative colitis, whereas lymphoma is rare. We report two cases with along history of ulcerative colitis complicated by Non- Hodgkin's lymphoma of the colon.

CASE 1

S.N., a 28 year old housewife presented to the Aga Khan University Hospital with increasing abdominal distension, pain and fever for 7 days. She had also noticed a vague mass in the left iliac fossa over the past one month prior to admission. She had ulcerative colitis for the past 10 years. Colonoscopy and biopsies done on a number of occasions demonstrated gross and histological features of ulcerative colitis. She had taken corticosteroids and mesalazine with partial benefit only. On examination she looked very unwell, cachectic and toxic. She was pale with no sign of jaundice or lymphadenopathy. Abdominal examination revealed ascites with vague mass in the left iliac fossa. Her haemoglobin was 9.1 mg%, white cell count $11.6 \times 10^9/l$, platelets $122 \times 10^9/l$, ESR 8 mm/hr. BUN, serum creatinine were normal. Colonoscopy showed globular masses in sigmoid colon which were biopsied. Histology revealed features of ulcerative colitis and Non-Hodgkin's lymphoma (Figure 1 and 2).

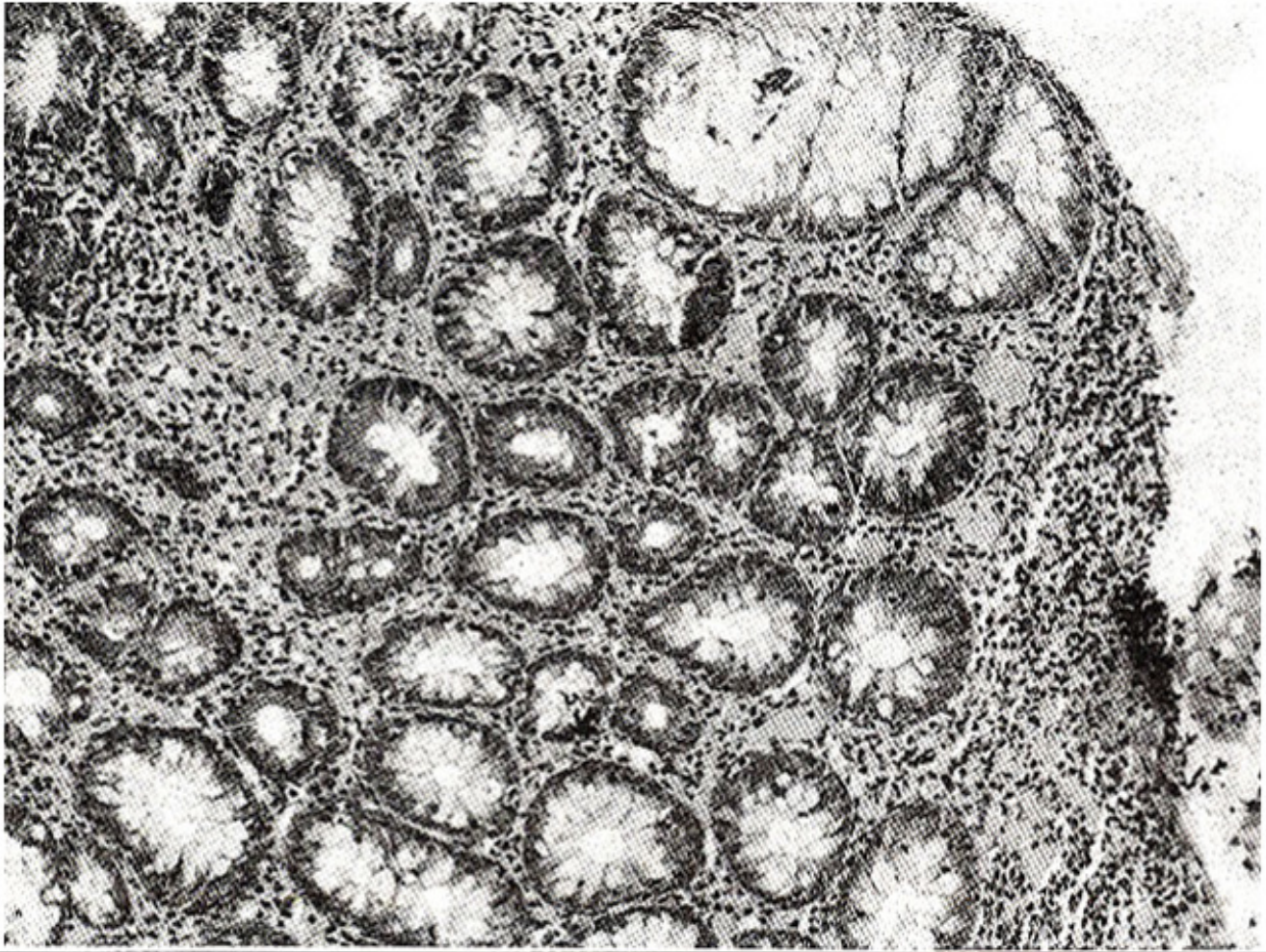


Figure 1. Ulcerative proctitis - rectal mucosa showing crypt branching and focal mucin depletion (H&E x 200).

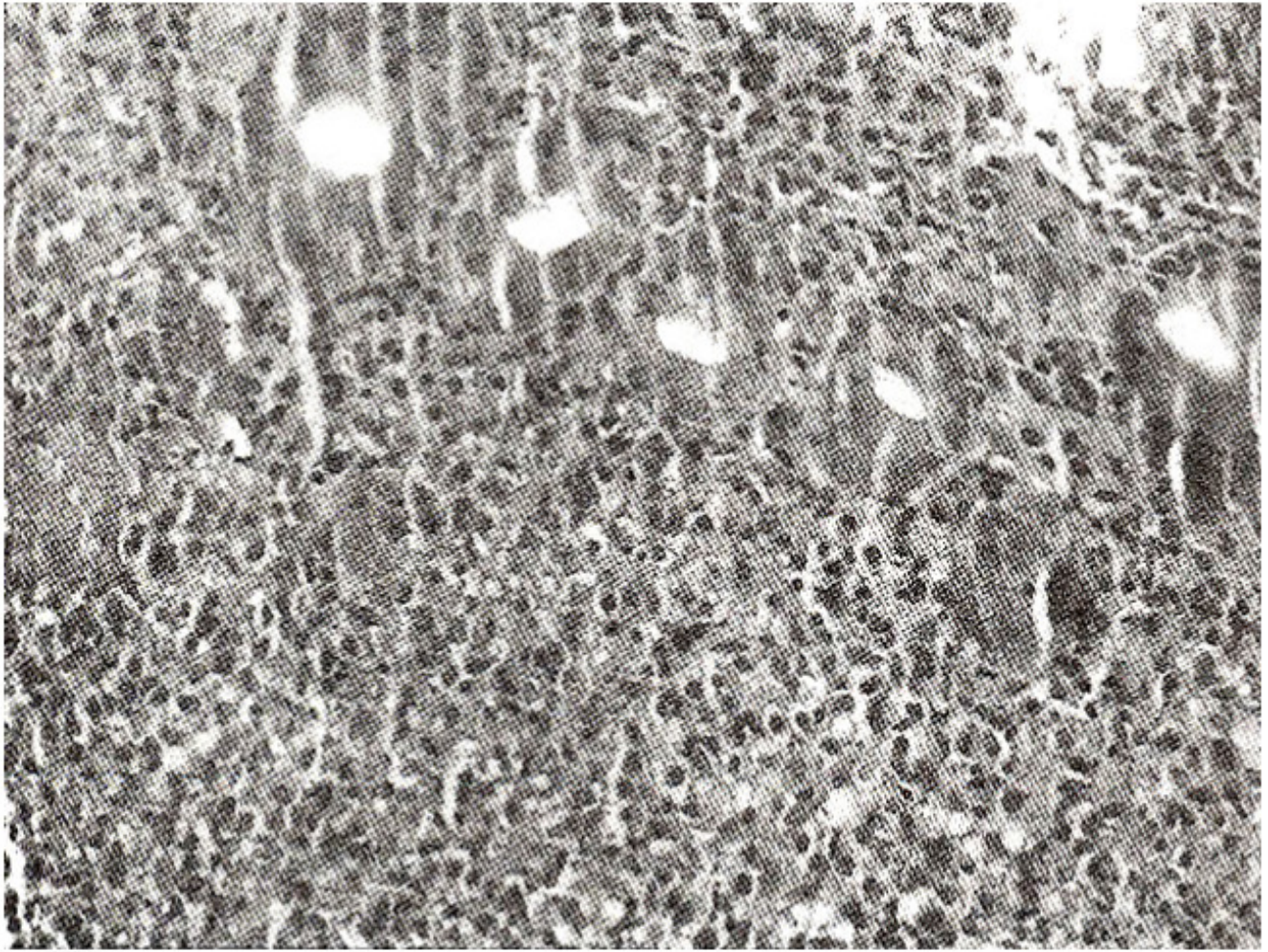


Figure 2. Lymphoma rectum - lymphoma cell infiltration in the lamina propria (H&E x 100).

Her ascites worsened and paracentesis of ascitic fluid confirmed lymphoma cells in the ascitic fluid. She developed bacterial infection and despite antibiotic therapy she died. A post mortem biopsy of left iliac fossa mass confirmed the presence of lymphoma of gut infiltrating into the surrounding tissues (Figure 3).

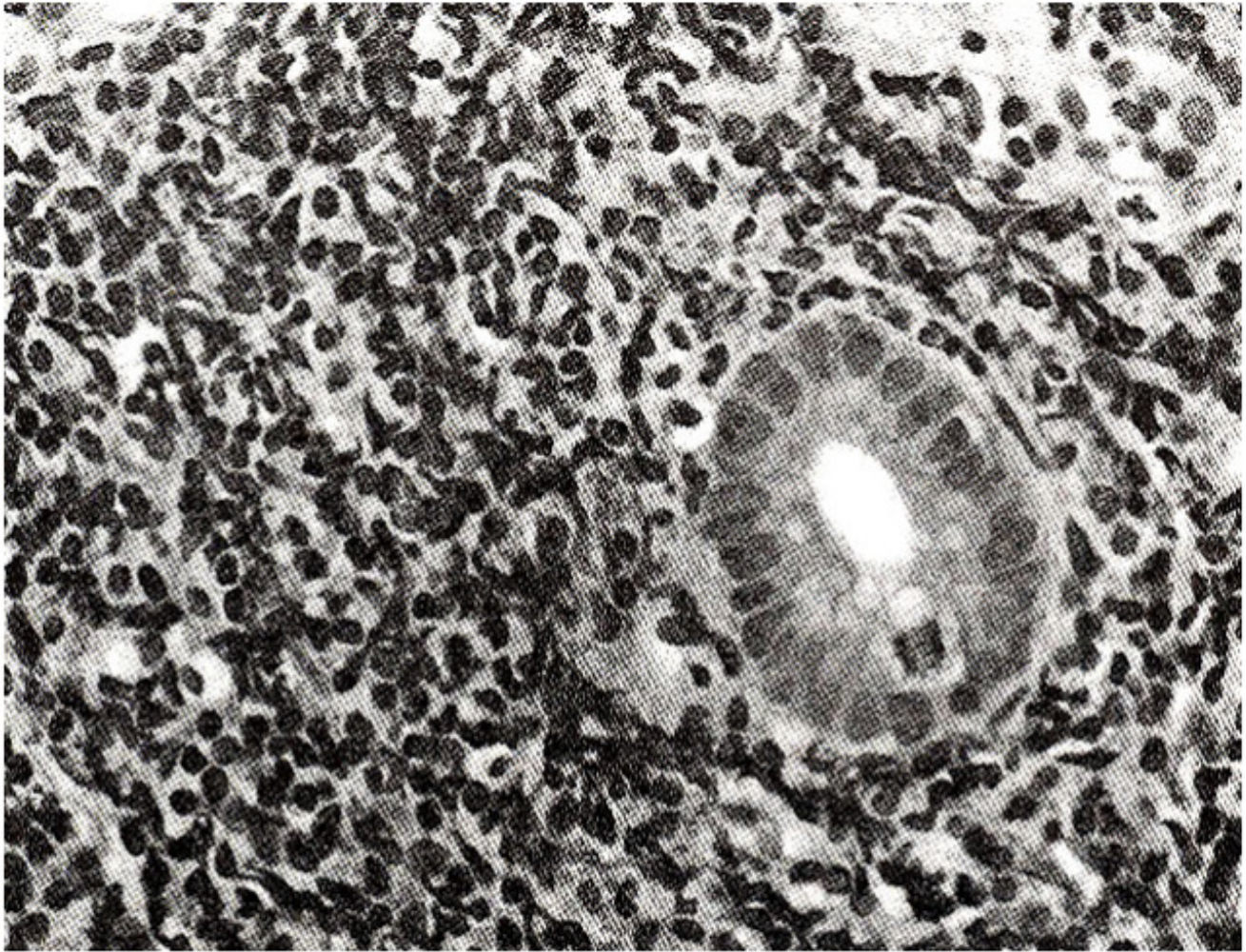


Figure 3. Lymphoma rectum - lymphoma cells in the lamina propria with paucity of the crypts (H&E x 400).

CASE 2

ASA, a 70 year old male, presented to the Aga than University Hospital with four and half months history of passage of loose stools with mucus but no blood. There were accompanying periumbilical and left iliac fossa pains. There was no history of weight loss, malaise, fever or arthralgias. Past medical history and personal history were unremarkable. On examination he was pale without jaundice or lymphadenopathy. Cardiovascular and chest examination were unremarkable. The abdomen was soft, non-tender with no visceromegaly. Mobile masses which were firm and non-tender were palpable. Air contrast barium enema showed multiple ulcerations in descending and sigmoid colon with narrowing at the rectosigmoid junction. Flexible sigmoidoscopy was done and biopsies taken showed features of ulcerative proctitis with lymphomatous involvement (Figures 4, 5,6).

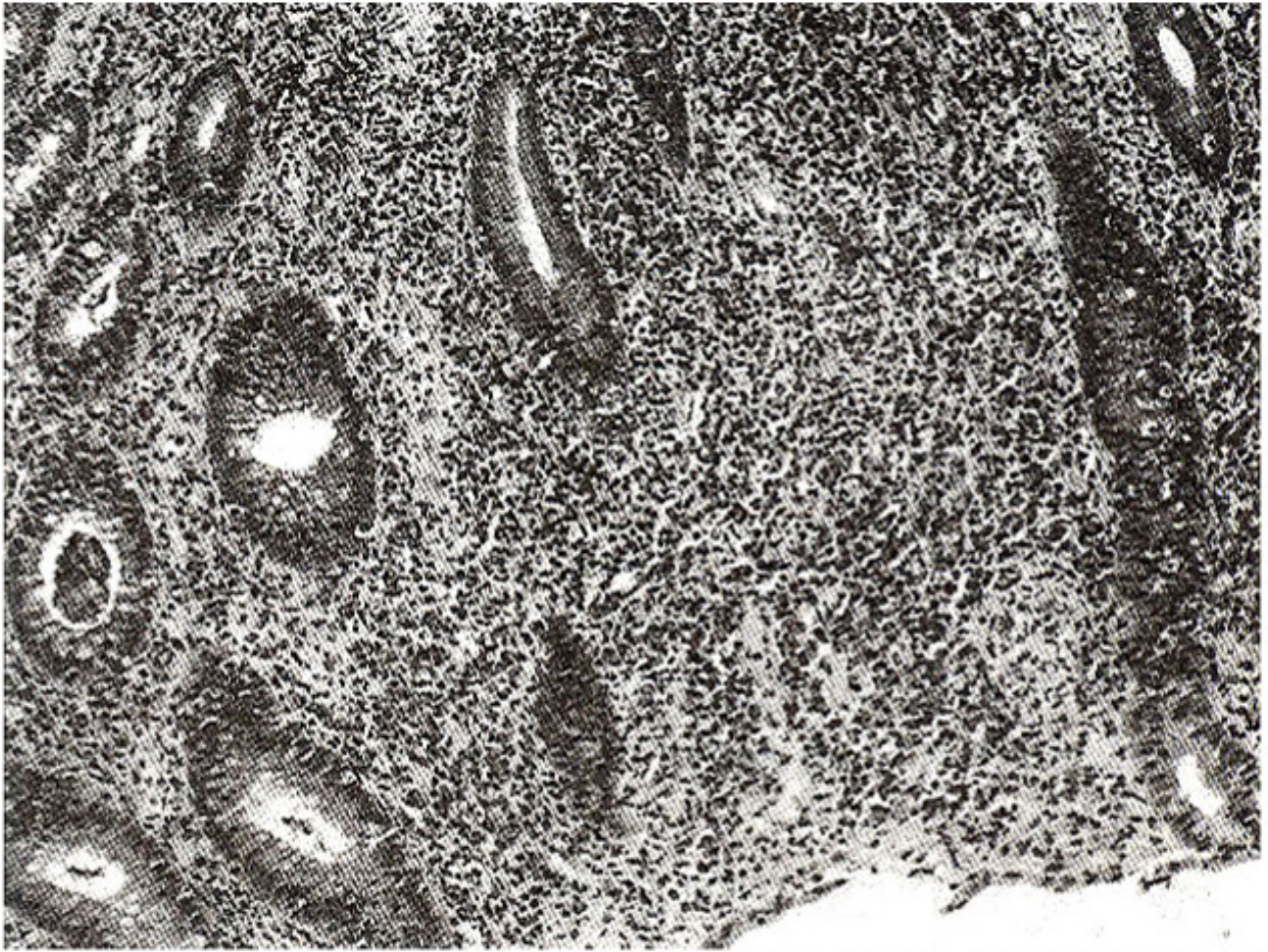


Figure 4. Ulcerative proctitis - crypt hyperplasia, distortion, mucin depletion with inflammation in the lamina propria (H&E x 200).

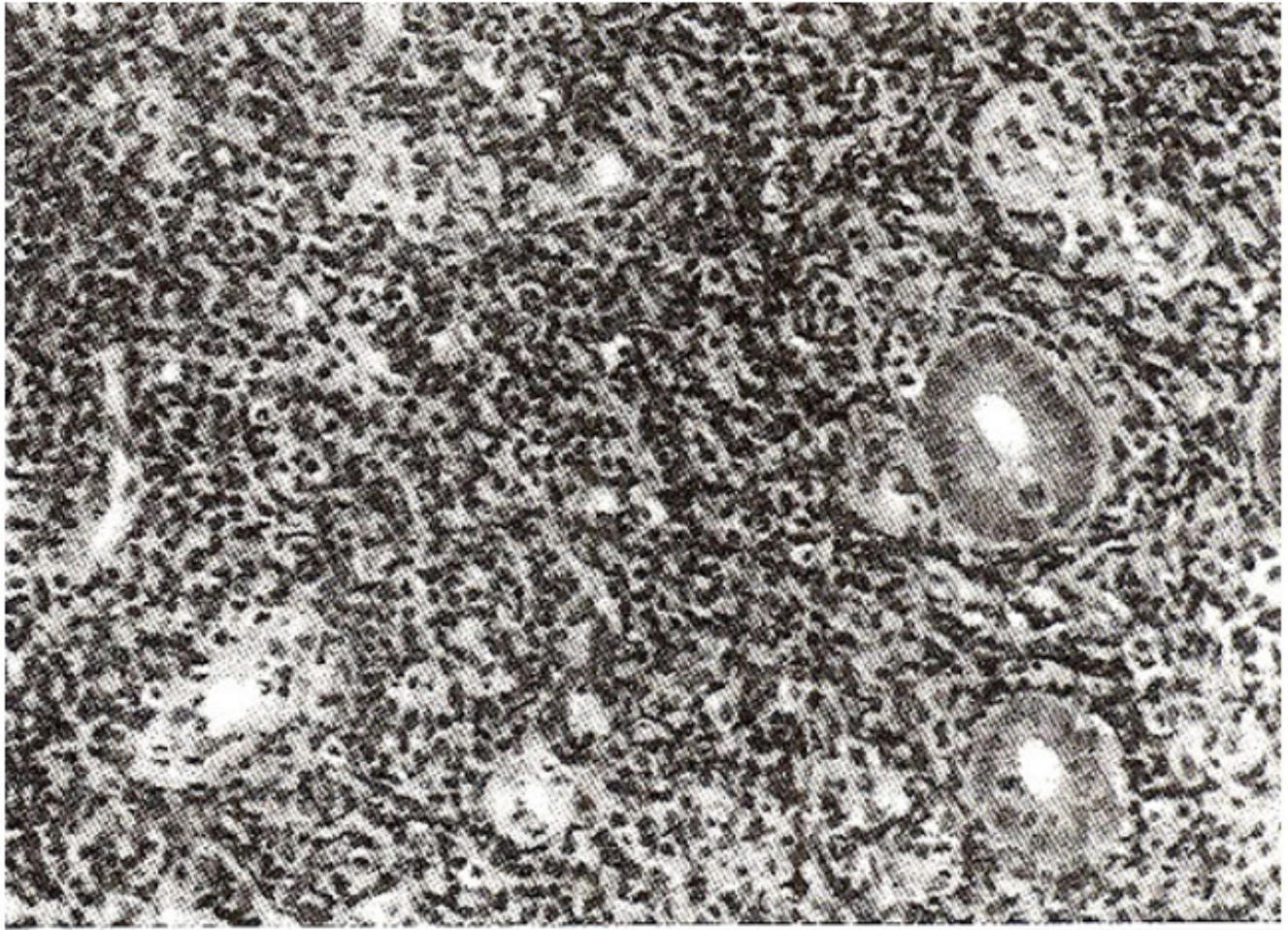


Figure 5. Lymphoma rectum - lymphoma cell infiltration in the lamina propria (H&E x 100).

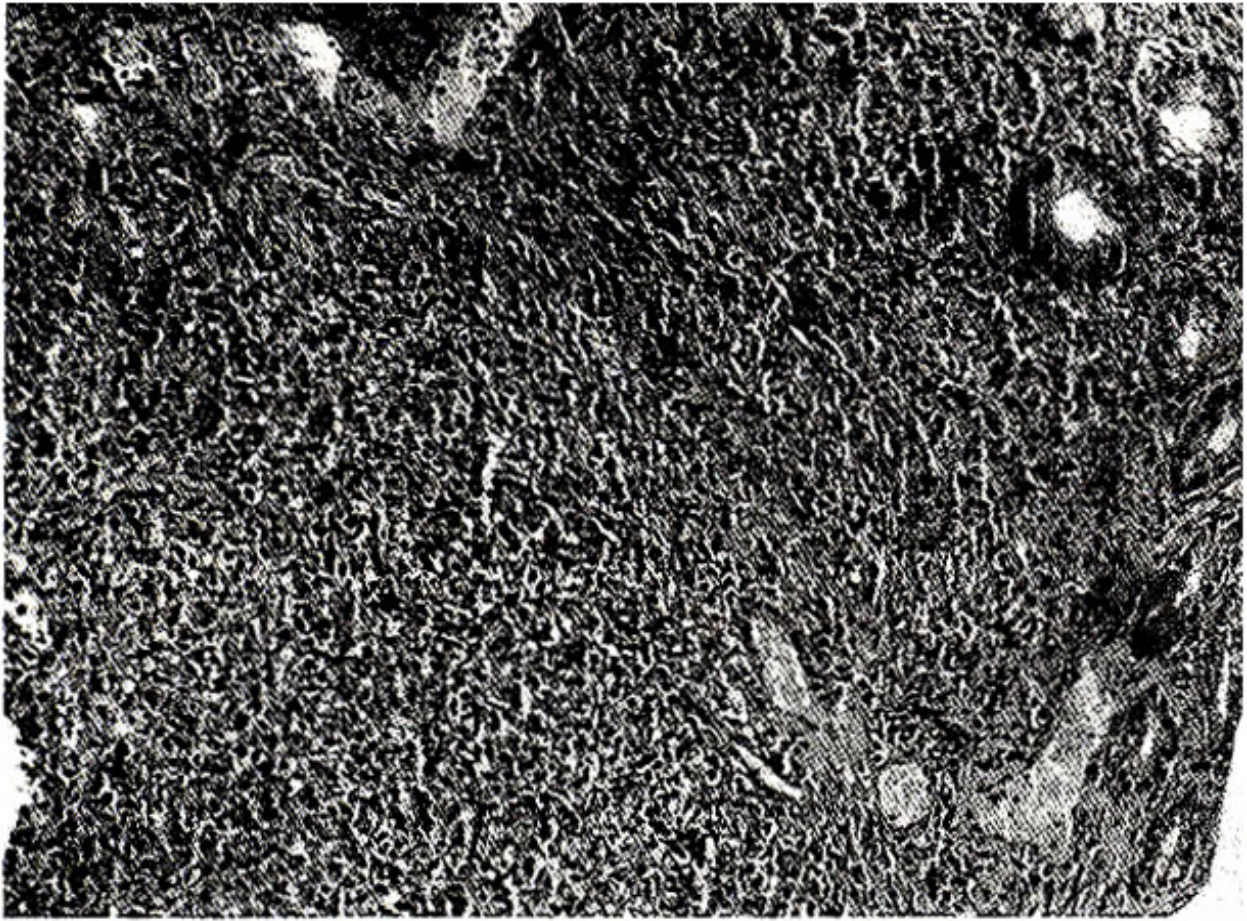


Figure 6. Lymphoma rectum - large bowel mucosa showing replacement of the crypts by lymphoma cells (H&E x 100).

Chestx-raywas normal. Computerized tomogram of the abdomen showed thickened loops of bowel and enlarged retroperitoneal lymph nodes. Hemoglobin was 10.7 gm%, ESR 40 mm/hr and IHA for arnebiasis was less than 1:16. This patient was given chiorambucil and prednisolone for his lymphoma.

DISCUSSION

Malignant lymphoma of the large gut complicating chronic ulcerative colitis is rare¹. First ever report of ulcerative colitis complicated by lymphoma appeared in 19282. There are less than thirty cases of this association reported in literature³⁻⁸. One case of malignant lymphoma arising in terminal ileum of a patient with ileostomy after colectomy for ulcerative colitis has also been mentioned⁹ and a recent report describes lymphoma occurring after colectomy and ileorectal anastomosis in ulcerative colitis¹⁰. Most lymphomas in this situation are of B cell lineage. It is important to exclude involvement of gut in a generalized lymphomatous process rather than this being a primary gut lymphoma. Therefore, there should be no evidence of lymphoma in bone marrow, lymph nodes except regional nodes, liver, spleen and other distant sites at least in the initial phases of disease¹¹. Our cases were diagnosed quite late and yet it seems that there was no extra abdominal spread of disease and that this was primary gut lymphoma Case 1 is unusual in that she was a young female with left sided colonic involvement whereas most cases reported in literature are middle aged males with right sided involvement of colon¹². Our report further emphasises the importance of continued surveillance to detect rectal

lymphoma as well as carcinoma.

REFERENCES

1. Edwards, P.C. and Truelove, S.C. The course and prognosis of ulcerative colitis. III. Complications. *Gut*, 1964;5:1-22.
2. Bargen, S.A. Chronic ulcerative colitis associated with malignant disease. *Arch. Surg.* 1928;17:561-76.
3. Bashiti, H.O. and Kraus, K.T. Histiocytic lymphoma in chronic ulcerative colitis. *Cancer*, 1980;46:1695-700.
4. Sataline, L.R., Mobley, E.M. and Kirkham, W. Ulcerative colitis complicated by colonic lymphoma. *Gastroenterology*, 1963;44:342-47.
5. Walker, F.C., and Weaver, J.P. Lymphosarcoma in ulcerative colitis. *Br.J. Surg.*, 1964;51:475-77.
6. Wychulis, A.R., Beahrs, O.H. and Woolner, L.B. Malignant lymphoma of the colon. A study of 69 cases. *Arch. Surg.*, 1966;93:215-25.
7. Nugent, F.W., Zuberi, S., Bulan, M.B. and Legg, M.A. Colonic lymphoma in ulcerative colitis: report of four cases. *L. abey Clin. Found. Bull.*, 1972;21:104-11.
8. Parikh, N.K. Shah, P.M., Patel, S.M. and Chandra, D.D. Colonic lymphoma in ulcerative colitis (a case report). *J. Assoc. Physns. India*, 1973;21:713-16.
9. Lewin, K.J., Ranchod, M. and Dorfman, R.F. Lymphoma of the gastrointestinal tract. *Cancer*, 1978;42:693-707.
10. Tears, J.P., Greenfield, S.M. and Slater, S. Rectal lymphoma after colectomy for ulcerative colitis. *Gut*, 1992;33:138-39.
11. Dawson, L.M.P., Comes, J.S. and Morson, B.C. Primary malignant lymphoid tumors of the intestinal tract. Report of 37 cases with a study of factors influencing prognosis. *Br.J.Surg.*, 1961;49:80-9.
12. Renton, P. and Blackshaw, A.J. Colonic lymphoma complicating ulcerative colitis. *Br.J. Surg.*, 1976;63:542-45.