

Anterolateral Decompression for Traumatic Spinal Cord Compression

Pages with reference to book, From 242 To 243

Ahmed Ali Shah, Iqbal Ahmed Memon (Department of Neurosurgery, Dow Medical College and Civil Hospital, Karachi.)

Abstract

Nine patients with traumatic fractures of doisolubar spine leading to pain and neurological deficit are presented. All had radiological evidence of spinal cord or quada equina compression, with either monoparesis, paraparesis or sphincter dysfunction alone. All patients underwent anterolateral decompression through a transpleural or retroperitoneal approach. Seven patients had bone grafting and spinal stabilization with Webb-Morley system. Two patients had decompression only. The results were favourable. This approach is safe and effective and allows early mobilization and functional recovery (JPMA44:242,1994).

Introduction

The treatment of spinal injuries has been a most unrewarding and frustrating surgical exercise even in the hands of most experienced surgeons. The classical approach to these problems has been a posterior decompressive laminectomy and the surgical literature is full of reports of dismal results¹. Alternate methods for dealing with anterior thoracic and lumbar abnormalities have achieved a success rate far exceeding that of standard laminectomy². Tn 1956, Hodgson and Stock³ developed anterolateral, transthoracic procedure for the treatment of tubereulous spine with excellent results. Anterolateral approach allows a one-stage decompression of the neural tissue and spinal stabilization with metallic prosthesis alongwith bone grafting. showed dramatic spinal cord cojnpression from bone and disc material (Figure 3).

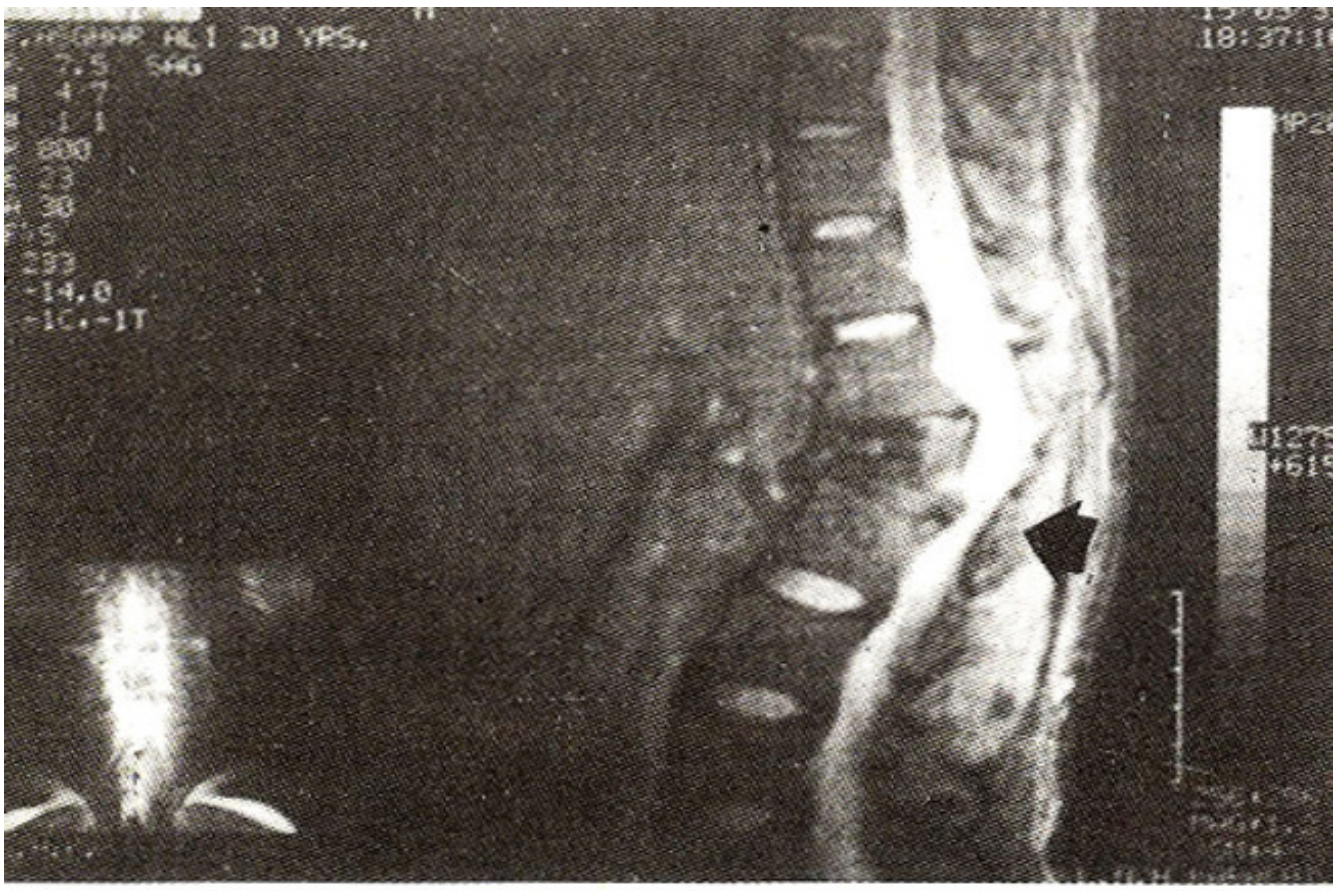


Figure 3. Sagittal MRI image showing spinal cord compression and angulation.

Patients and Methods

Nine patients with traumatic fractures of dorsal and lumbar spine were treated at the neurosurgery department of Civil Hospital, Karachi, between 1989 and 1993. There were 8 males and one female (mean age 22 years). Six patients were involved in road traffic accidents and one each had a fall from a tree, an electric pole and one during a grandmal seizure. Five patients had compression fractures involving the body of L1 vertebra, three had D 12 fractures and one had an L2 fracture. Four patients presented with para-paresis, two with monoparesis and three had sphincter dysfunction alone. All had pain in addition to their neurological deficit. In two patients with sphincter dysfunction, the injury had taken place more than 6 months previously and the fractures had healed. The other 7 patients presented within 48 hours of injury. Plain radiographs in all patients showed compression fractures involving a single vertebra with retropulsion. Angulation was seen in 5 patients. One patient had a myelogram which showed a complete block at the level of fractured vertebra (Figure 1).

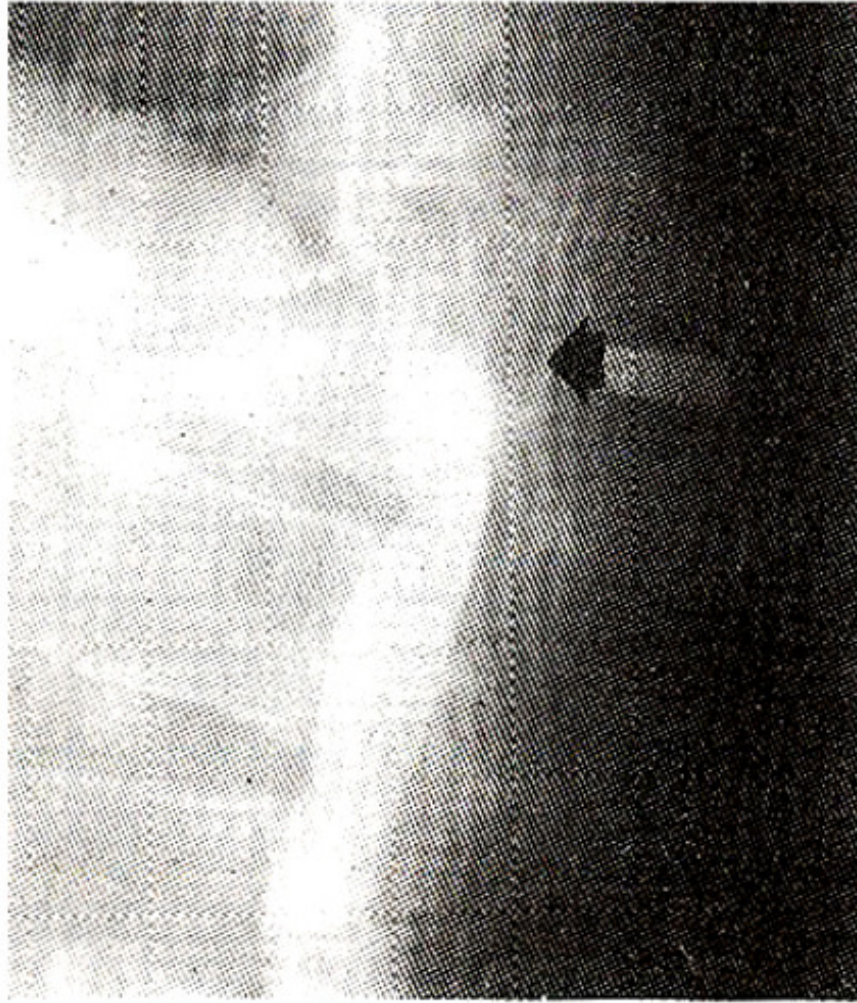

Figure 1. Myelogram showing a complete block due to retropulsion of fractured bone.

Three patients had CT-myelogram showing compression of ventral subarachnoid space from retropulsed fragments (Figure 2).

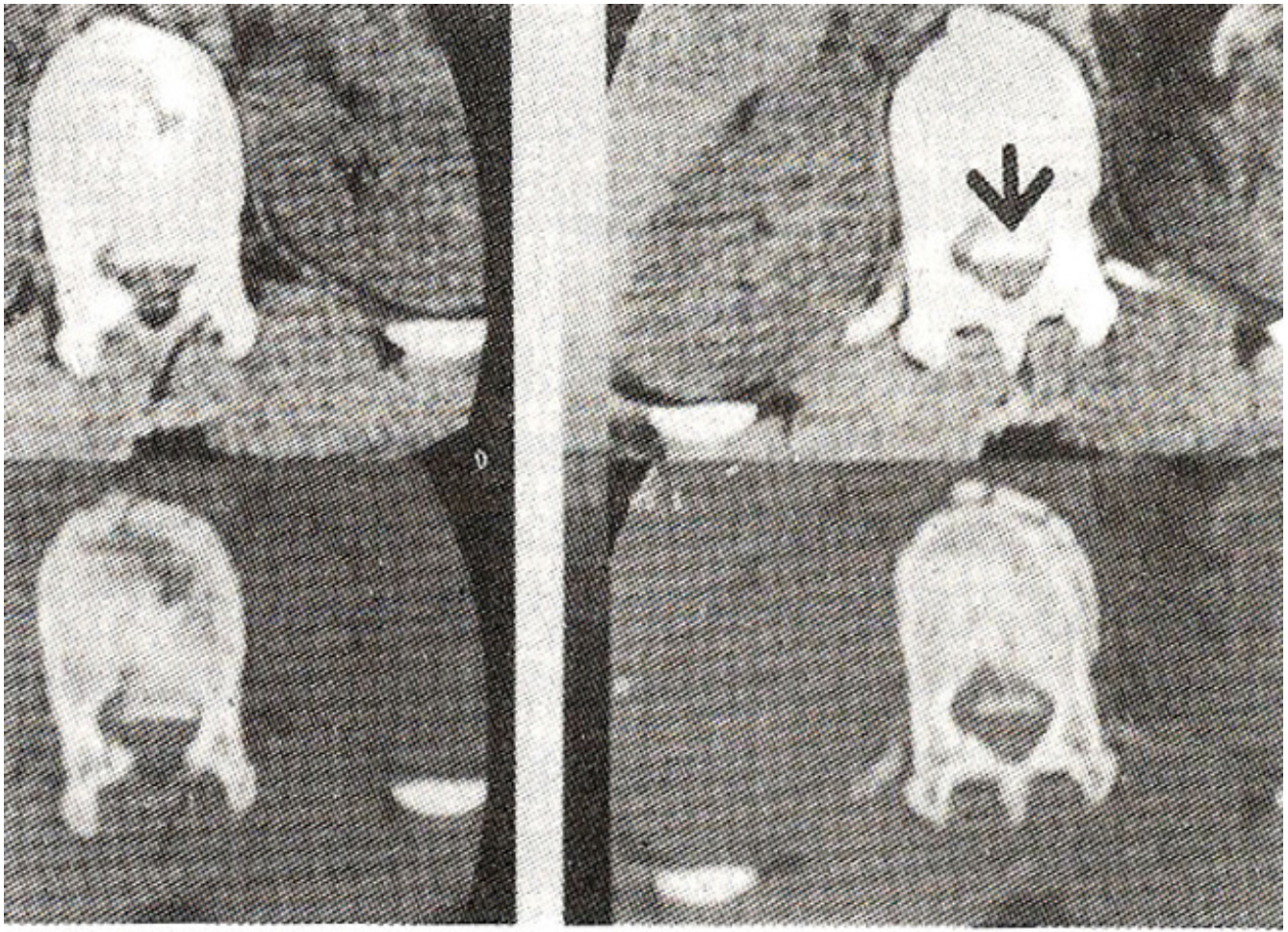


Figure 2. Axial CT showing retropulsed fragment within the spinal canal.

The other five had an MN which All patients had an anterolateral decompression, either through athoracotomy or a retroperitoneal approach, depending on the level of injury, in the lateral decubitus position. A high speed drill was used to resect the relevant pedicle and the bony fragments within the spinal canal. The prolapsed disc was also excised in each case and the dural sac decompressed. Seven patients had a bone graft, taken from the iliac bone or the resected rib, placed in the defect. All the seven had spinal stabilization by the Webb-Morley instrumentation (Figure 4).

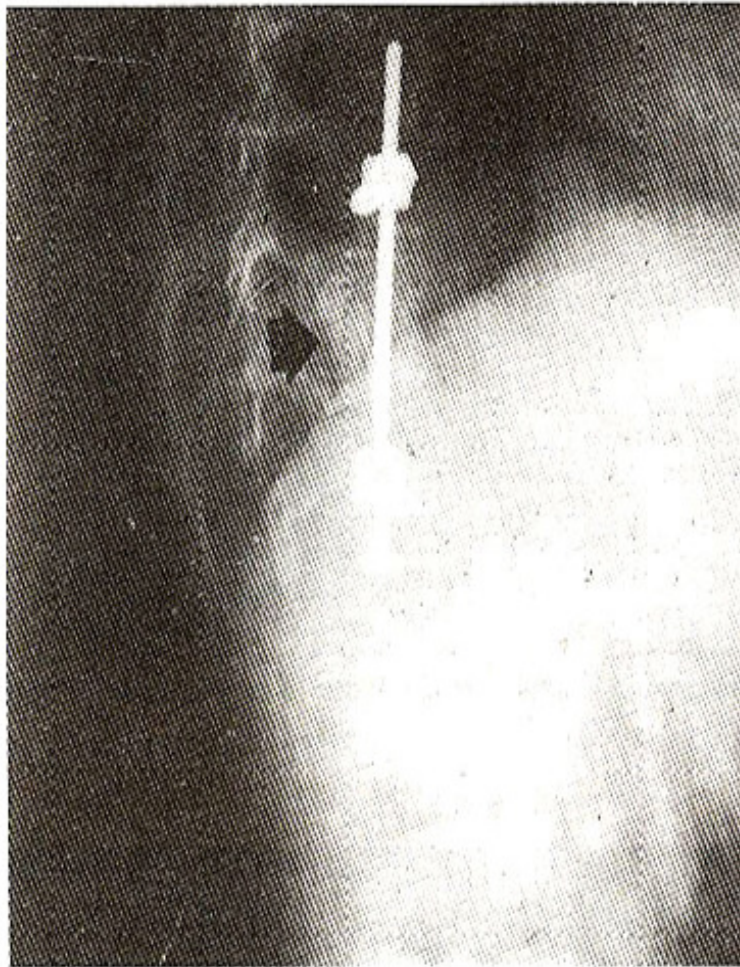


Figure 4. Lateral view of the spine showing stabilization in distraction with Webb-Morley system and bone graft.

There was no mortality and the complications were insignificant and transitory. All patients were ambulatory within 10 days of the surgical procedure and each received physiotherapy for several weeks. Of the four patients with paraparesis, three recovered completely whereas one continues to have unilateral partial foot-drop. All three patients with sphincter dysfunction improved; two completely and one partially. Two patients with monoparesis had a total neurological recovery. Our follow-up has been from 3 months to 3 years.

Discussion

Spinal injuries are common in Pakistan, not only from the ever increasing road traffic accidents but also from falls from rooftops, trees and electric poles. As there are no spinal wilts, majority of these unfortunate patients with permanent disability suffer tremendously from serious complications such as bedsores, urinary tract infections and chest infections. A small number of patients with partial neurological deficit also face the same bleak future although they have a good potential for recovery, if treated effectively and within reasonable time. The goals of management should therefore be to ensure best possible neurological recovery, provide early mobilization and to prevent delayed spinal instability and pain⁴. The current management of thoracolumbar spine injuries has changed from the conservative approach of Guttman⁵ to a more aggressive surgical intervention. It is logical to assume that continued

compression of neural tissue can only hamper neurological recovery and delay mobility⁴. Surgical decompression and spinal stabilization shortens the period of immobilization, hospitalization and rehabilitation and reduces the degree of spinal deformity and pain^{4,6}. It is generally assumed that for lesions anterior to the cervical spinal cord, an anterior decompression and fusion should be performed, whereas, for posterior lesions, a posterior laminectomy should be done⁷. This sound reasoning ought to be extended to thoracic and lumbar spine as well, where the compression of neural tissue is anterior, from retimpulsion of bony fragments and disc material. Most surgeons now agree that laminectomy is, at best, inadequate when dealing with ventrally situated lesions². An antemlateral decompression through transpleural or retroperitoneal approach allows direct access to the lesion. The neural tissue can be effectively decompressed by removing the offending bone and disc, an iliac or rib graft can be placed for osteogenesis and bony fusion and spinal stabilization afforded by metallic implant application. This would correct the deformity too. We have presented 9 cases treated anterolaterally with favourable results. All these patients had significant neurological deficit and radiological evidence of anterior thecal compression. All of them benefitted from timely surgical intervention and became ambulatory. A one-stage antemlateral decompression and stabilization through a transpleural or a retroperitoneal approach is a safe and effective method of dealing with thoracic and lumbar spine trauma.

References

1. Perot, P.L. and Munro, D.D. Transthoracic removal of midline thoracic disc protrusions causing spinal cord compression. *J. Neurosurg.*, 1969;31:452-58.
2. Lobosky, J.M., Hitchon, R.W. and McDennell, D.E. Transthoracic anterolateral decompression for thoracic spine lesions. *Neurosurgery*, 1984;14:26-30.
3. Hodgson, A.R. and Stock, F.E. Anterior spinal fusion. A preliminary communication on the radical treatment of Pott's disease and Pott's paraplegia. *Br. J. Surg.*, 1957;44:266-75.
4. Bose, B., Osterholm, J.L., Northrup, B.E. et al. Management of lumbar translocation injuries Case reports. *Neurosurgery*, 1985;17:958-61.
5. Guttman, L. Spinal deformities in traumatic paraplegics and tetraplegics following surgical procedures. *Paraplegia*, 1969;7:38-58.
6. Jacobs, R.R., Ather, M.A. and Sridler, R.K., Thoracolumbar spinal injuries. A comparative study of recumbent and operative treatment in 100 patients. *Spine*, 1980;5:463-77.
7. Benzel, E.C., and Larson, S. J. Functional recovery after decompressive operation for thoracic and lumbar spine fractures. *Neurosurgery*, 1986;19:772-78.