

Crossed renal ectopia presenting with suprapubic swelling and acute renal failure

Sundeep Singh Grewal

Abstract

A 17-year-old male was admitted with a fluctuant suprapubic mass. A bladder scan demonstrated >999 ml filling so he was catheterised. However, only 75ml of urine was drained. He was in acute renal failure with serum potassium of 6.5mmol/l. Computerised tomography (CT) scan showed a large midline 'cystic mass' separate from the bladder compressing the left ureter, causing left-sided hydronephrosis. Right kidney was not visualised. Percutaneous aspiration of the 'cyst' yielded 2000ml of straw-coloured fluid high in creatinine, urea and electrolytes indicating that it was urine. Having relieved the left ureter, the patient was subsequently diuresed, and renal function returned to normal.

A CT urogram showed contrast uptake with renal parenchyma in the 'cyst'. Consequently, a diagnosis of right-sided crossed renal ectopia was made. Bilateral ureteric stents were inserted, and later a right-sided nephrectomy was performed. The patient made a full recovery. To the best of our knowledge, this is the only reported case of crossed renal ectopia causing obstruction of the normal ureter, resulting in acute renal failure. The role of modern imaging in the management of this condition is also highlighted in this report.

Keywords: Crossed renal ectopia, DMSA, Nephrectomy.

Introduction

Crossed renal ectopia occurs when both kidneys are on the same side with two ureters inserting into the bladder.¹ It is extremely rare and most cases are discovered incidentally.

A case of presumed urinary retention in a young male with a midline lower abdominal mass is reported herein. This transpired to be crossed renal ectopia. In this case, the right-sided ectopic kidney obstructed the left ureter, resulting in left-sided hydronephrosis and acute renal failure. The ectopic kidney presented with a large painless, central abdominal mass. The use of computerised tomography (CT) imaging to diagnose this condition is also being commented upon for the first time, and its subsequent use in the surgical management. To our

.....
Addenbrooke's Hospital, Cambridge University. Hills Road, Cambridge.

Correspondence: Email: sundeep_grewal@hotmail.com

knowledge, this is the first case to present in such a way and to be investigated with CT imaging.

Case Report

A 17-year-old male was admitted with a palpable midline abdominal mass that had been enlarging over three weeks. He described mild left loin pain and his urine output had been minimal for 48 hours. Abdominal examination confirmed a tense, fluctuant midline mass, and a portable bladder scanner indicated a volume of

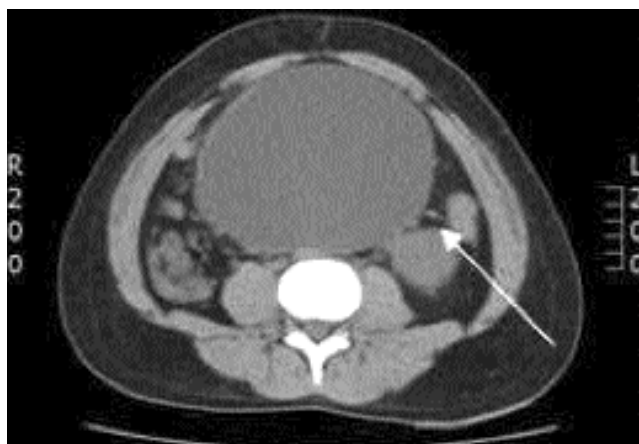


Figure-1: CT scan showing a very large abdominal cystic mass compressing the left ureter (arrow).

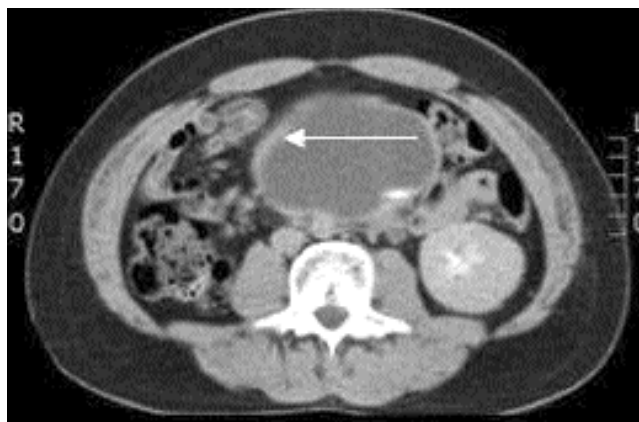

Figure-2: CT scan demonstrating contrast uptake in the periphery of the right crossed ectopic kidney showing it is parenchymal tissue (arrow). This is after the kidney was drained percutaneously.

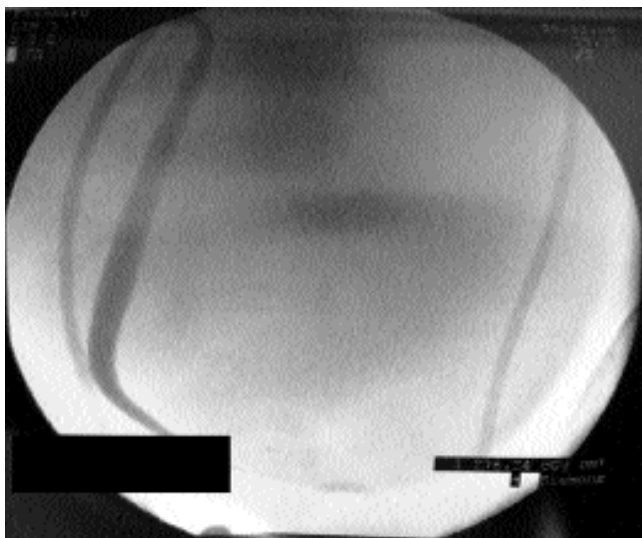


Figure-3: Retrograde study with stent insertion, revealing a hairpin ureter in the dilated ectopic kidney and contrast pooling in a large cystic structure.

>999ml. Neurological examination and bedside observations were unremarkable.

The admitting house surgeon felt that this mass could be a palpable bladder and thus made a diagnosis of urinary retention and urethral catheterisation was performed, draining only 75ml of urine. Blood results revealed an elevated creatinine level of 13.1mg/dL, urea level of 477 mg/dL, potassium level of 6.5mmol/l and an eGFR of 9ml/min. An electrocardiogram (ECG) showed changes consistent with hyperkalaemia and medical management of this was commenced. His urine output remained minimal despite reinsertion of the urethral catheter and attempts to confirm its position with a bladder flush. Suprapubic catheterisation was not felt to be appropriate.

An urgent abdominal ultrasound showed "a mass likely to be a distended bladder with a left hydronephrotic kidney". The right kidney was not visualised. A non-contrast CT scan of the abdomen and pelvis was requested, which reported an empty bladder with a very large "abdominal cyst" compressing the left ureter with an associated left hydronephrosis. The right kidney was again not visualised (Figure-1).

Following discussion and review of the imaging with the general surgeons, a differential diagnosis of "mesenteric cyst" causing obstruction of a solitary kidney and thus acute renal failure was suggested. The recommended management of this case was by placement of a left-sided nephrostomy to drain the hydronephrosis and subsequent percutaneous aspiration of the 'cyst', performed using a

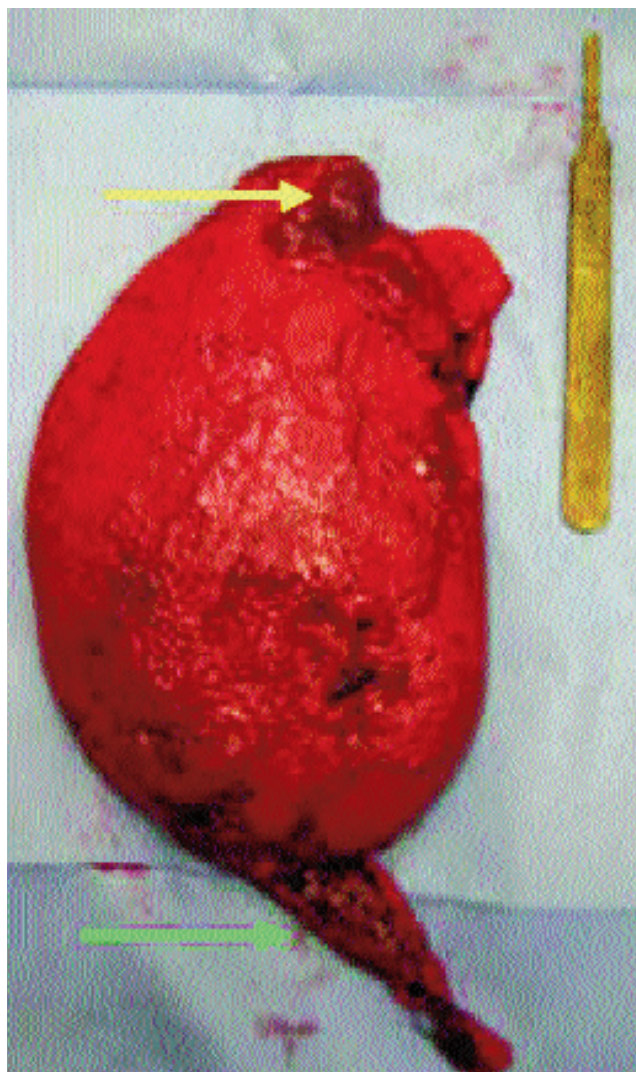


Figure-4: Image of the crossed renal ectopic kidney post nephrectomy, as compared to a standard surgical scalpel. The renal tissue is visible at the upper pole (yellow arrow) with the remainder of the structure a grossly dilated renal pelvis. A megaureter is also visible (green arrow).

large bore cannula 1.5cm below the umbilicus.

About 2000ml of straw-coloured fluid was aspirated and sent for biochemistry, including creatinine, microscopy and cytology. Immediately after the aspiration of the 'cyst', the patient drained 350ml of urine from the urethral catheter and began to diurese.

Biochemistry of the cyst aspirate revealed a creatinine level of 59.9 mg/dL, urea level of 1389 mg/dL, sodium level of 64mmol/l, and potassium level of 10.1 mmol/l, thereby indicating that it was urine. The patient continued to diurese approximately 8000ml per day for 4 days and

required careful fluid management; however his renal function normalised by the third day of admission. As such, a CT urogram was performed to clarify the nature of this cystic structure.

Surprisingly, a contrast level was seen within the cyst with an area of enhancing tissue at the periphery, suggesting it comprised of renal parenchyma (Figure-2). The left kidney and ureter were dilated as they were obstructed by the 'cyst'. A diagnosis was made of a right-sided crossed-ectopic hydronephrotic kidney causing obstruction to the left ureter and acute obstructive renal failure.

Cystoscopy and bilateral retrograde studies were arranged. The left ureter and kidney were dilated above the level of the cyst and a 6FG multi-length ureteric stent was placed. Right retrograde study revealed a hairpin ureter filling into a grossly dilated renal pelvis (Figure-3). With some difficulty, a 4.8FG multi-length stent was placed into the renal pelvis. Subsequently a dimercaptosuccinic acid (DMSA) renogram showed <1% function from the right kidney.

Following multidisciplinary discussion, a right nephrectomy was performed via a midline laparotomy (Figure-4). Surgery revealed unfused crossed ectopic renal tissue in the midline with a grossly dilated renal pelvis with the stented left ureter closely adherent to it.

An uneventful post-operative recovery was made and the patient was discharged. The ureteric stent was subsequently removed under a local anaesthetic and his renal function remains within normal limits at recent review.

Discussion

Crossed renal ectopia is a condition in which both kidneys exist on the same side with two separate ureters inserting into the bladder. The kidneys can be fused,¹ and while this condition is thought to be very rare, autopsy findings suggest an incidence as high as 1:7000.² It is also twice as common in men and the migration of the left kidney to the right occurs three times more frequently.³

The aetiology is unclear, although it is hypothesised that the problem lies with the ureteric bud crossing over to the contralateral metanephric blastema, thereby inducing differentiation of a renal promordium.⁴

Approximately 30% of the cases are found incidentally. Some common presenting complaints include abdominal pain, urinary tract infections and frank haematuria.⁵ The associated urological findings also include hydronephrosis,

reflux, nephrolithiasis and rarely, tumours.^{4,6}

To our knowledge, no patient in the literature has presented with unfused crossed renal ectopia causing ureteric obstruction and subsequent acute renal failure. The presentation is also unique since it appeared as a painless abdominal mass. A nephrectomy was indicated in this case, as a renogram demonstrated minimal renal function in the ectopic kidney, and so pyeloplasty or any form of reconstruction would have been inappropriate.⁷

In this case the right hemicolon was mobilised and a combination of blunt and sharp dissection was used to isolate the large midline dilated renal pelvis. The lower ureter was identified, mobilised, ligated and divided, with the previously inserted stent removed. The left ureter was carefully preserved.

Contrast CT scan was particularly helpful in this case not only for diagnosis but also for preoperative planning. It enabled clear identification of the vascular anatomy, in place of angiography, which has been used in previous cases.⁷ It also helped confirm the nature of the cyst whereas intravenous urograms have been used in the past.⁸

Conclusion

This case highlights how unfused crossed renal ectopia is a very interesting, albeit rare, cause of an abdominal mass causing obstructive acute renal failure. Modern cross-sectional imaging techniques such as contrast enhanced CT imaging can be used to aid diagnosis and are particularly useful to delineate anatomy to enable the safe and planned management of this condition. This case also highlights some of the limitations of ultrasound imaging when investigating abdominal pathology.

References

1. McDonald JH, McClellan DS. Crossed renal ectopia. *Am J Surg* 1957; 93: 995-1002.
2. Campbell MF, Harrison JH (eds.). *Urology*. 3rd ed. Philadelphia: WB Saunders; 1970; pp 1458
3. Fowles GA, Mee AD, Colbeck R, Twomey B. Acute abdomen - an unusual presentation of crossed renal ectopia. *Br J Urol* 1994; 73: 328-9.
4. Kyrayiannis B, Stenos J, Deliveliotis A. Ectopic kidneys with and without fusion. *Br J Urol* 1979; 51: 173-4.
5. Marshal FF, Freedman MT. Crossed renal ectopia. *J Urol* 1978; 119: 188-91.
6. Birmole BJ, Borwankar SS, Vaidya AS, Kulkarni BK. Crossed renal ectopia. *J Postgrad Med* 1993; 39: 149-51.
7. Hendren WH, Donahoe PK, Pfister RC. Crossed renal ectopia in children. *Urology* 1976; 7: 135-44.
8. Baniel J, Glezeron G, Tobias M, Manning AJ. Crossed renal ectopia. Case report. *Scand J Urol Nephrol* 1991; 25: 241-4.