

# Barium Stone Impaction in Parkinsonism

Pages with reference to book, From 165 To 167

Yamac Erhan, Ali Koyuncu ( Departments of Surgery, Aegean University Medical School, Izmir, Turkey. )  
Necla Osmanoglu ( Departments of Gastroenterology, Aegean University Medical School, Izmir, Turkey. )

## Abstract

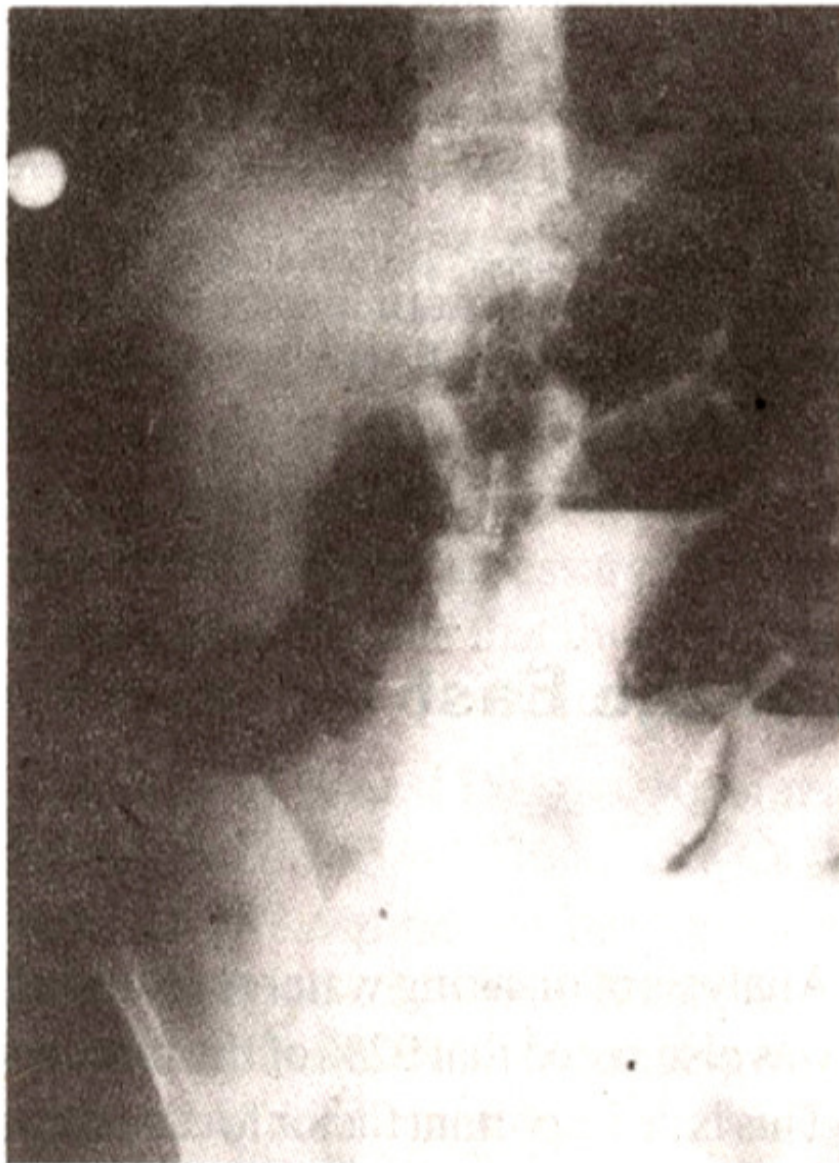
Autonomic symptoms such as orthostatic hypotension, abnormal sweating and constipation occur frequently in Parkinson's disease. In our case, barium meal used for upper gastrointestinal study caused barium stone formation and a paralytic-ileus-like syndrome. Therefore, attention should be paid while using barium meal for diagnostic purpose in Parkinsonism.

## Introduction

Barium meal used in Parkinson's disease for upper gastrointestinal tract studies can cause a real chaos. Autonomic symptoms such as orthostatic hypotension and abnormal sweating occur frequently in patients with idiopathic Parkinson's disease<sup>1,2</sup>. Sialorrhea, nasopharyngeal dysfunction, dysphagia, achalasia delayed gastric emptying, chronic colonic pseudoobstruction, volvulus and megasigmoid are other disturbances of alimentary function which have been reported by various authors<sup>3,4</sup>. In a significant number of cases, examination performed by barium enema revealed atony of the large bowel, sometimes leading to a megacolon<sup>5</sup>. Inpatients suffering from constipation with Parkinson's disease, barium meal used for upper gastrointestinal X-ray studies and barium enema should be immediately evacuated from the intestine in order to prevent the formation of barium stones<sup>7</sup>. We present a patient in whom barium meal caused a paralytic-ileus-like syndrome two days after an upper gastrointestinal series.

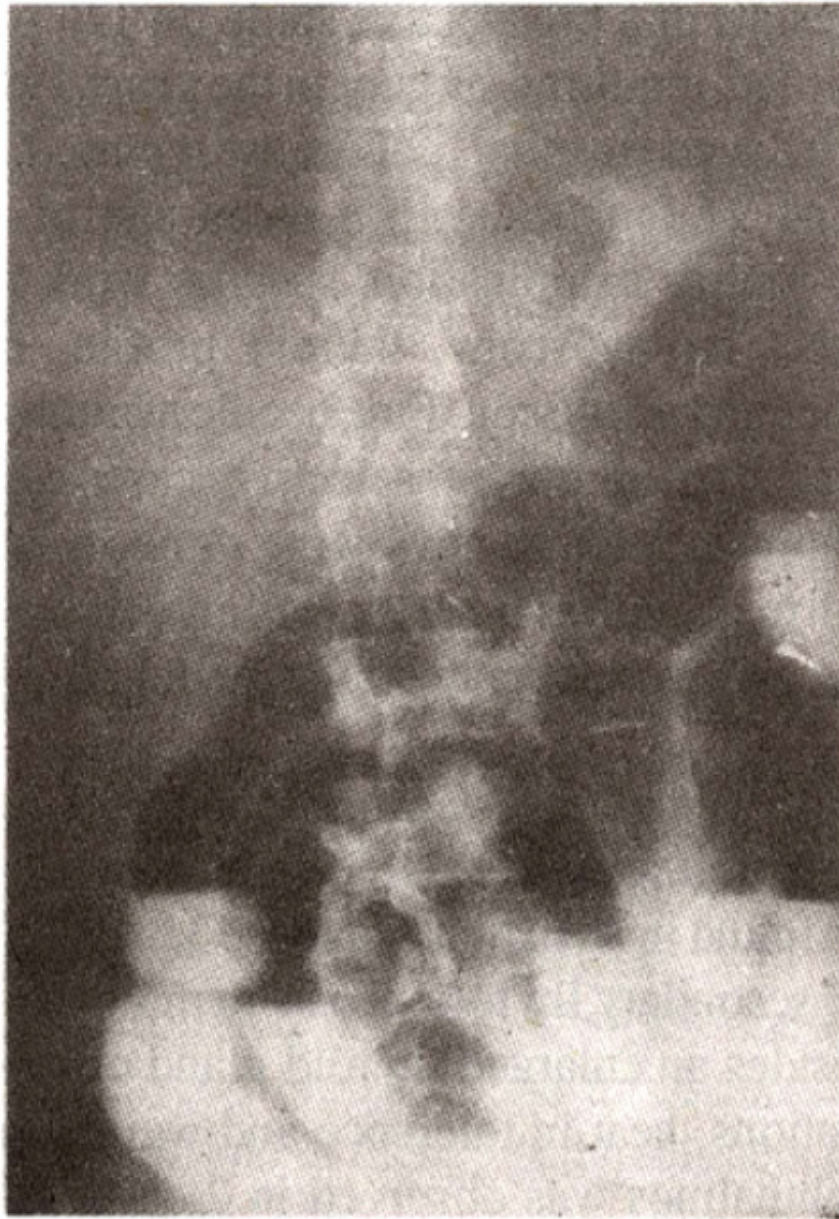
## Case report

A 39 years old man with Parkinson's disease was admitted because of epigastralgia and vomiting for two days. He had a fine intermittent tremor of both hands, mild cogwheel rigidity in the neck muscles and arms and gait disturbance leading to a diagnosis of Parkinson's disease. An upper gastrointestinal x-ray study revealed no pathognomonic findings. Two days later, the patient complained of abdominal pain, constipation, obstipation and abdominal distention. A plain abdominal film (Figures 1,2,3)



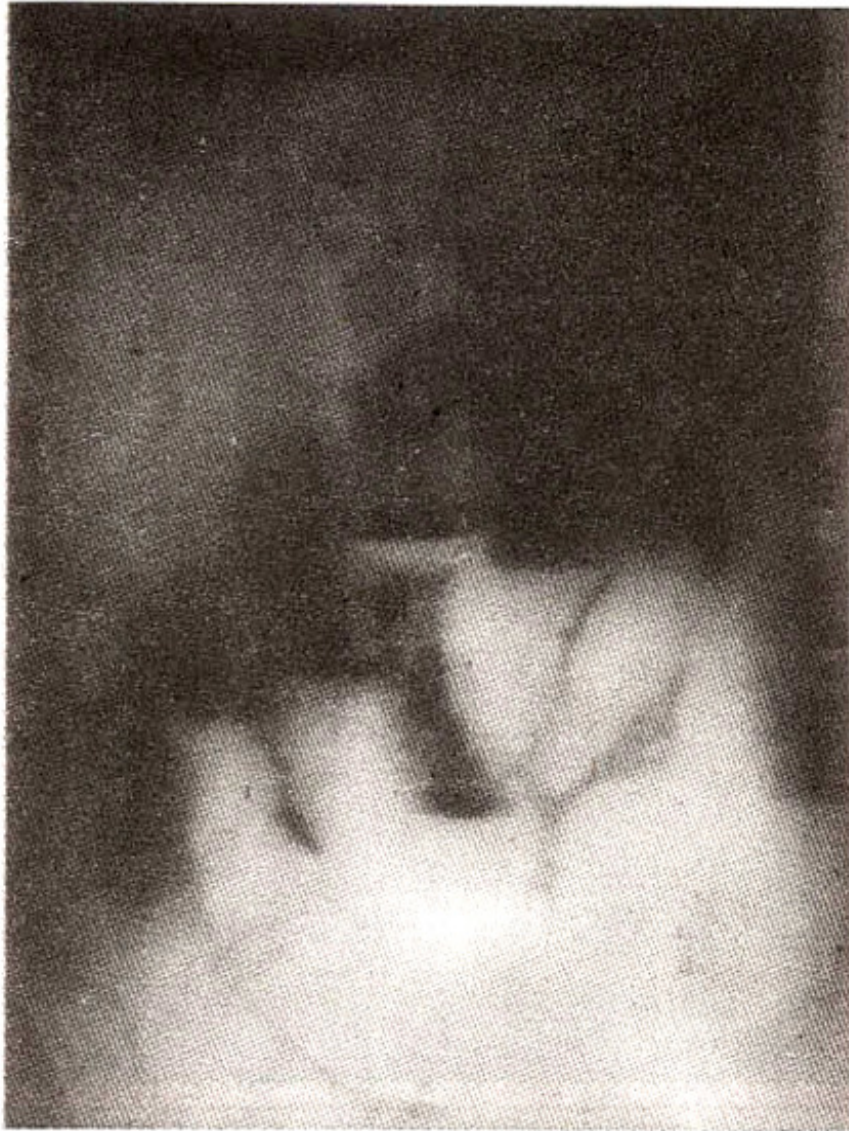---

Figure 1. Large amount of barium throughout the small intestine (the same day) and gas-fluid level.



---

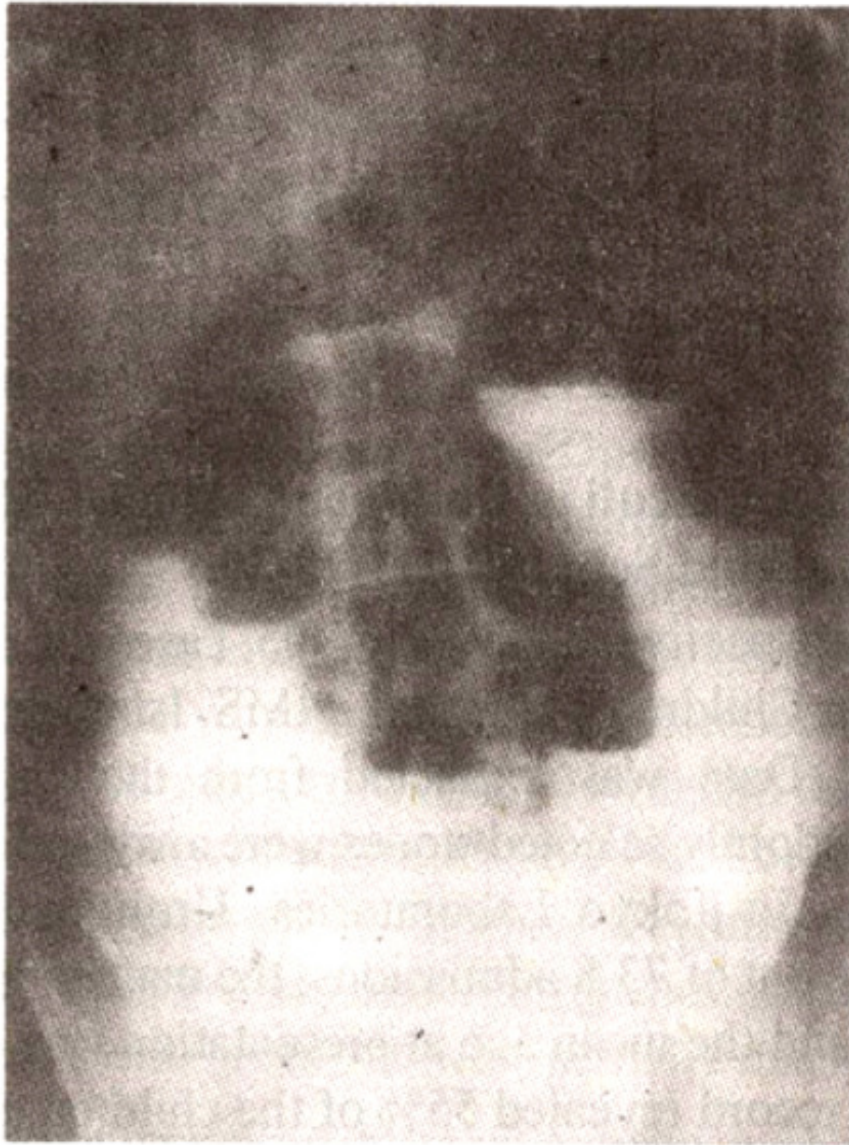
Figure 2. Barium seen throughout the small intestine and gas-fluid level still continuing (5 days later after barium meal examination).



---

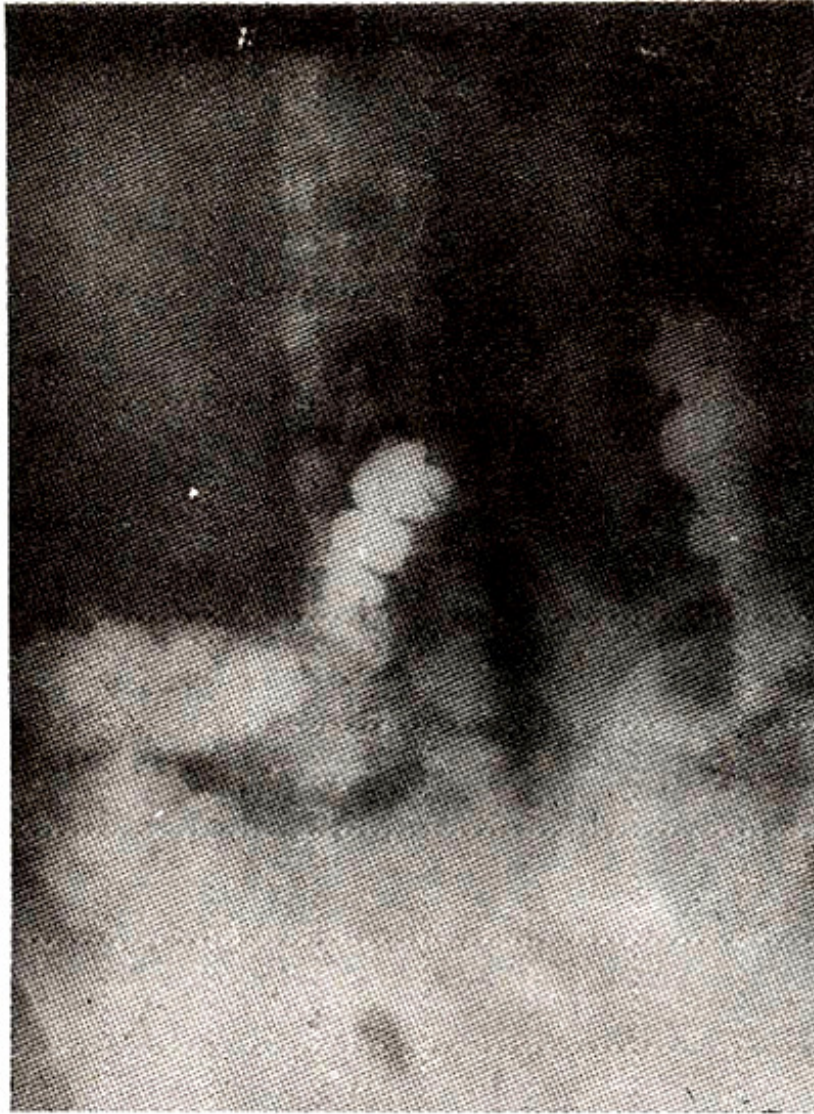Figure 3. Barium seen throughout the small intestine and gas-fluid level still lasting (12 days later after barium meal examination).

revealed a large amount of barium throughout the small intestine and gas-fluid levels. These radiographic findings persisted for 20 days (Figures 4 and 5).



---

Figure 4. Plain abdominal X-ray showing barium throughout the small intestine (16 days later after barium meal examination).



---

Figure 5. Finally, barium passed throughout the colon (20 days later after barium meal examination).

Multiple analeptic enemas and parenteral nutrition overcome the difficulty. Further abdominal x-ray films showed no barium remnants. Thereafter, the patient received anti-Parkinsonian therapy.

### **Discussion**

Autonomic symptoms, especially related with alimentary function, occur frequently in patients with idiopathic Parkinson's disease<sup>4,5</sup>. However, the distinct pathologic basis for autonomic symptoms in Parkinsonism has not been established. Some investigators have found degenerative changes, including neurons containing intracytoplasmic hyaline inclusions (Lewy bodies) in hypothalamic and brain stem nuclear groups and in sympathetic ganglion cells in Parkinsonian patients with these symptoms and have concluded that the symptoms may reflect direct involvement of these neural structures by the disease process<sup>4,7</sup>. Involvement of the dorsal motor nucleus of the vagus nerve has been postulated to account in part for the disturbances in gastrointestinal function. Our case suggests that barium meal

used in an upper gastrointestinal study may lead to the development of a paralytic-ileus-like syndrome in Parkinsonian patients with constipation.

## References

1. Appenzeller, O. and Goss, J. E. Autonomic deficits in Parkinson's syndrome. *Arch. Neurol.*, 1974;24:50-57.
2. Gross, M., Bannister, R. and Godwin-Ansten, R. Orthostatic hypotension in Parkinson's disease. *Lancet*, 1972; 1:174-176.
3. Bernyi, M. R. and Schwartz, G. S. Megacigmoid syndrome in diabetes on neurologic disease: Review of 13 cases. *Am. J. Gastroenterol.*, 1967;47:311-320.
4. Selby, G. Parkinson's disease. *Handbook of clinical neurology*. Vinken, P. J., Bruyn G. W. (eds). Vol. 6, Diseases of the basal ganglia. Amsterdam, North-Holland, 1968, pp. 173-211.
5. Eadie, M.J. and Tyler, J. H. Alimentary disorders in parkinsonism. *Australas Ann. Med.* 1965;14:13-22.
6. Umeki, S. Caution in upper gastrointestinal x-ray study in constipated parkinsonsian patients. *South. Med. J.*, 1989;82: 1589-91.
7. Langston, J. W. and Forno, L. S. The hypothalamus in Parkinson's disease. *Ann. Neurol.*, 1978;3:129-133.