

# Benign Ovarian Cysts - A Retrospective Evaluation Over Two Years

Pages with reference to book, From 61 To 63

Noshin Wasim Yusuf, Ambreen Imran ( Department of Pathology, Fatima Jinnah Medical College, Lahore. )  
Rakhshanda Rehman ( Department of Obstetrics & Gynaecology, Fatima Jinnah Medical College, Lahore. )

## Abstract

Histological analysis of 89 "benign" ovarian cysts received over a period of 2-1/2 years (January, 1991 to July, 1993) at the department of Pathology, Fatima Jinnah Medical College, Lahore showed that 44 were neoplastic, 22 dysfunctional, 19 simple and 4 endometriotic. Clinical presentation and gross features could not serve to differentiate these types. Routine histological examination had to be supplemented with ample blocking and deeper sections for a more specific typing. With this procedure the original diagnosis was altered in 11.2% cases, 7 cases originally labelled as "simple cysts", were categorized as dysfunctional (N=2), neoplastic (N=1) and endometriotic cysts (N=3). Similarly in 3 cases the primary diagnosis of endometriotic cysts was altered in favour of dysfunctional (N=2) and neoplastic (N=1) cysts. The neoplastic and dysfunctional cysts have different clinical implications. It is proposed that the clinical diagnosis of benign ovarian cyst should be supported by a careful histological evaluation (JPMA 45: 61,1995).

## Introduction

Cystic masses in the ovary constitute the most frequently encountered adnexal lesions in gynaecological practice<sup>1</sup>. Their clinical management depends on the size of the cyst monitored by sequential ultrasound examinations<sup>2</sup>. Its increasing size beyond 3- 5 cm or presence of a solid focus calls for surgical intervention<sup>3</sup>. Histologically these cysts belong to two major categories i.e., neoplastic and dysfunctional, both having different clinical implications. Where histological differentiation between the dysfunctional cysts, neoplastic cysts and/or endometriotic cysts is not possible, the nondescript terminology of "simple cyst" is utilized<sup>4</sup>. In the present study we evaluated the "benign" ovarian cystic lesions to define the features which can help to differentiate between dysfunctional and neoplastic cysts.

## Material and Methods

A retrospective study was carried out to evaluate the benign cystic lesions of ovaries received in the Department of Pathology at Fatima Jinnah Medical College, Lahore, over a 2-1/2 years (January 1991 through July 1993). Slides were retrieved from the files and reviewed. At least 6-8 more blocks were taken where the specimens were still available or the available blocks were serially sectioned in debatable cases. The sections were stained with haematoxylin and eosin and the original diagnosis was varified.

## Results

A total of 89 "benign" cysts were evaluated. They were histologically classified (Table) into neoplastic (44), dysfunctional (22), simple (19) and endometriotic cysts (4). The clinical presentation and gross features could not serve to differentiate these types and routine histological examination had to be

supplemented with ample blocking and deeper sections for a more specific typing. With this procedure the original diagnosis was altered in 11.2% cases i.e. 7 “simple cysts” were categorized as dysfunctional (N=2), Neoplastic (N=2) and endometriotic cysts (N=3). Similarly in 3 cases the primary diagnosis of endometriotic cysts was altered in favour of dysfunctional (N=2) and Neoplastic (N=1) cysts. The pathognomonic microscopic features of follicular cysts, corpus luteal cyst, simple cysts and serous cyst adenomas, are shown in figures 1-4 respectively.

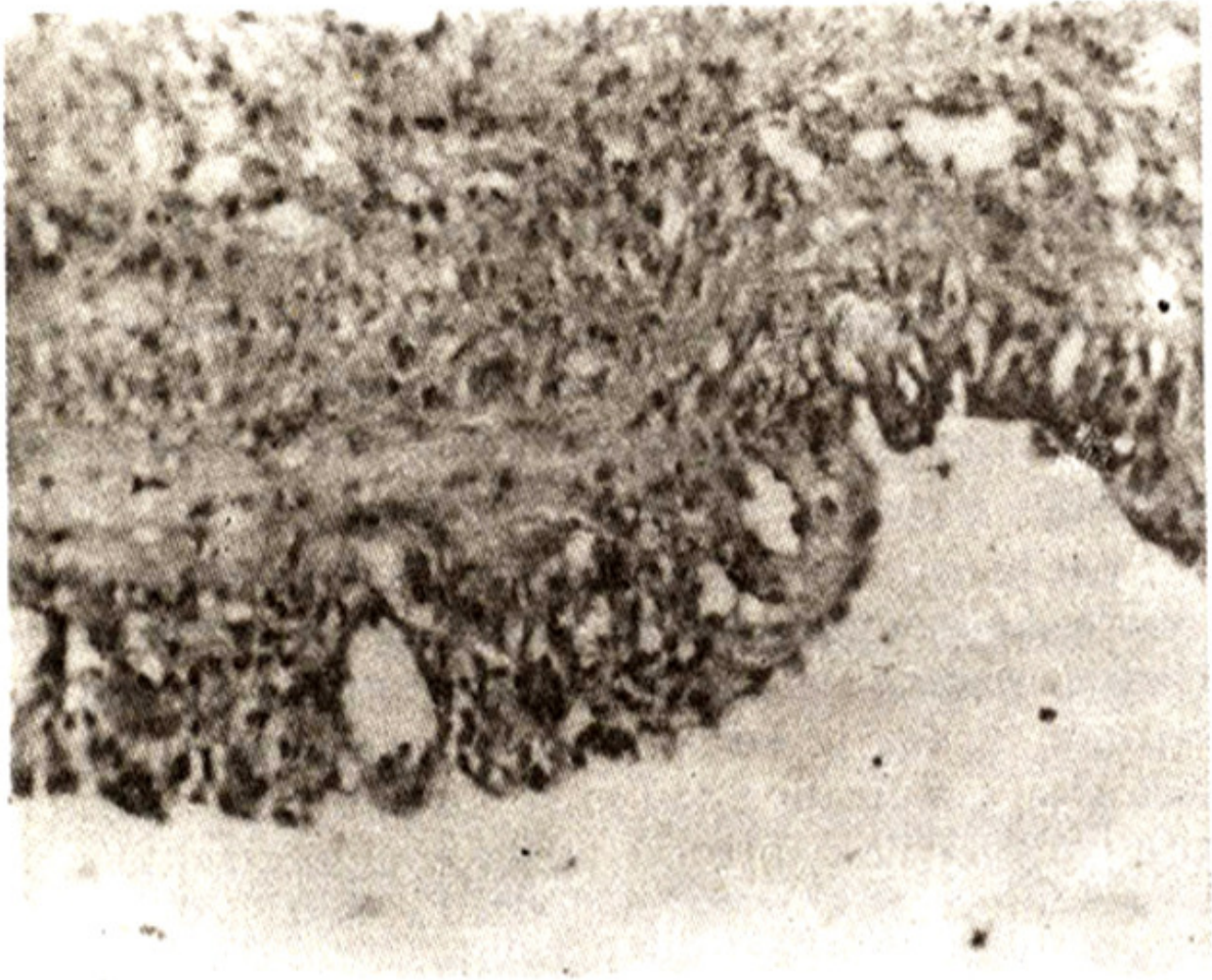


Figure 1. Photomicrograph showing wall of a follicular cyst with flattened lining and outer vascular theca zone (Low power view).

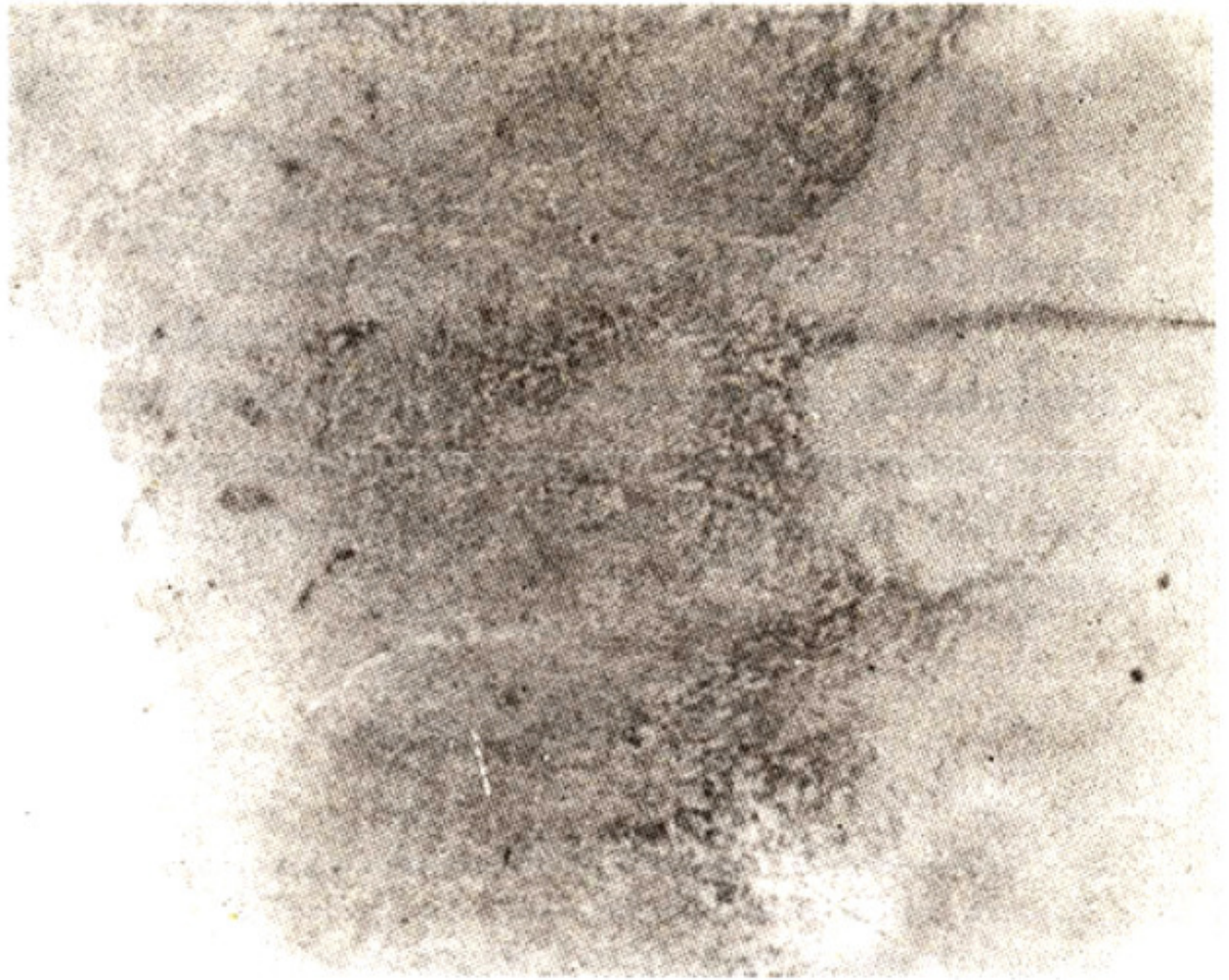


Figure 2. Photomicrograph showing wall of a corpus luteal cyst showing superficial haemorrhagic zone and Pathognomonic convoluted basal shape (Low power view).

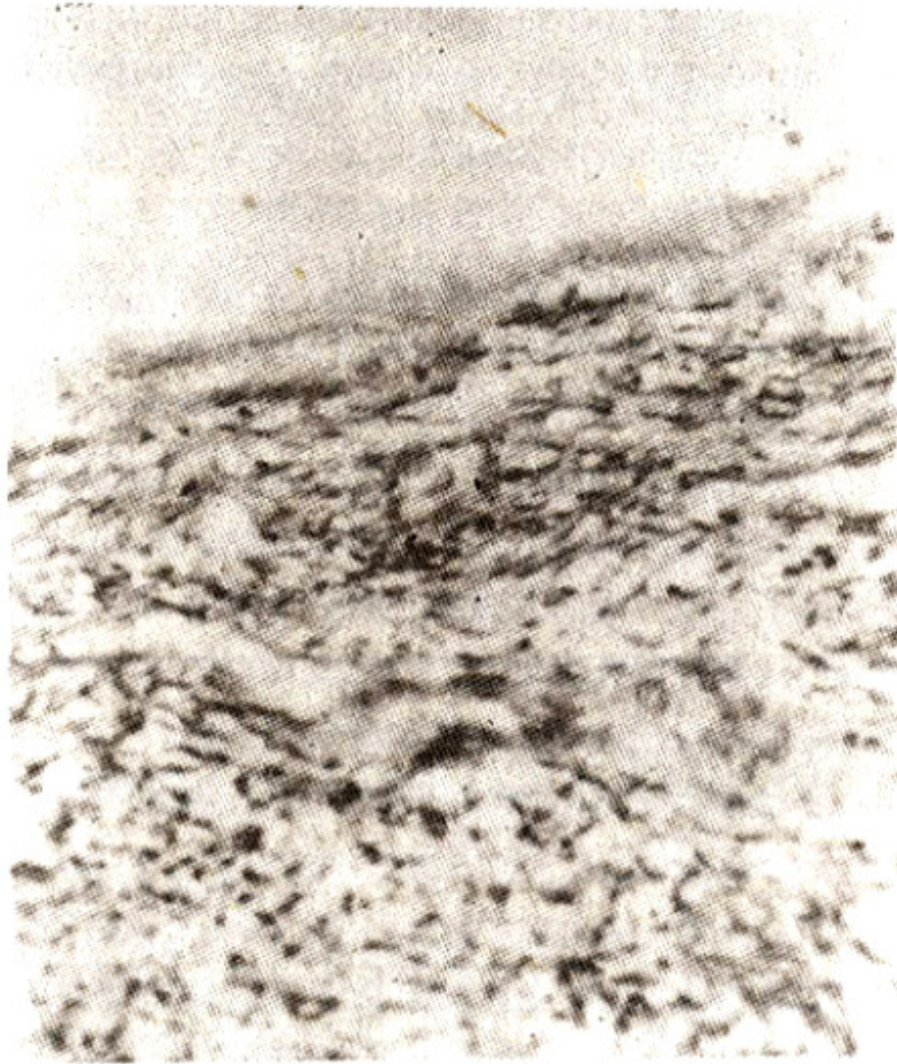


Figure 3. Photomicrograph showing wall of a simple cyst with non descript lining resting over ovarian cortical stroma (Low power view).

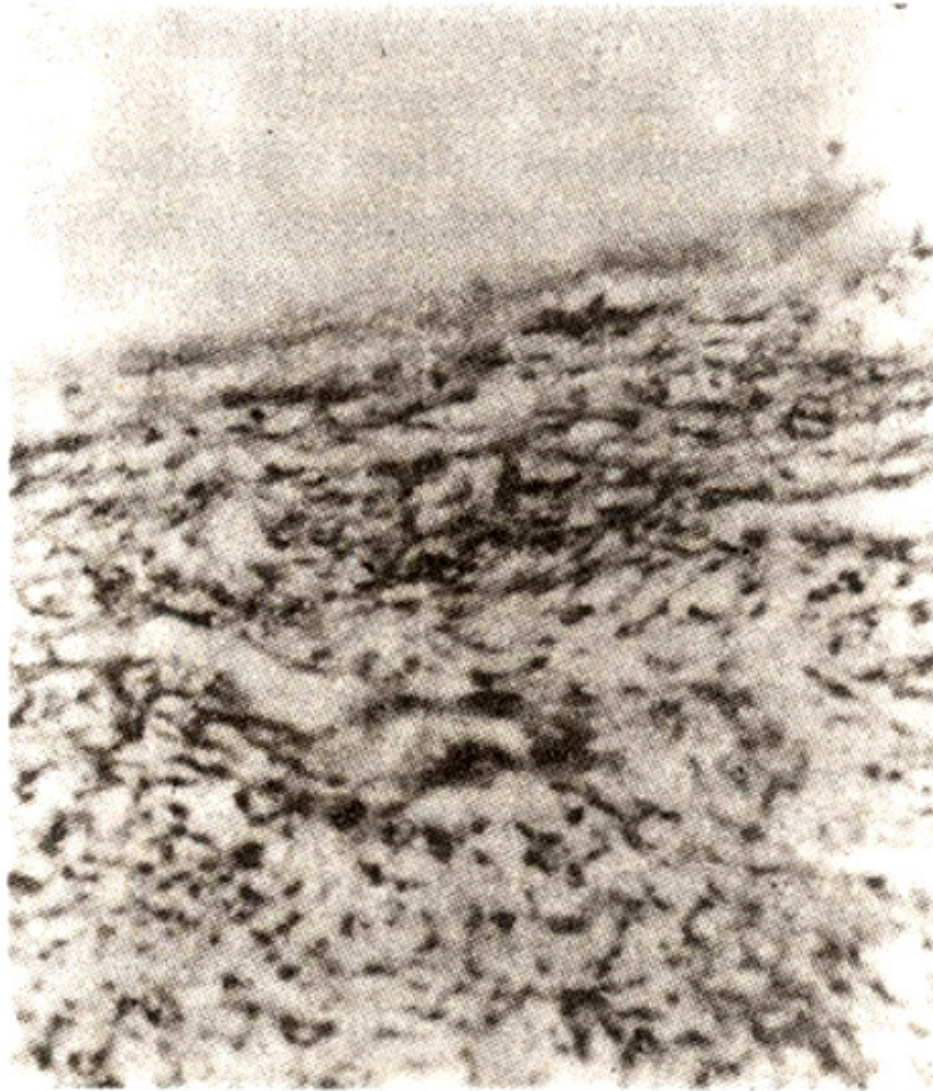


Figure 4. Photomicrograph showing wall of a serous cyst showing single layered lining with collagenous zone underneath (High power view).

### Discussion

In the present study 49.3% “benign” ovarian cysts were diagnosed as neoplastic and 24.8% as dysfunctional. Other studies also support the higher frequency of neoplastic type<sup>5,6</sup>. The size of dysfunctional cysts in the present study ranged between 3.5-10 cm, surgical removal of such cysts is not mandatory and the current trend is to treat them by needle aspiration under ultrasound guidance followed by cytological examination<sup>7</sup>. Cyst measuring more than 5 cm in size are monitored by sequential ultrasound scanning at 6 weekly interval and any increase in size or persistent mass calls for intervention<sup>3</sup>. A conservative management is recommended only if the aspiration cytology confirms the follicular origin of the cyst by revealing granulosa cells and/or estradiol level  $>5$  nmol/l<sup>7</sup>. As reported by others<sup>4</sup> on gross examination external appearance of the cyst wall, the character of its luminal contents and appearance of luminal surface, revealed considerable overlap in different varieties of cysts. Microscopically also, distinction between dysfunctional and neoplastic cysts is problematic

between the follicular cysts and serous cyst adenomas<sup>4</sup>. Haemorrhagic follicular cyst, simple haemorrhagic cyst and/or an endometriotic cyst, can also present overlapping microscopic features<sup>4</sup>. According to present study for the diagnosis of follicular cyst at least focal presence of well recognizable granulosa cell zone or a vascular theca zone is essential. For the corpus luteal cyst convoluted contour of the cyst wall and invaginating theca cells producing wedges at the basal portion of the cyst were the most significant features as reported in previous studies as well<sup>4</sup>. Serous cyst adenoma were the most frequently encountered neoplastic cysts, which is similar to previous reports<sup>8</sup>. Histologically majority of cysts revealed flattened to low cuboidal lining whereas the columnar and typical endosalpingeal type was an infrequent finding which is also supported by other studies<sup>5</sup>. For mucinous cyst adenomas presence of pathognomonic endocervical type of mucous secreting epithelium is essential. Simple cysts are mostly non neoplastic in nature. However, on further exploration, one of our cases turned out to be neoplastic and 3 each of endometriotic and dysfunctional types emphasizing the need for a thorough microscopic evaluation. Still a certain percentage of ovarian cysts remains to be labelled as simple cysts where exact nature cannot be commented upon. The pathologist here is certain only about the non-malignant nature of the cysts. Therefore, despite the strong opposition by Anderson<sup>5</sup> we suggest that the term "simple cyst" should be retained in the nomenclature of benign ovarian cysts. Half of our cases labelled as endometriotic cysts were incidental microscopic findings as they presented with non specific clinical features resembling those encountered in dysfunctional or neoplastic cysts. On gross examination overlapping features with those of any haemorrhagic, neoplastic or dysfunctional cysts were observed thus supporting the previous studies<sup>5</sup>. The definite diagnosis depends on microscopic evidence of well recognized endometrial tissue in the cyst wall. In its absence, the presence of a fibrotic wall with a lining zone of pigmented macrophages is accepted as being suggestive of endometriosis<sup>5</sup>. However, in our study 3 such cases on further exploration turned out to be either neoplastic or dysfunctional types. The converse was also observed as 3 of our cases labelled as simple haemorrhagic cysts revealed unequivocal endometriotic foci on further blocking. This emphasises the need for ample sampling of suspected endometriotic cysts. To conclude considering the differing clinical implications of neoplastic and dysfunctional cysts, Pathologist must thoroughly sample the benign ovarian cysts for a more specific categorization. Conservative management of dysfunctional cyst needs to be promoted in our country by introducing an ultrasound directed aspiration procedure.

## References

1. Caroly, W. and Colleen, J.G.C. Benign ovarian cysts in England and Wales and in the United States. *Br. J. Obstet. Gynaecol.*, 1992;99:329-32.
2. Susan, I.W., Barbara, B.G., More, R.E. et al. Prevalence of simple adenexal cysts in post-menopausal women. *Radiology*, 1991; 180:65-69.
3. Lachlan, D.C., Hugh, P., Rin Ruth, A. et al. The 'simple' ovarian cyst: aspirate or operate? *Br. J. Obstet. Gynaecol.*, 1989;96:1035-39.
4. Russel, P. and Bannatyne, P. Dysfunctional cysts. In *surgical pathology of ovaries*. U.K., Churchill Livingstone, U.K., 1989, pp.49-107.
5. Anderson, M.C. Tumour of the ovary 2: Epithelial (serosal) tumours. In: Symmers W.C. and Anderson M.C. ed. *New York, Edinburgh, London, Churchill Livingstone*, 1991, pp.307-318. 268, 270.
6. Bhan, V., Amson, A., Whitehead, C. et al. Characteristics of persistent ovarian masses in asymptomatic women. *Br. J. Obstet. Gynaecol.*, 1989;96: 1384-91.
7. Buckley, C.H. Is needle aspiration of ovarian cysts adequate for diagnosis? *Br. J. Obstet. Gynaecol.*, 1989;96: 1021-32.
8. Fox, H. and Langley, F.A. The classification and incidence of ovarian tumours In *tumours of the*

ovary. London, Heinmann, 1979, p.23.