

Open Label Trial of the Efficacy and Tolerability of Lamisil (Terbinafine 500 mg Once Daily in the Treatment of Onychomycosis Due to Candida

Pages with reference to book, From 258 To 260

Zohra Zaidi, N. Jafri, K.Khan, P. Hasan, N. Kapadia (Department of Dermatology, Jinnah Postgraduate Medical Centre, Karachi.)

Abstract

An open label trial of Lamisil (Terbinafine) 500mg daily for 16 weeks was conducted on 20 patients with Onychomycosis due to candida. Of these, 15 patients could complete the trial. Total number of target nails infected was 21. The follow-up period was from 16 to 52 weeks. At 16 weeks, 71% cases showed clinical improvement and 67% had mycological cure, Thirty-three percent had complete cure at 52 weeks. The results show that Terbinafine is effective against candida but requires a longer duration of treatment. The drug was well tolerated (JPMA 46:258, 1996).

Introduction

Onychomycosis accounts for about 50% of all nail problems¹. The most common pathogens are dermatophytes, but yeast and moulds are also responsible. A number of studies have been done on onychomycosis due to dermatophytes. The results of treatment with allylamines and imidazoles are quite promising². Few studies have been conducted on onychomycosis due to yeast and moulds. In a developing country like Pakistan women do almost all the housework single bandedly and without protection. Mechanical trauma destroys the cuticle and is responsible for invasion of candida into the nail folds, this then leads to onychomycosis². Nails infections caused by candida are mostly associated with chronic paronychia or chronic mucocutaneous candidiasis. Candida has also been isolated from the nails showing primary distal and lateral onycholysis³. Most cases of onychomycosis due to yeast are caused by candida albicans Candida albicans and candida parapsilosis are not keratolytic, but can affect the nail fold and nail plate as pathogens⁴.

Moulds responsible for onychomycosis are also not keratolytic. They live on unkeratinised intercellular cement or take, advantage of partial denaturing of nail keratin by preexisting trauma or nail disease. Unlike dermatophytes, the moulds colonise in the outer layers of the nail, leuconychia trichophyta is the common manifestation of this nail infection⁴.

Terbinafine has a broad spectrum of activity against dermatophytes, yeasts moulds and dimorphic fungi. In vitro activity is strongest against dermatophytes and as per gillosis. It is fungicidal against candida paTapSiiOsiS but fungistatic against candida albicans. C.andida albicans in mycelial form is inhibited at 0.26 ug/ml which is easily achieved with therapy in the nail as well as in the stratum corneum of skin⁵. This study reports an open trial of this drug onychomycosis due to candida.

Patients and Methods

Twenty patients above the age of 18 years v examined locally and systemically at first visit and evaluation for onychomycosis due to candida. They had clinical evidence of onychomycosis and a positive culture for candida. clinical parameters were paronychia, onycholysis and hyperkeratosis. They were rated by means of a 4- point scale absent, 1=mild, 2=moderate, 3=severe). They did not have recent oral or

topical antifungal therapy. Pregnant lactating women, patients with diseases that impair absorption of the drug from the gastrointestinal tract and those with systemic disorder were excluded. All patients were given Terbinafine 500 mg orally 16 weeks - They were then seen at 4 weeks interval till 12 weeks and at 6 weeks interval till 52 weeks. At each visit local and mycological examination of the target nail (infected nail) was done. Blood was examined for haematoh and biochemistry at the first visit and then at 16 weeks which the active therapy was stopped. The investigations done were serum creatinine, uric acid, potassium, SGOT, SGPT, Lt Gamma GT, alkaline phosphatase, total bilirubin, cholesterol and triglycerides. Urine was examined for protein glucose. The proportion of the affected nail was graphically recorded. The length of the unaffected nail was measured each clinical examination. If the clinical parameters showed signs of improvement and the length of the unaffected nail increased on each examination; it signified that the drug was effective. Clinical cure was considered when the nails appeared normal. At each mycological examination, the nails were examined for both microscopy and culture. Nail samples were taken with the help of a dental drill. They were treated with 20% KOH, using gentle heat when required. The presence of budding yeast, mycellium of both were noted. Nail material was cultured on Sabouraud's dextrose agar without chlorhexamide for candida and mycobiotic agar for dermatophytes. Plates were examined after 3-5 days for candida, and 1-2 weeks for dermatophytes. Tubes showing no growth were discarded after 4 weeks of incubation. Candida isolated were identified by the chlanwospore formation and biochemical reaction. Mycological cure was considered when the nails were negative both on microscopy and culture and complete cure when the nails had both clinical and mycological cure.

Results

Of the 20 patients enrolled in the study, only 15 could complete it as 3 dropped out due to non-compliance and 2 showed a mixed infection at 4 weeks examination.

Table. Clinical profile.

Total patients	15
Male Female ratio	1:4
Age range	20-65 years
Mean age range	38 years
Range of duration of infection	18-122 months
Mean duration of infection	62 months
Total target nails	21
Target finger nails	15
Target toe nails	6
Nails with paronychia	12
Nails with onycholysis	9
Causative organism	<i>Candida albicans</i>

The Table shows the clinical profile of the patients. The total number of target infected nails was 21. Of these, 12 had paronychia. The clinical and mycological evaluation is shown in Figure 1.

TREATMENT PERIOD

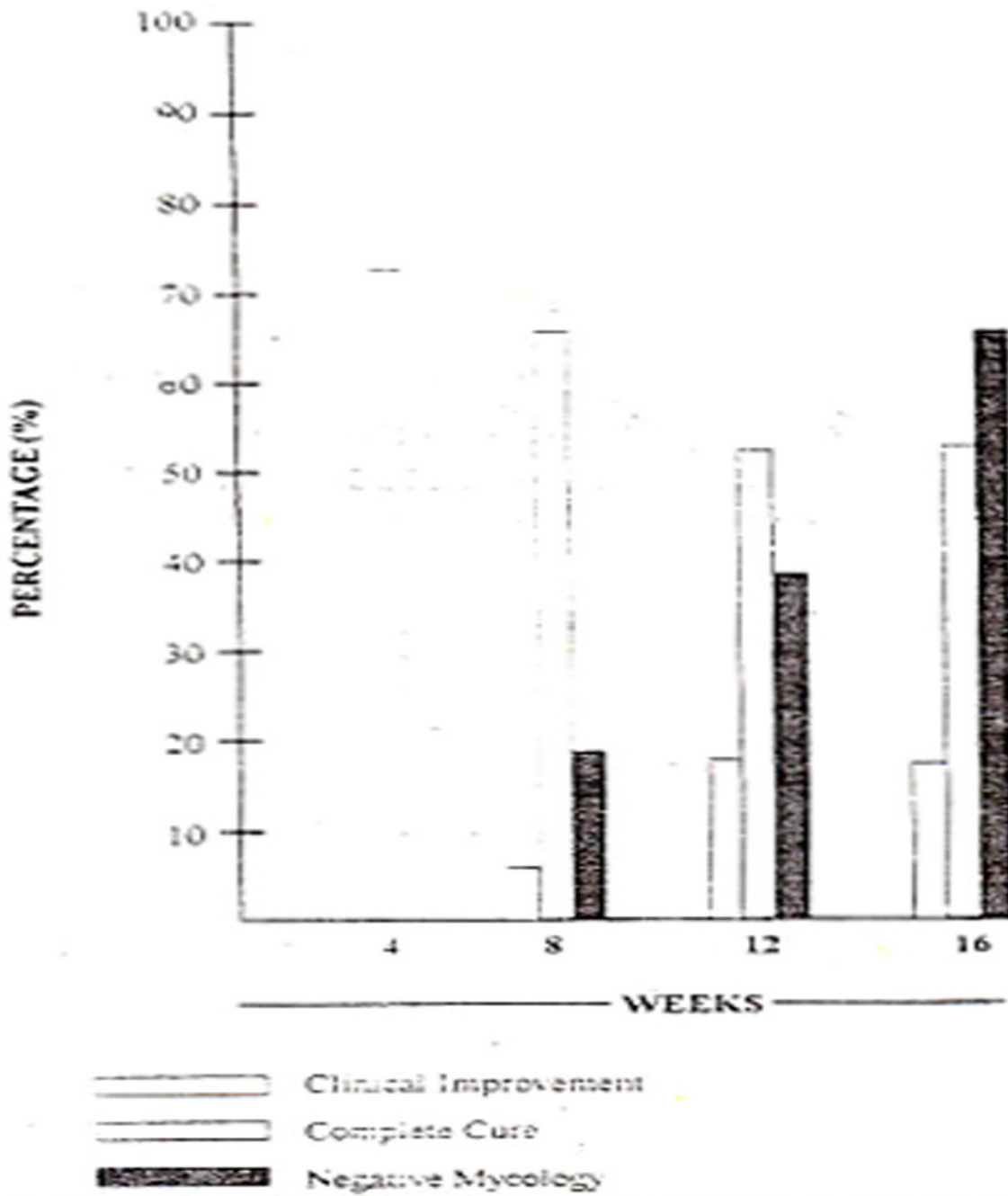


Figure 1. Mycological and clinical evaluation.

The therapy was stopped at 16 weeks after which 3 more nails had mycological cure at 22, 28 and 40 weeks. The clinical evaluation of the therapy can be seen in Figure 2.

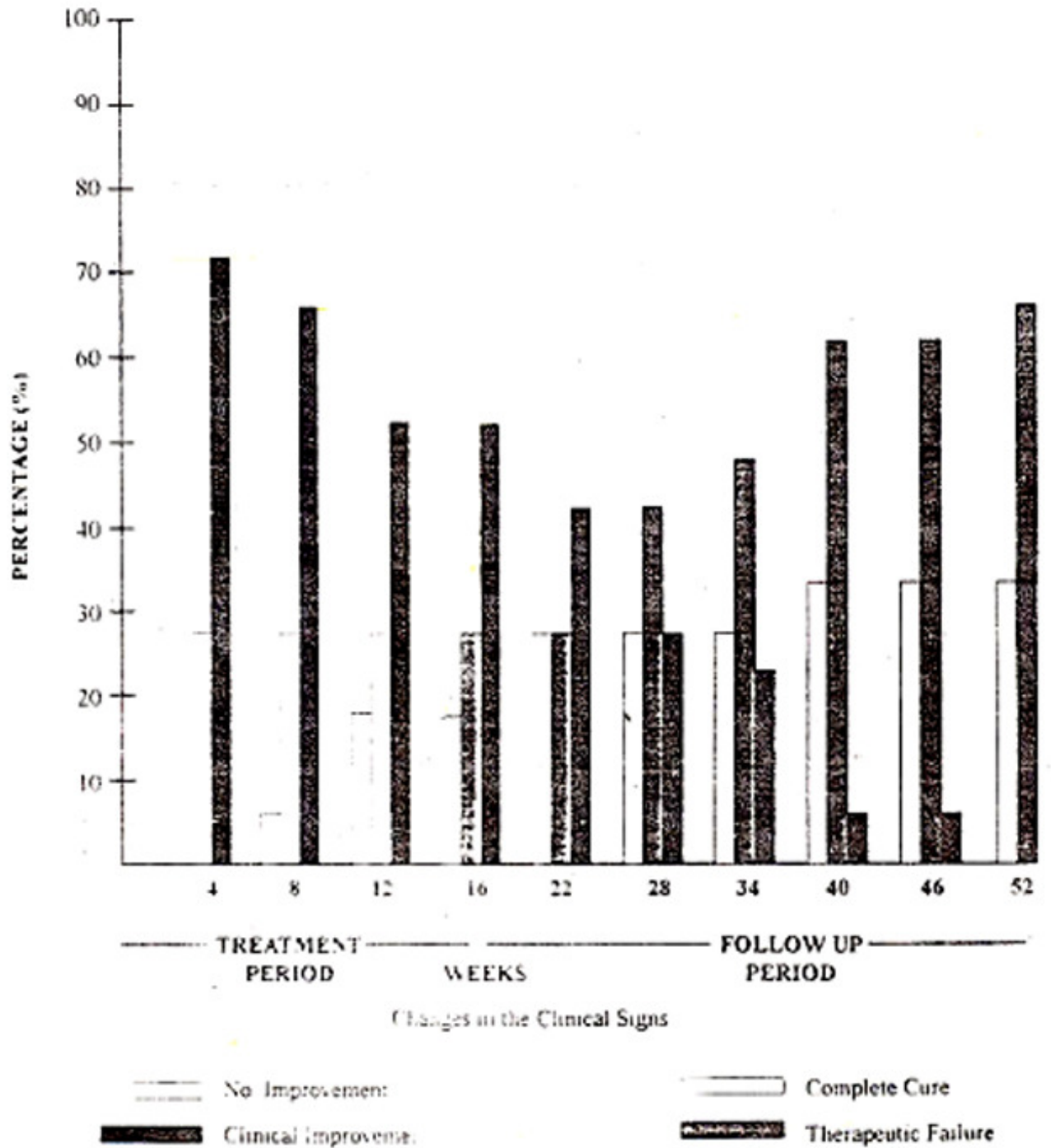


Figure 2 Clinical evaluation.

Of the 11 nails with mild improvement, 3 had a complete cure at 22,28 and 40 weeks whereas 8 cases relapsed. Complete cure at 52 weeks was 33%, The drug was well tolerated, only 1 patient had epigastric pain which did not require withdrawal of therapy.

Discussion

Twenty-one target nails were examined for onychomycosis due to candida (Finger nails 15. toe nails 6).

Candida albicans was the only pathogen in our study. In a previous study, *Candida albicans* was responsible for 97.5% of cases⁶. Chronic paronychia is usually confined to finger nails and so is onychomycosis due to *Candida albicans*⁴. *Candida parapsilosis* on the other hand is not associated with chronic paronychia. Infection with dermatophytes and moulds are more common in the toe nails⁴. Chronic paronychia was present in 12 finger nails. The rest of the target nails had mild to moderate onycholysis. None of our patients had any gross systemic abnormality. This shows that *Candida* can infect nails with onycholysis^{2,4}.

Mean age range in our patients was 38 years and mean duration of infection was 62 months. Most of our patients were housewives who could not avoid working with water nor could they afford any proper protection to their nails because of poverty. Perhaps if the treatment was started early and proper protection provided, the results of the treatment could have been better. The right thumb nail was the most common nail affected in our study. The right middle finger has been reported as the most common nail affected in previous studies. Three target nails showed moderate improvement at 16 weeks and complete cure was seen after stopping of therapy during the follow-up period. This shows the residual effect of the drug. Terbinafine is both keratophilic and lipophilic. It therefore, persists in the nail even after withdrawal of therapy^{7,8}. The drug was well tolerated. Only one patient had epigastric pain, which did not require withdrawal of therapy. In most studies the drug has been well tolerated⁹⁻¹¹.

Terbinafine was effective against *Candida albicans*. In our study the drug was given for 16 weeks. Onychomycosis due to *Candida*, was treated from 28-48 weeks by other workers^{3,4}. The activity of terbinafine against *Candida* organisms observed in clinical studies is somewhat better than predicted by these in vitro findings. This relatively high level of clinical efficacy is attributable to inhibition by the Terbinafine of pseudohyphal growth of *Candida* which is thought to be associated with pathogenesis. This form of organism is known to be suppressed with a Terbinafine concentration considerably lower than that required for inhibition in the yeast form⁷.

References

1. Scher, R. K. Onychomycosis is more than a cosmetic problem. *Br. J. Dermatol.*, 1994;130(Suppl 43):15.
2. Barlow, A.J. E., Chattaway. F.W., Holgate, MC. et al. Chronic paronychia. *Br. J. Dermatol.* 1970;82:448-453.
3. Hay. R.J., Baran, R., Moore, M.K. et al. *Candida* onychomycosis. An evaluation of the role of *Candida* species in nail disease *Br. J. Dermatol.*, 1988;1 18:47-58.
4. English, M.P. Nails and Fungi *Br J. Dermatol.*, 1976,94.697-701.
5. Nolting, S., Brantingham, M. and Weidinger, G Terbinafine in onychomycosis with involvement by non-dermatophyte fungi. *Br. J. Dermatol.*, 1994,130 (Suppl43): 16-21.
6. Marten, R.H. Chronic paronychia. *Rr.J Derrnatol* 1959;71:422-426.
7. Bnnbaum, J.E. Pharmacology of allylamines. *J. Am Acad. Dermatol.*, 1990,23:782-785.
8. Ryder. N.S. Squalene epoxidase as the target of antifungal allylamines. *Pesticide Science*, 1987;21:281-288.
9. Jones, T.C. and Villars, V Present status of the efficacy and tolerability of terbinafine (Lamisil) used systemically in the dermatomycosis of the skin and nails. *3. Dermatol. Treat.*, 1990,1 :(Suppl)2;33-38.
10. Goodfield. M.J.D.. Rowell, KR., Forster, R.A. el al. Treatment of dematophyte infection of the finger and toe nails with terbinafine (SF 86-327) lamisil an orally active fungicidal agent *Br. 3. Dermatol.*, 1989;121:753-757.
11. Rosselet, F.B., Rakosi, T. Wili PB: etal Treatment of onvechomycosis with terbinafine *Br. J Dcrmatol.*, 1992;126:Suppl 39:40-46.