

Valproic Acid Induced Hyperammonaemic Encephalopathy

Saima Amanat, Naila Shahbaz, Yasmin Hassan

Abstract

Objective: To observe clinical and laboratory features of valproic acid-induced hyperammonaemic encephalopathy in patients taking valproic acid.

Methods: Observational study was conducted at the Neurology Department, Dow University of Health Sciences, Civil Hospital, Karachi, from February 26, 2010 to March 20, 2011. Ten patients on valproic acid therapy of any age group with idiopathic or secondary epilepsy, who presented with encephalopathic symptoms, were registered and followed up during the study. Serum ammonia level, serum valproic acid level, liver function test, cerebrospinal fluid examination, electroencephalogram and brain imaging of all the patients were done. Other causes of encephalopathy were excluded after clinical and appropriate laboratory investigations. Microsoft Excell 2007 was used for statistical analysis.

Results: Hyperammonaemia was found in all patients with encephalopathic symptoms. Rise in serum ammonia was independent of dose and serum level of valproic acid. Liver function was also found to be normal in 80% (n=8) of the patients. Valproic acid was withdrawn in all patients. Three (30%) patients improved only after the withdrawal of valproic acid. Six (60%) patients improved after L-Carnitine replacement, one (10%) after sodium benzoate. On followup, serum ammonia had reduced to normal in five (50%) patients and to more than half of the baseline level in two (20%) patients. Three (30%) patients were lost to followup after complete clinical improvement.

Conclusion: Within therapeutic dose and serum levels, valproic acid can cause symptomatic hyperammonaemia resulting in encephalopathy. All patients taking valproic acid presenting with encephalopathic symptoms must be monitored for the condition.

Keywords: Hyperammonaemia, Valproic acid, Encephalopathy. (JPMA 63: 72; 2013)

Introduction

Valproic acid is a broad-spectrum anti-epileptic drug that has been used in the treatment of different types of partial and generalised epileptic seizure, bipolar and schizo-affective disorders, neuropathic pain, as well as for the prophylaxis of migraine headache.¹

Valproic acid-induced encephalopathy is a rare phenomenon. Search of local data also revealed very few case reports of valproic acid-induced encephalopathy.² This may occur in people with normal liver function, with normal doses and normal serum levels of valproic acid.³ Increased free levels of valproic acid despite normal total serum levels might explain the development of hyperammonaemia.⁴ Encephalopathy is typically characterised by acute onset of impaired consciousness, focal neurologic symptoms and increased seizure frequency.^{5,6}

The rationale of our study was based on the frequent use of valproic acid in our setting and lack of enough local data regarding this serious but potentially treatable side

.....
Department of Neurology, Dow University of Health Sciences and Civil Hospital, Karachi.

Correspondence: Saima Amanat. Email: dr.saimakashif@gmail.com

effect of valproic acid. We decided to conduct this study on all patients with symptoms of valproic acid-induced encephalopathy who presented to our department.

Patients and Methods

During the observational study which was conducted at the Department of Neurology, Dow University of Health Sciences, Civil Hospital, Karachi, all patients with epilepsy, idiopathic or symptomatic, who were on valproic acid therapy and developed encephalopathic symptoms and signs, were followed up from February 26, 2010 to March 20, 2011. None of the patients had prior clinical evidence of metabolic urea cycle disorder. Onset of encephalopathic symptoms had close temporal relationship with either the initiation of valproic acid therapy or the escalation of its dose. Blood ammonia level, serum valproic acid level, liver function test, cerebrospinal fluid examination, electroencephalogram and brain imaging of all patients were performed.

Other causes of encephalopathy, like non-convulsive or sub-clinical seizures, septicaemia, electrolyte imbalance, uraemia, hepatic failure, thyroid disorders, vitamin B deficiency, cerebrovascular insults, trauma, and other drug toxicities were excluded after appropriate clinical and laboratory investigations.

Valproic acid was fairly rapidly withdrawn in all cases compared to our usual routine withdrawal of the anti-epileptic drug. Simultaneous alternative therapy according to the seizure type was instituted.

Patients who showed no signs of or slow recovery from encephalopathic symptoms were treated mostly with L-carnitine 100mg/kg/day for 10 days to reduce blood ammonia levels. One patient was given sodium benzoate for two weeks after consultation with the referring paediatrician who sought our opinion to ascertain the cause of encephalopathy.

Blood ammonia levels were re-checked approximately two weeks after the discontinuation of valproic acid therapy.

Results were analysed on Microsoft Excell 2007. Using SPSS version 16.

Scatter graphs were plotted between the values of serum ammonia level and liver enzymes, dose of valproic acid and serum ammonia level, serum valproic acid and serum ammonia level.

Results

Out of 10 patients 3(30%) were female and 7(70%) were male. All patients were on valproic acid; 3(30%) of them were using one more antiepileptic; while 2 (20%) were using two other antiepileptics along with valproic acid.

Six (60%) patients were diagnosed cases of idiopathic epilepsy. One (10%) patient had mental retardation with epilepsy, the cause of which could not be determined. In the rest of the three (30%) cases, causes for symptomatic epilepsy were, sub-acute sclerosing panencephalitis, postencephalitic sequel and myoclonic encephalopathy. The ages ranged between 5 and 26 years, with a mean of 12.15 ± 6.85 years.

Encephalopathic symptoms, including recent and progressive change in cognition, sensorium or behaviour in various combinations, were present in all the patients.

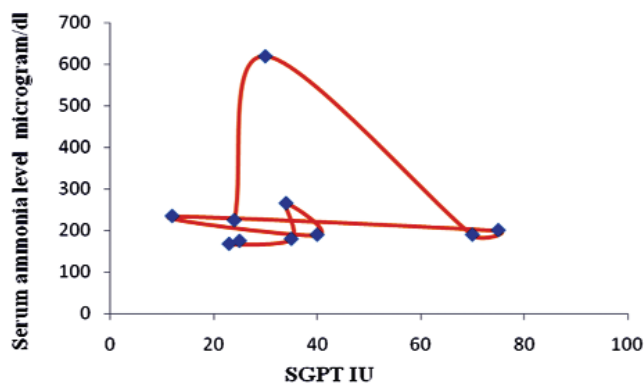


Figure-1: Relationship between rising serum ammonia and liver enzymes.

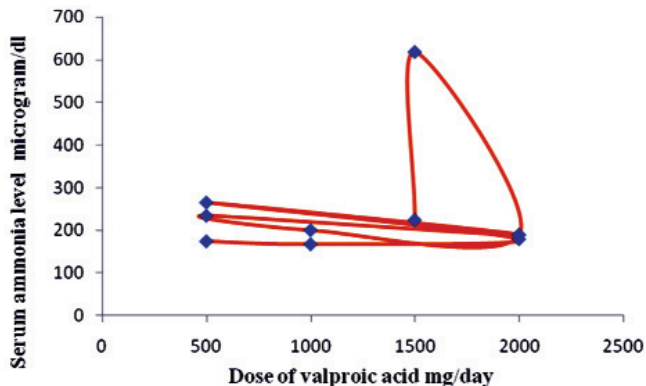


Figure-2: Relationship between Hyperammonaemia and dose of valproate.

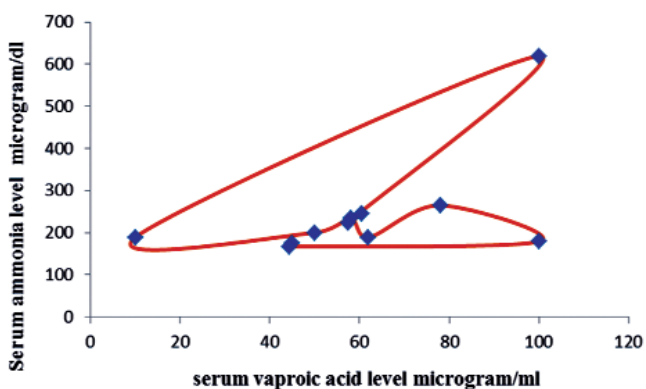


Figure-3: Relationship between Hyperammonaemia and serum valproate levels.

Onset of encephalopathic symptoms after initiating valproic acid or increase in its dose ranged between 2 and 21 days, with a mean of 7.8 ± 6.4 days.

Dose of valproic acid ranged between 500-2000mg/day, with a mean of 1250 ± 635 mg/day.

Serum valproic acid levels ranged between 10-100 microgram/ml with a mean of 60.48 ± 38.3 microgram/ml.

Serum ammonia ranged between 167-619 microgram/dl with a mean of 244 ± 135.2 microgram/dl.

The electroencephalograms of 5 (50%) patients showed generalised slowing, whereas frontal intermittent rhythmic delta activity was seen in one (10%) patient; status epilepticus in one (10%) patient and it was normal in the remaining three (30%) patients.

Serum glutamic pyruvic transaminase (SGPT) was normal in 8 (80%) patients, while it was raised in 2 (20%) patients. It ranged between 12-75 IU with a mean of 36.8 ± 20.38 IU.

Three (30%) patients improved only on the withdrawal of valproic acid. Six (60%) patients received L-carnitine and one

(10%) patient received sodium benzoate for 2 weeks Blood ammonia levels returned to normal value in 5 (50%) patients and reduced to more than half of the baseline in two (20%). Three (30%) patients with complete clinical recovery did not turn up for followup blood ammonia levels.

Relationship between SGPT and serum ammonia level was also worked out. Rise in SGPT on the X-axis did not occur with increasing level of serum ammonia on the Y-axis (Figure-1).

Likewise, change in serum ammonia level on the Y-axis did not correlate with the dose of valproic acid on the X-axis (Figure-2).

The relationship between serum valproic acid and serum ammonia level showed that hyperammonaemia on the Y-axis reviewed within therapeutic level (less than 100microgram/ml) of serum valproic acid on the X-axis (Figure-3).

Discussion

Changes in mental status are thought to be due to high levels of ammonia. The brain ammonia concentration can be high even when the serum ammonia level is normal.⁶ Hyperammonaemia can also cause encephalopathy by inhibition of glutamate uptake by astrocytes.⁷

Clinical features of valproic acid-induced hyperammonaemia range from asymptomatic⁵ patients to increase in seizure activity⁸ and even death.⁹ Most of the patients present with confusion, personality change, irritability, ataxia, visual disturbance, lethargy, and somnolence.¹⁰ They may also present with nausea, vomiting, or hyperventilation. We did not observe hyperventilation in any of the patients, but all of the other features were present in various combinations in our patients.

Patients with urea cycle disorders can also present with hyperammonaemic encephalopathy. None of our patients had premorbid clinical evidence of urea cycle disorders like failure to thrive in neonatal period, hyperactive behaviour or self injurious behaviour, previous episodes of encephalopathy with repeated vomiting, lethargy and delirium after high-protein diet, exhaustion or febrile illnesses. Women who are carriers of the urea cycle defect are at risk for developing hyperammonaemia during the postpartum period.¹¹

None of our patients had pre-existing mitochondrial disorder. If a patient has a known mitochondrial disorder, then valproate should be avoided, as the risk of hyperammonaemic encephalopathy are high in these patients.¹²

Though uncommon, a possible induction of non-convulsive status epilepticus by valproate-induced hyperammonaemic encephalopathy should be taken into account and properly managed by the discontinuation of the drug.¹³ This was the case in one of our patients: a 12-year-old child, with history of two generalised seizures in the preceding 6 months, but without any treatment, presented with 8 days' history of recurrent seizures and confusional state and inattentiveness during the interictal period. Her electroencephalography (EEG) showed non-convulsive status epilepticus during the interictal period; magnetic resonance imaging of the brain, cerebrospinal fluid (CSF) analysis, complete haematologic, metabolic (including plasma ammonia) and serologic workup turned out to be normal. She was loaded with phenytoin with no apparent clinical improvement. She improved markedly clinically and electrophysiologically with injectable valproic acid but 5 days later again developed confusional state and vomiting. Repeat EEG showed runs of generalised epileptiform discharges. SGPT and serum valproic acid was normal but serum ammonia was 224. Again, improvement was noticed after rapid withdrawal of valproic acid and treatment with L-carnitine and alternative anti-epileptic drug.

Rarely, valproic acid-induced encephalopathy may also occur without hyperammonaemia or hypocarnitinaemia. EEG monitoring is an appropriate mean to diagnose this adverse effect.¹⁴

Combination of phenobarbital, phenytoin and topiramate may increase ammonia levels in people taking valproic acid.^{6,15} All these drugs are also known to potentially cause hyperammonaemia when administered alone as well.

In our study, the mean duration of the onset of encephalopathic symptoms was 7.8 days. It usually occurs within a few days of the administration of valproic acid, but some subjects are known to develop valproate-induced non-hepatic hyperammonaemic encephalopathy with chronic therapy.¹⁶

The primary treatment for valproic acid-induced encephalopathy is the withdrawal of valproic acid. Complete recovery generally occurs over a period of 1 day to a few days. Prolonged recovery times have also been reported.²

Valproic acid inhibits the activity of carbamoyl phosphate synthetase I, the first enzymatic reaction in the urea cycle, thereby hindering the excretion of ammonia and raising plasma ammonia levels. Carnitine is a carrier-type molecule required for the transport and oxidation of fatty acids in the mitochondria. Valproic acid is believed to

interact with carnitine in such a manner that the renal excretion of carnitine is enhanced.¹⁷ Also, valproic acid, carnitine, and coenzyme A form intracellular complexes resulting in reduction in fatty acid use for energy needs.¹⁸

In patients with severe urea cycle defects, sodium benzoate can eliminate nitrogen independent of the urea cycle.¹⁹

In our study, rise in liver function was not observed with hyperammonaemia. Previous studies also showed that most cases of hyperammonaemia present with normal liver function.^{20,21} Hyperammonaemia may commonly be caused by liver failure. We, therefore, excluded the possibility of this co-morbidity in our patients by proper investigations.

The study also found that hyperammonaemia did not directly correlate with the dose of valproic acid. However, many researchers have shown that higher doses induce the development of valproic acid-induced hyperammonaemia.^{6,22}

On the contrary, literature review showed that valproic acid-associated hyperammonaemia was mostly found with normal valproic acid serum levels,³ matching the observations in our study.

Conclusion

Valproic acid-induced hyperammonaemic encephalopathy is a serious but potentially treatable side effect of valproic acid. It may develop within the therapeutic dose and serum levels of valproic acid. It should be considered in all patients who develop encephalopathic symptoms while taking valproic acid.

References

1. Wadzinski J, Franks R, Roane D, and Bayard M. Valproate-associated hyperammonaemic encephalopathy. *J Am Board Family Med* 2007; 20: 499-502.
2. Rehman A, Zafar S. Valproate-induced encephalopathy. *J Coll Physicians Surg Pak* 2005; 15: 571-2.
3. Gerstner T, Buesing D, Longin E, Bendl C, Wenzel D, Scheid B, et al. Valproic acid induced encephalopathy-19 new cases in Germany from 1994 to 2003-a side effect associated to VPA-therapy not only in young children. *Seizure* 2006; 15: 443-8.
4. Carr RB, Shewsbury K. Hyperammonemia and Valproic Acid-Induced Encephalopathy. *Am J Psychiatry* 2007; 164: 1912-3.
5. Hamed SA, Abdella MM. The risk of asymptomatic hyperammonemia in children with idiopathic epilepsy treated with valproate: relationship to blood carnitine status. *Epilepsy Res* 2009; 86: 32-41.
6. Hamer HM, Knake S, Schomburg U, Rosenow F. Valproate-induced hyperammonaemic encephalopathy in the presence of topiramate. *Neurology* 2000; 54: 230-2.
7. Vossler DG, Wilensky AJ, Cawthon DF, Kraemer DL, Morgan JD, Caylor LM, et al. "Serum and CSF glutamine levels in valproate-related hyperammonaemic encephalopathy." *Epilepsia* 2002; 43: 154-9.
8. Marescaux C, Warter JM, Micheletti G, Rumbach L, Coquillat G, Kurtz D. Stuporous episodes during treatment with sodium valproate: report of seven cases. *Epilepsia* 1982; 23: 297-305.
9. Triggs WJ, Gilmore RL, Millington DS, Cibula J, Bunch TS, Harman E. Valproate-associated carnitine deficiency and malignant cerebral edema in the absence of hepatic failure. *Int J Clin Pharmacol Ther* 1997; 35: 353-6.
10. Hawkes ND, Thomas GA, Jurewicz A, Williams OM, Hillier CE, McQueen IN, et al. Non-hepatic hyperammonaemia: an important, potentially reversible cause of encephalopathy. *Postgrad Med J* 2001; 77: 717-22.
11. Lipskind S, Loanzon S, Simi E and Ouyang DW. Hyperammonaemic coma in an ornithine transcarbamylase mutation carrier following antepartum corticosteroids. *J Perinatol* 2011; 31: 682-4.
12. Lin CM, Thajeb P. Valproic acid aggravates epilepsy due to MELAS in a patient with an A3243G mutation of mitochondrial DNA. *Metab Brain Dis* 2007; 22: 105-9.
13. Velio?lu SK, Gazio?lu S. Non-convulsive status epilepticus secondary to valproic acid-induced hyperammonaemic encephalopathy. *Acta Neurol Scand* 2007; 116: 128-32.
14. Reif A, Leonhard C, Mössner R, Lesch KP, Fallgatter AJ. Encephalopathy and myoclonus triggered by valproic acid. *Prog Neuropsychopharmacol Biol Psychiatry* 2004; 28: 1061-3.
15. Murphy JV, Marquardt K. Asymptomatic hyperammonemia in patients receiving valproic acid. *Arch Neurol* 1982; 39: 591-2.
16. Verrotti A, Trotta D, Morgese G, Chiarelli F. Valproate-induced hyperammonaemic encephalopathy. *Metab Brain Dis* 2002; 17: 367-73.
17. Camina MF, Rozas I, Castro-Gago M, Paz JM, Alonso C, Rodriguez-Segade S. Alteration of renal carnitine metabolism by anticonvulsant treatment. *Neurology* 1991; 41: 1444-8.
18. Coude FX, Grimber G, Parvy P, Rabier D, Petit F. Inhibition of ureagenesis by valproate in rat hepatocytes. Role of N-acetylglutamate and acetyl-CoA. *Biochem J* 1983; 216: 233-6.
19. Das AM, Illsinger S, Hartmann H, Oehler K, Bohnhorst B, Kühn-Velten WN, Lücke T. Prenatal benzoate treatment in urea cycle defects. *Arch Dis Child Fetal Neonatal Ed* 2009; 94: 216-7.
20. Zaret BS, Beckner RR, Marini AM, Wagle W, Passarelli C, et al. "Sodium valproate-induced hyperammonemia without clinical hepatic dysfunction". *Neurology* 1982; 32: 206-8.
21. Treem WR. "Inherited and acquired syndromes of hyperammonemia and encephalopathy in children. *Semin Liver Dis* 1994; 14: 236-58.
22. McCall M, Bourgeois JA. Valproic acid-induced hyperammonemia: a case report. *J Clin Psychopharmacol* 2004; 24: 521-6.