

Endometrial Ossification

Pages with reference to book, From 117 To 117

Dear Madam, With reference to the article "Endometrial ossification" by Muzaffar et al published in August 1997 issue, we would like to share our experience regarding this rare entity. We have two cases of endometrial ossification in our records. The first patient was a 21 years old woman who presented with excessive yellow coloured vaginal discharge and severe dysmenorrhoea, She gave a history of 16 weeks missed abortion, 4 months back, followed by uterine evacuation, the histopathological results of which were not available. She previously had another abortion of 8 weeks pregnancy one year back, followed by dilatation and curettage. After her recent D & C, her menses had become heavy in the form of fresh bleeding, however, they were regular. She had been married for 2 years and was keen to conceive again. Her general physical and vaginal examination were normal and the cervical os was closed. Ultrasound of pelvis revealed multiple echogenic foci which were compatible with calcified retained products of conception. The patient underwent a D&C and calcified feeling was appreciated on the anterior and right lateral walls of the uterus. Moderate amount of calcified curettings were obtained and the histopathologic examination revealed endometrial tissue, blood clots and bony fragments (Figure).

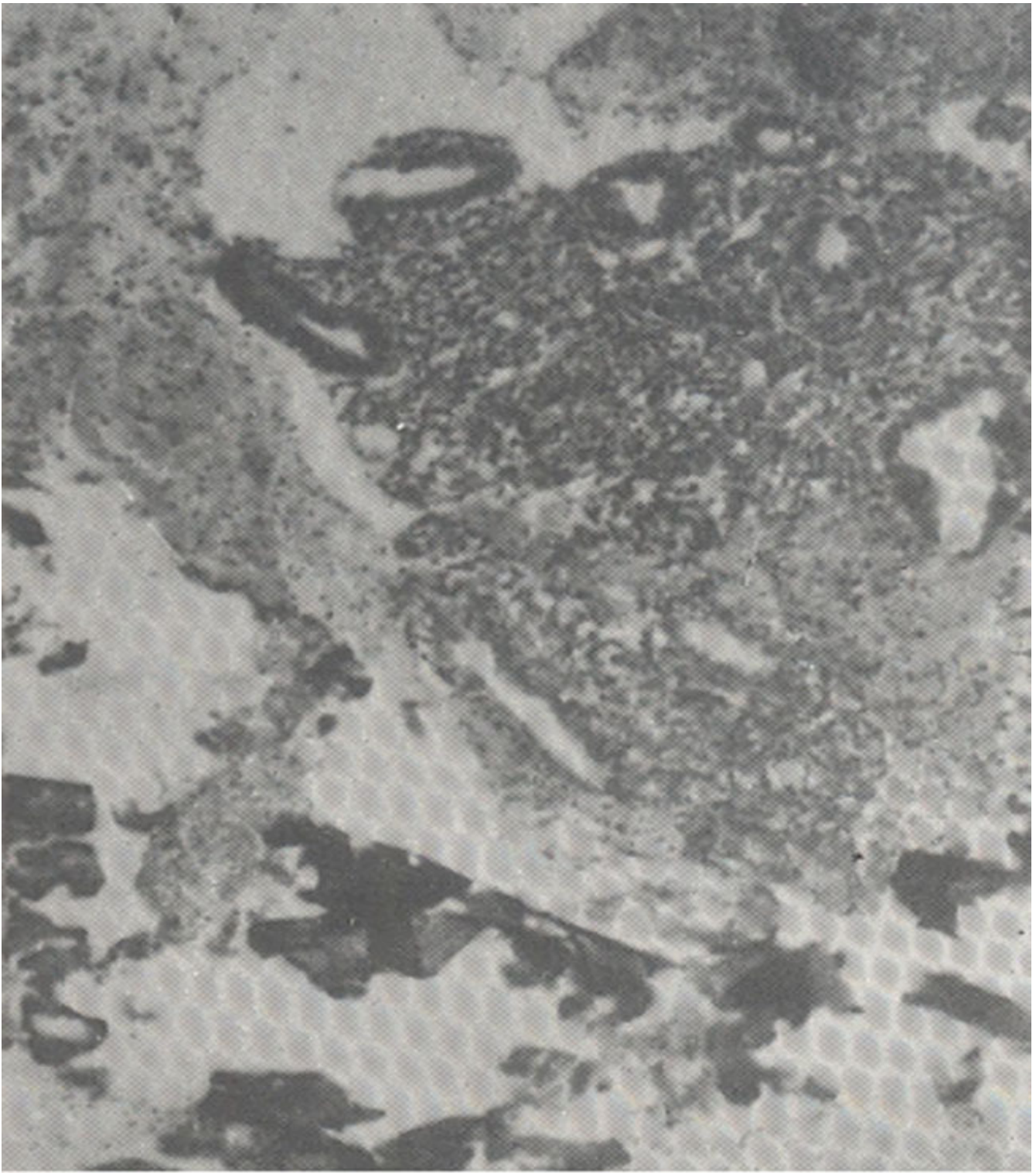


Figure. Microphotograph showing proliferative endometrium, with fragments of mature bone (H & E stain. Mag. x 40).

The endometrium was composed of proliferative phase endometrial glands in a fibrocellular stroma and a dense infiltrate of chronic inflammatory cells including plasma cells. The bony tissue was composed of mature bony trabeculae surrounded by inflammatory cells and occasional multinucleated giant cells. No decidual tissue or chorionic villi were identified. Six months later, the patient again presented with

similar complaints and ultrasound examination revealed ossified areas in the endometrium. A repeat D & C was performed and revealed bony plates firmly adherent to the uterine wall all around. These appeared like mature bony chips on naked eye examination. Histopathologic examination showed endometrial tissue in secretory phase with spindle stroma and dense plasma cell infiltration. Mature bony trabeculae were identified in the endometrial stroma as well as separately. No decidua or chorionic villi were present. Her serum calcium and phosphate levels were within normal range.

The second patient was a 35 years old woman who presented with polymenorrhagia and foul smelling vaginal discharge since one and a half years. She had these problems after her last abortion. The patient was a multiparous woman who delivered 7 children, the last delivery was 3 years back. In addition, there were 6 abortions and she had undergone 2 D & C for incomplete abortions, the last one was one and half years back. The physical and vaginal examinations were unremarkable. Ultrasound examination revealed bulky uterus and the upper part of endometrium appeared thick, dense and echogenic. The patient underwent D & C and noise like breaking of synechae and feeling of separation of anterior and posterior uterine walls heard and felt. Moderate amount of bony curettings were obtained. The bony chips were submitted for decalcification. Histopathological examination revealed fragments of proliferative type endometrium with a fibrocellular stroma and lymphoplasmacytic inflammatory infiltrate. The bony tissue was mainly composed of necrotic bony trabeculae surrounded by acute inflammatory cells. Endometrial calcification and ossification is rarely encountered in endometrial biopsy specimens. The mechanism of endometrial osteogenesis is probably multifactorial and in most cases, either represents the calcified and ossified retained products or osseous metaplasia of the endometrial tissue secondary to chronic endometritis. The past history of abortions in both of our cases is strongly suggestive of ossification of retained products of conception. The associated chronic endometritis in these cases probably acts as an adjunct in the induction of osseous metaplasia. In our cases, both mechanisms probably have induced endometrial ossification.

Slthail Muzaffar, Naveen Faridi, Sadia Ahsan*, Azra Ahsan
Departments of Pathology and Gynaecology*, Liaquat National Hospital, Karachi.