

Percutaneous Nephrostomy: A Non-Operative Management of Urinomas: 2 Case Reports

Pages with reference to book, From 21 To 23

Tanveer-ul-Haq, I.H. Rizvi, Zahid A. Khan, Ateeque A. Khan (Department of Radiology, Aga Khan University Hospital, Karachi.)

Introduction

Uretero-retropitoneal fistulas (urinomas) occur most commonly following penetrating trauma or calculi. Despite the large variety of surgical procedures advocated for the management of ureteral fistulas or urinomas, the results are suboptimal. Conservative treatment by endoscopic placement of indwelling ureteral stents is often preferred^{1,2}. Adaptation of antegrade percutaneous stents offers an excellent conservative method of treatment for patients not suitable for surgery and even for endoscopic placement. PCN has also been used successfully in the management of urinomas^{3,4}.

Case Reports

Case No. 1

A 27 year old male had a road traffic accident. His car rolled over after striking with another vehicle. He had transient loss of consciousness for few minutes at the time of accident. He presented to the emergency room with complaint of right flank pain. There was no associated injury. He was hemodynamically stable. On physical examination, he was a healthy young male, fully conscious and oriented in time, space and person. His blood pressure was 120/70 mm Hg, pulse 80/min and Hb was 12.2 Gm%. Serum creatinine was 1.5 mg%. Mild tenderness was identified in right renal region. Ultrasound showed possible contusion in anteroinferior part of right kidney and small amount of fluid in hepatorenal pouch. IVU examination revealed extravasation of contrast from right renal pelvis and collection of contrast around renal pelvis and proximal ureter (Figure 1).

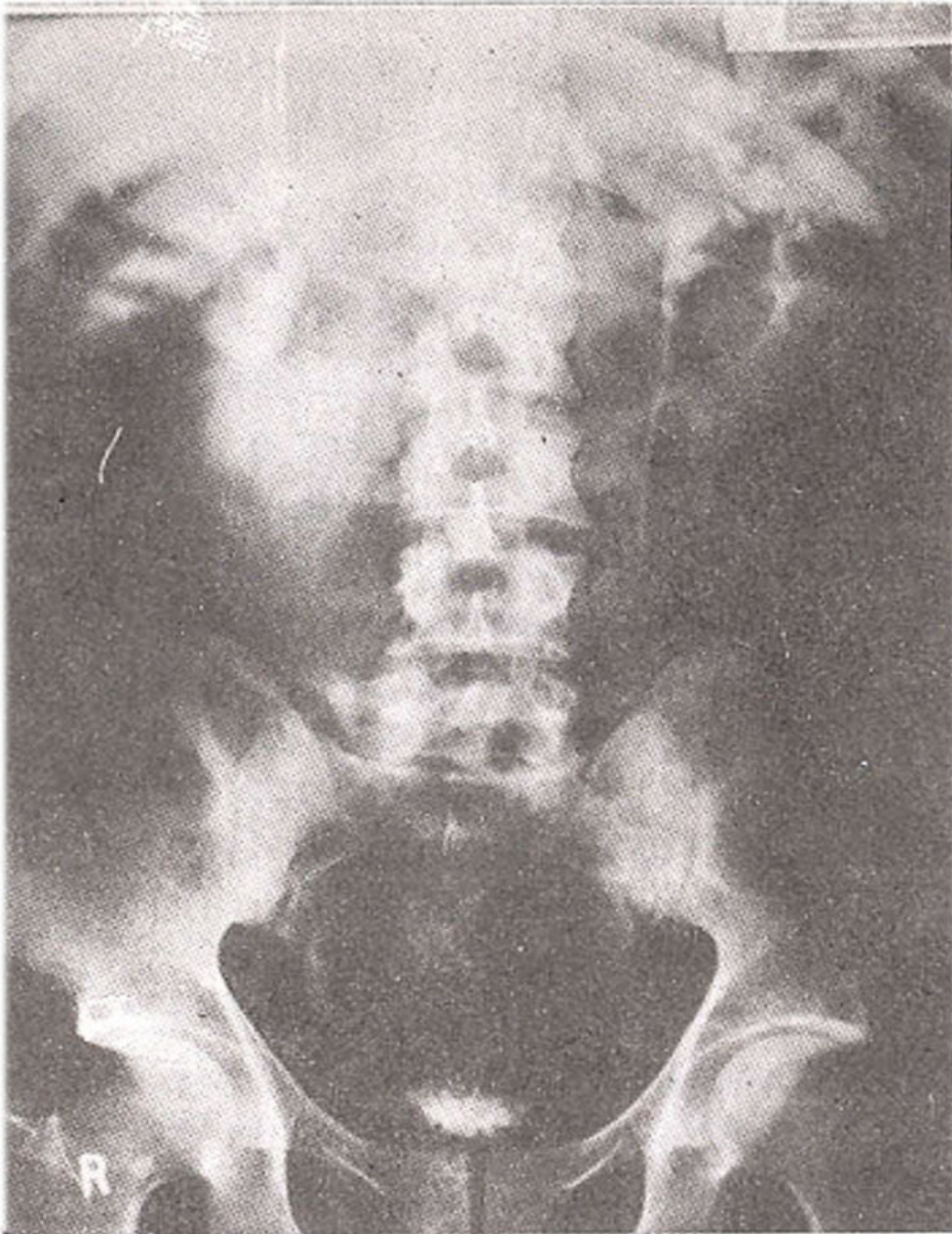


Figure 1. IVU showing extravasation of contrast from right renal pelvis.

Distal ureter was also outlined. This was suggestive of partial rupture of renal pelvis. An oval shaped calculus was also seen in right mid ureter causing partial obstruction and mild dilatation of collecting system. An attempt to insert DJ stent retrogradely was unsuccessful. Later, a percutaneous nephrostomy tube was placed (Figure 2).

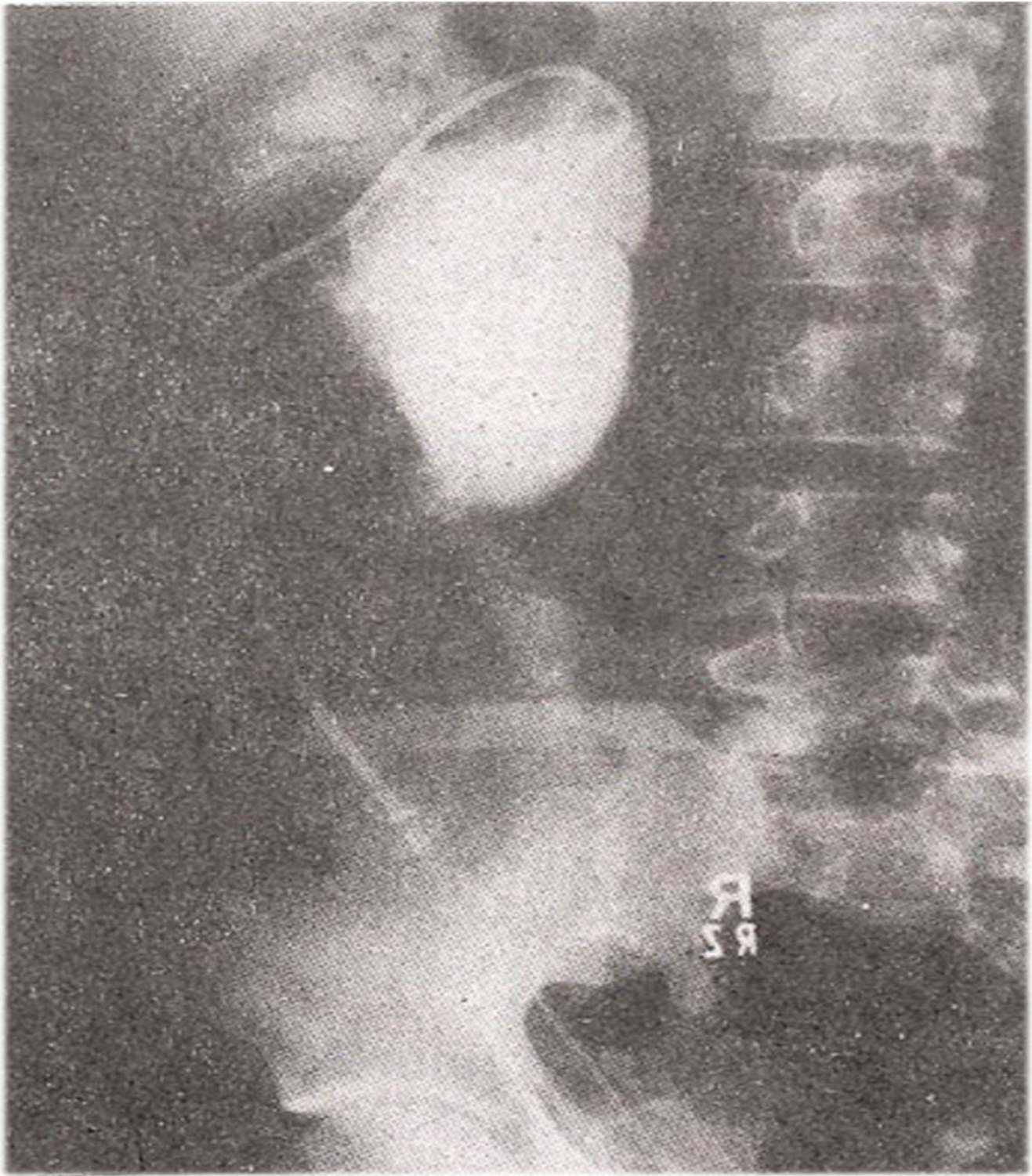


Figure 2. Nephrostogram at the time of nephrostomy showing large urinoma connected with renal pelvis.

Nephrostogram performed two weeks later, showed prompt healing of unnorna (Figure 3)

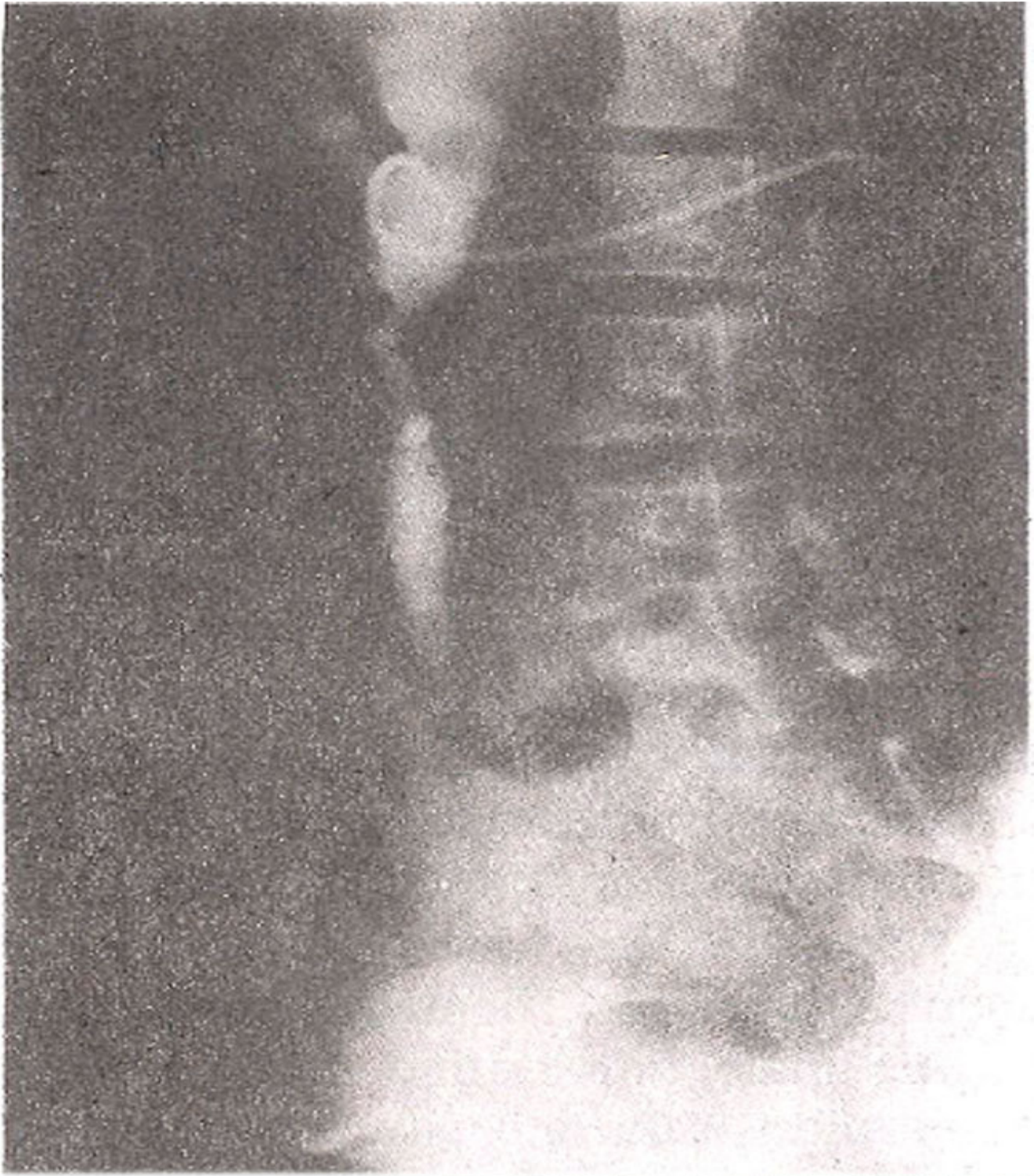


Figure 3. Nephrostogram after 2 weeks showing prompt healing of urinoma. Stone is seen obstruct- ing mid ureter.

Subsequently, a percutaneous DJ stent was inserted for further management of ureteric calculus. DJ stent was placed with the help of special glide (Temmo) wire which passed across the obstruction even in the presence of stone and obstruction.

Case No.2

Sixty years old female known to have diabetes mellitus and hypertension presented in the emergency room with right sided abdominal pain, fever and vomiting for 10 days.

Examination revealed a soft tissue mass on the right side of the abdomen. Initial laboratory investigations showed leucocytosis, elevated levels of blood sugar and urinary tract infection. Ultrasound showed bilateral renal calculi, gross hydronephrosis on right as well as perinephric collection of fluid. Left kidney was shrunken and scarred without any hydronephrosis. A nephrostomy was done on the subsequent day to relieve obstruction. Nephrostomy done during the procedure showed hydronephrosis and extravasation of contrast from the right upper ureter which was filling up a large irregular cavity (Figure 4).

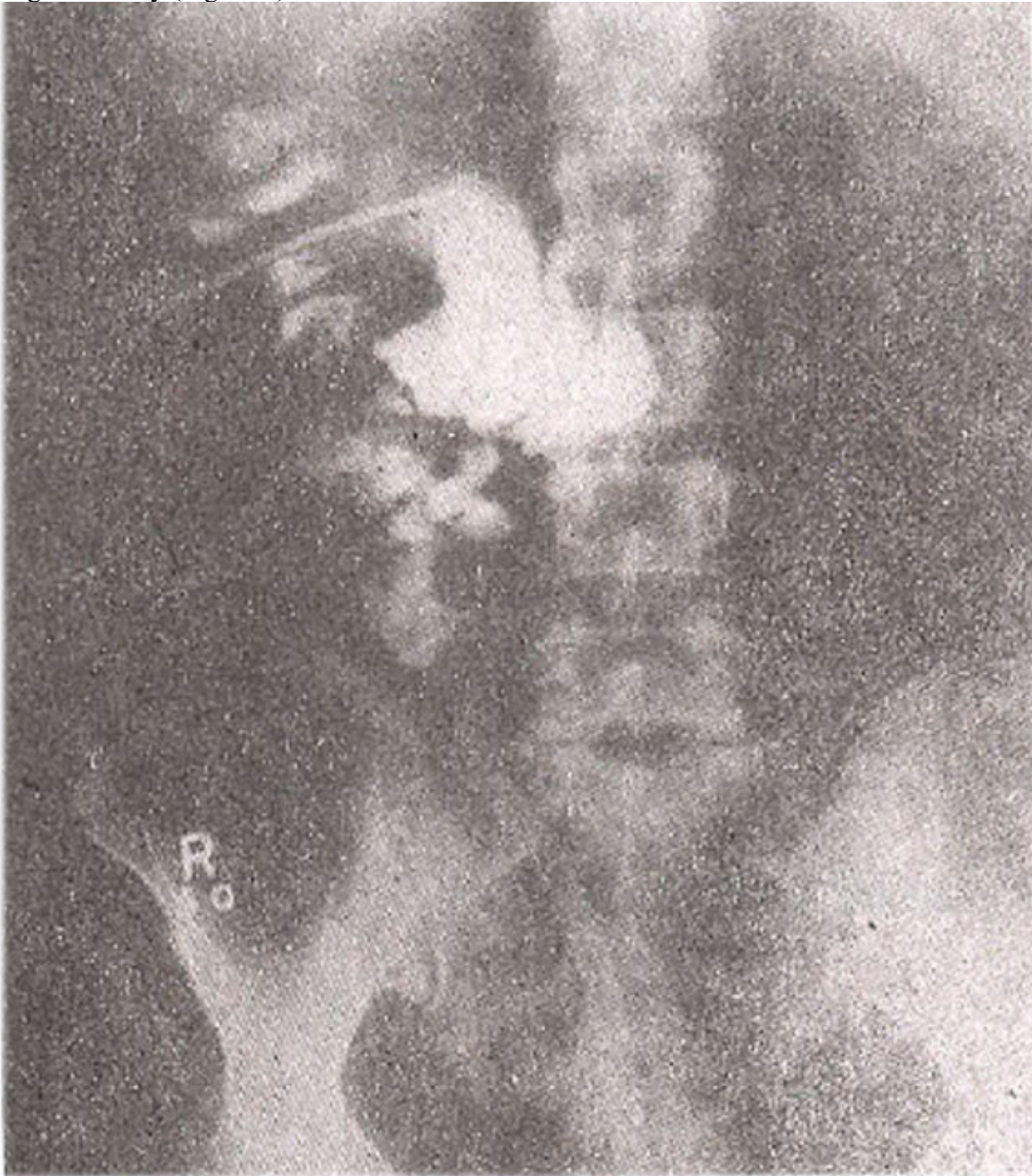

Figure 4. Large extravasation from renal pelvis seen during nephrostomy.

Rest of the ureter could not be delineated. The drained urine was pusy and later grew E. Coli. Patient showed improvement with this treatment. The infection was controlled and her serum creatinine came

down to 5.5 mg% from initial 12.8 mg% in 8 days time. A repeat nephrostogram after a week showed reduced dilatation of the collecting system with better anatomical details and completely obstructed mid ureter by a stone. There was refilling of the cavity which also showed communication with the duodenum (Figure 5).

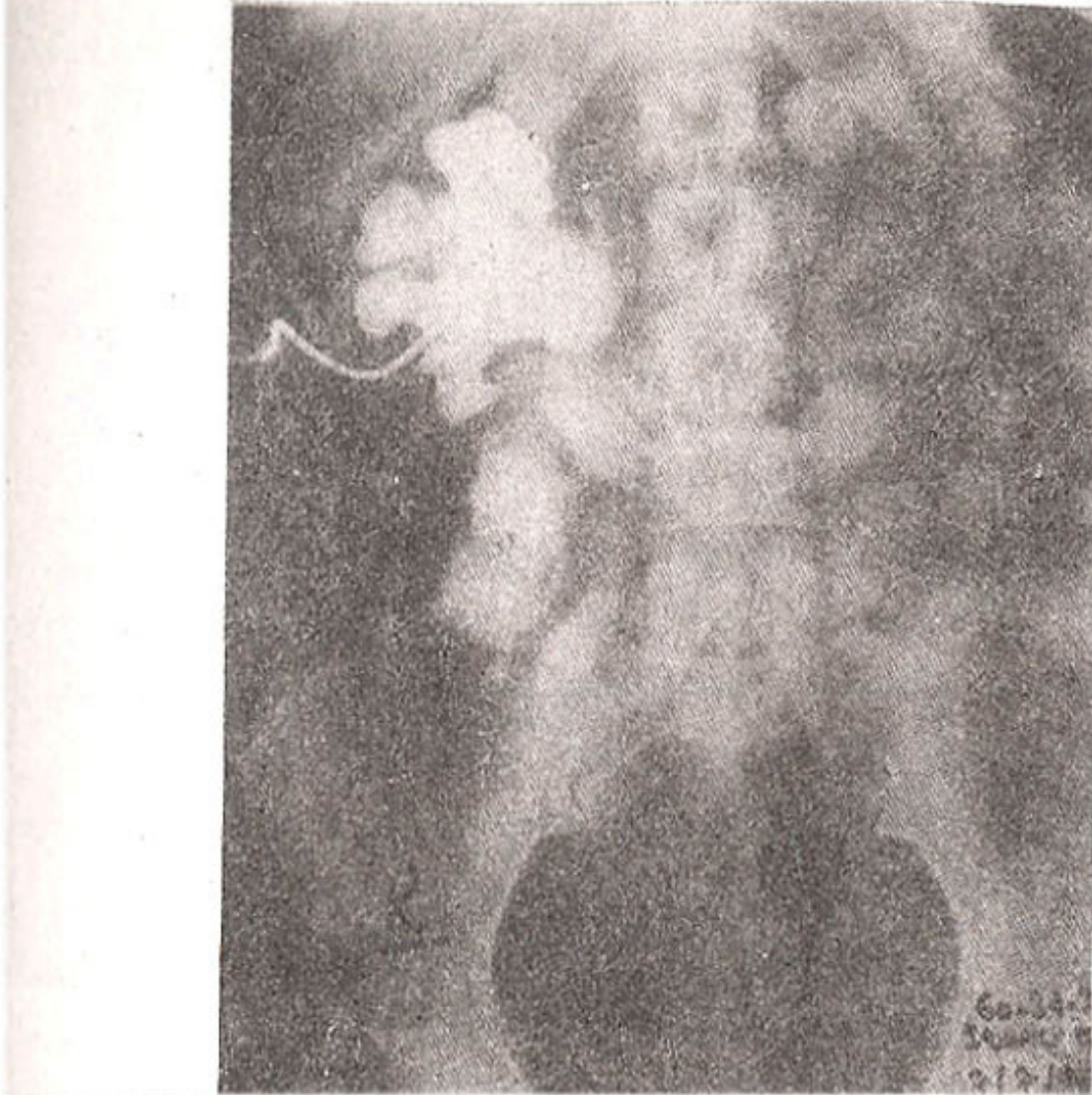


Figure 5. Fistulous communication between urinoma and small bowel wall seen at a later nephrostogram.

It was assumed that the abscess cavity might have burst into the duodenum. Patient was discharged with the nephrostomy and recalled after three weeks for a nephrostogram, which showed complete healing of cavity and enterorenal fistula (Figure 6).

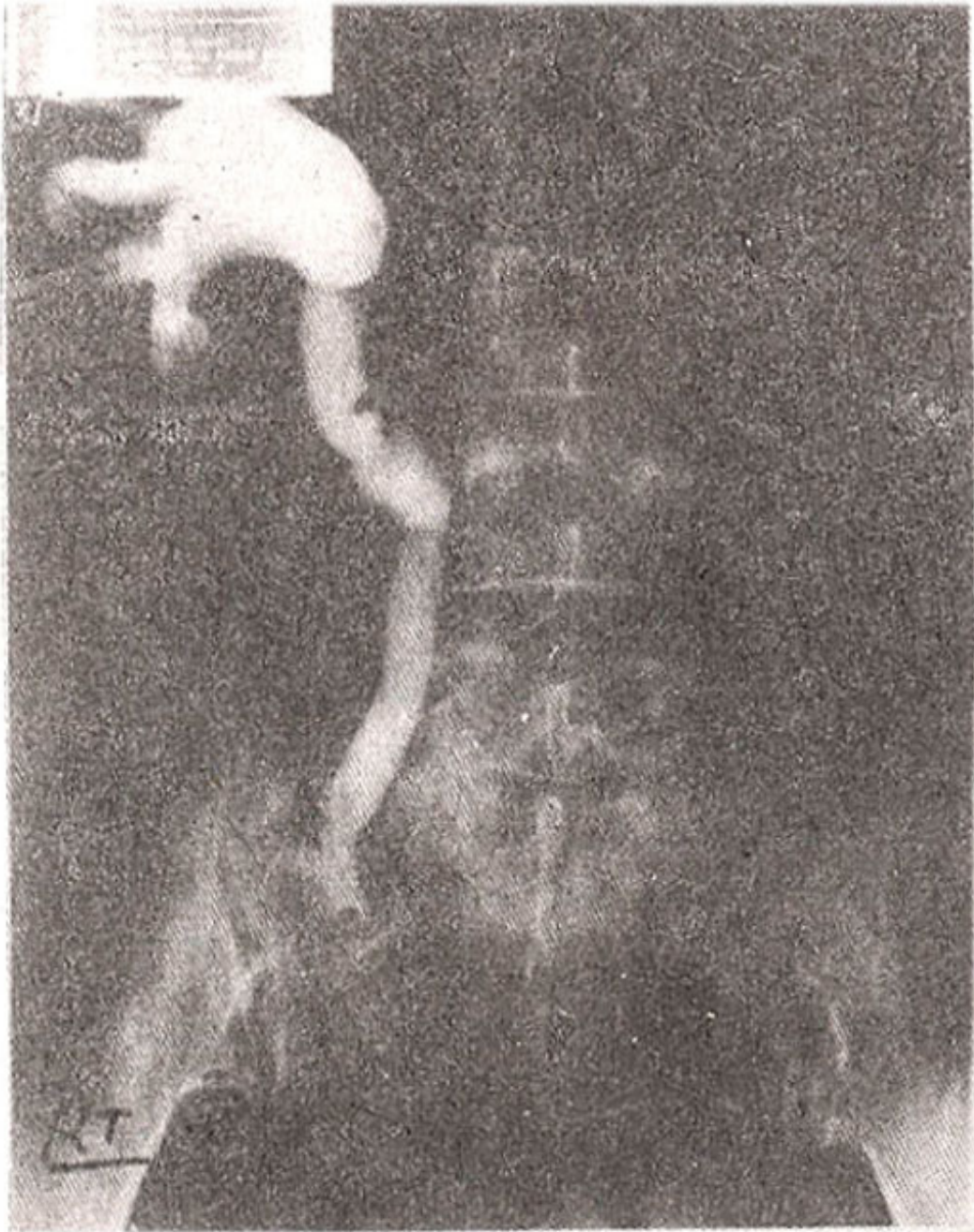

Figure 6. Complete healing of urinoma and fistula with stone obstructing distal ureter.

An antegrade double J stent was placed in for her subsequent management of stone and obstruction.

Discussion

A urinoma is an encapsulated extravasation of urine in retroperitoneum which can be secondary to trauma or which can occur spontaneously. The essential factors are continued renal function, rupture of the collecting system and distal obstruction. The extravasated urine causes lipolysis and stimulates an intense fibrous reaction which forms a thick wall⁵. The spontaneous rupture of the ureter is a rare condition⁶. An obstructed renal system can easily be ruptured even with minor trauma as in our first case. Conservative management by indwelling catheters is atleast as effective as primary surgery^{7,8}.

Even percutaneous drainage alone is considered sufficient⁵ and results in satisfactory healing of urinoma. This safe effective procedure allows non-operative management of urinoma. Recent experience has proved that, for the treatment of fistulas, urinomas, urinary ascites and obstruction due to a missed ureteral injury, the best results are achieved with initial nephrostomy followed by reconstruction when needed⁹. In one series nephrostomy was the definitive treatment in 44% of cases with leakage and it protected any required reconstruction¹⁰. Distortion of the ureteral orifice by scar tissue often makes retrograde introduction of indwelling catheters impossible; moreover, passage may be impeded by a near dehiscence of the ureter or an incomplete dehiscence may be totally severed during attempt at passage¹¹. Obstructing calculus in ureter also impedes the retrograde passage of catheter. The antegrade percutaneous technique offers an attractive alternative to placement of an indwelling stent. In our first case stent placement via cystoscopy had failed. PCN did very well and urinoma was healed within 2 weeks. Subsequently, a DJ stent was placed percutaneously for further management of ureteric calculus which was causing partial obstruction. In the second case, though urinoma was infected with a fistulous communication between infected urinoma and duodenum, but still, PCN was found to be a definite treatment and urinoma healed satisfactorily. In conclusion, percutaneous nephrostomy alone can be the primary treatment allowing healing of urinoma, which in some cases will be the only treatment required, while in others it may be the initial minimally invasive therapy till more definite treatment is done. In many cases this may avoid major surgery.

References

1. Keamey, G.P., Mahoney, E.M. and Brown, H.P. Useful technique for long term urinary drainage by indwelling ureteral stent Six year experience. *Urology*, 1979; 14: 126-134.
2. Konigsberg, H., Blunt, K.J., and Muecke, E.C. Use of Boari flap in lower ureteral injuries. *Urology*, 1975; 5: 75-77.
3. Stables, D.P., Ginsberg, N.J. and Johnson, M.L. Percutaneous nephrostomy: A series and review of the literature. *Am. J. Roentgenol.*, 1978; 130: 75-82.
4. Pfister, R.C. and Newhouse, J.H. interventional percutaneous pyeloureteral techniques; II. Percutaneous nephrostomy and other procedures. *Radiol. Clin. North Am.*, 1979; 17: 351-363.
5. Rohner, S., Tuchschnid, Y., and Graber, P. Perirenal urinoma (Abstract). *Ann. Urol.*, Paris, 1994; 28: 259-64.
6. Leuthardt, R., Berhardt, E., Gasser, T., et al. Spontaneous perforation of the ureter: A rare complication of urolithiasis. *Eur. J. Pediatr. Surg.*, 1994; 4: 205-6.
7. Goldin, A.R. Percutaneous ureteral splinting. *Urology*, 1977; 10: 165-168.
8. Lang, E.K., La-Nasa, J.A., Garrett, J. et al. The management of urinary fistulas and strictures with percutaneous ureteral stent catheters. *J. Urol.*, 1979; 122: 736-740.
9. Lang, E.K. and Glonoso, L. 'Management of urinomas by percutaneous drainage procedures'. *Radiol-Clin. North-Am.*, 1986; 24: 551-559.
10. Al-Ali, M. and Haddad, L.F. 'The late treatment of 63 overlooked or complicated ureteral missile injuries: The promise of nephrostomy and role of autotransplantation'. *J. Urol.*, 1996; 156: 1918-1921.
11. Lang, E.K. Diagnosis and management of ureteral fistulas by percutaneous nephrostomy and antegrade stent catheter. *Radiology*, 1981; 138: 311-317.