

Minimally invasive endoscopic selective parathyroidectomy

Montasir Junaid,¹ Zainul Abedeen Sobani,² Maliha Kazi,³ Mumtaz Junaid Khan⁴

Department of Otolaryngology, Head & Neck Surgery,^{1,3,4} Student, School of Medicine,² Aga Khan University, Karachi, Pakistan.

Abstract

Primary hyperparathyroidism is a common condition with surgery being the definitive treatment modality. Controversy exists over the extent of optimal neck exploration, whether unilateral or bilateral exploration should be performed, particularly since 85-90% of primary hyperparathyroidism results from single gland disease. Unilateral neck exploration is now considered to be adequate unless a definitive adenoma is not identified on ipsilateral exploration and where the serum intact Parathyroid Hormone (iPTH) level does not show a decline greater than 60% after removal of a suspected adenoma. It also avoids the potential risk of hypocalcaemia, recurrent laryngeal nerve injury along with extended anaesthesia and operative time and in-patient stay.

With the advent of advanced imaging modalities and peri-operative localization techniques the hyper-functioning gland can be identified and minimally invasive procedures can be performed, limiting the neck exploration to only the abnormal gland. Here we would like to describe our procedure for a minimally invasive endoscopic selective parathyroidectomy, performed on five patients. We describe our standard setup, procedure and the outcomes.

Keywords: Hyperparathyroidism, Parathyroidectomy, Minimally Invasive Parathyroidectomy.

Introduction

Primary hyperparathyroidism characterized by excessive secretion of parathyroid hormone (PTH) resulting in increased bone resorption and hypercalcaemia is a fairly common condition with an estimated incidence of 1 case per 1000 men and 2-3 cases per 1000 women. The incidence increases after age 40 years. Surgery represents the only curative treatment for primary hyperparathyroidism; restoring serum calcium and PTH homeostasis and improving bone mineral density with excellent cure rates.

Bilateral neck exploration (BLE) involving visualization of all four parathyroid glands and excision of grossly enlarged glands was previously considered the mainstay of parathyroid gland surgery. However, approximately 85-90% of patients with primary hyperparathyroidism have a single gland disorder,¹ bilateral neck exploration would lead to excessive tissue

manipulation and dissection, along with extended anaesthesia, operative time and in-patient course. With the advent of advanced imaging modalities and non-invasive peri-operative localization techniques the hyper-functioning gland can be accurately identified and procedures such as single gland exploration or unilateral neck explorations by minimally invasive methods can be employed.²⁻⁴

Here, we would like to describe the use of endoscope assisted parathyroidectomy for selectively removing single gland disease, performed in five patients at our tertiary care center.

Case Reports

Case-1:

A 45 year old male, otherwise healthy presented with history of leg cramps for 2 months. Laboratory investigations revealed a serum parathyroid hormone level of 295 pg/mL and Vit D3 levels of 9.96 mg/dl with serum calcium of 12.3 mg/dl and phosphate at 1.7 mg/dl. His spot urine calcium was 15mg/dl. Ultrasound evaluation of the neck showed a nodule on the right lower pole of the thyroid. Parathyroid scintigraphy showed a mass on the right lower thyroid pole consistent with a parathyroid adenoma.

A diagnosis of primary hyperparathyroidism due to a parathyroid adenoma was employed and he was electively scheduled for a minimally invasive right Inferior parathyroidectomy.

Peri operative Ultrasound (U/S) was performed by a senior radiologist and the incision site was marked over the underlying abnormal parathyroid gland. The remaining glands were also evaluated. The patient was administered general anaesthesia. A 2cm incision was made through the skin, subcutaneous tissue and platysma. Subplatysmal flaps were raised. The sternocleidomastoid muscle was retracted laterally along with the carotid sheath and its contents. A 0-degree 4mm Karl Storz rigid endoscope was introduced. Microsurgical instruments with 1mm fine tipped Debakey forceps and irrigating Bipolar electrocautery were used for endoscope assisted dissection around the thyroid gland.

The right inferior parathyroid was identified by minimal dissection right under the localized area. The recurrent laryngeal nerve was identified and preserved on

the posterior lateral aspect of the abnormal parathyroid gland. The abnormal gland was dissected and excised. It measured 1.5 x 1 cm with the capsule adherent to the thyroid stroma. Frozen section evaluation confirmed adenomatous hyperplasia of the parathyroid gland. Due to the lack of availability of iPTH assay, the ipsilateral second parathyroid gland was identified and appeared normal in appearance. It was not biopsied.

Post operatively there were no deficits or complications. The serum calcium levels were monitored twice daily for the first day. No symptomatic hypocalcaemia was observed and the patient was discharged on post operative day 3, after the serum calcium levels started to increase.

Case-2:

A 59 year old female, hypertensive, hypothyroid, status post excision of arteriovenous fistula, hepatitis C positive, end stage renal disease on dialysis, was evaluated and found to have a raised serum calcium level post dialysis. Parathyroid scintigraphy showed a mass on the right lower thyroid lobe.

She was referred to nephrology where a Sestamibi scan showed a functionally active parathyroid adenoma and she was referred for a minimally invasive right parathyroidectomy.

The adenoma was re-identified peri-operatively by U/S. The procedure was performed as described for Case 1. A single mass measuring 1x1 cm was identified and removed lateral to the Recurrent Laryngeal Nerve (RLN). Frozen section confirmed adenomatous hyperplasia. A second mass (1x2cm) was removed from below the RLN. This was consistent with a reactive lymph node. Her serum calcium levels were monitored twice daily. The immediate post-operative Calcium levels showed an initial downward trend and then stabilized by post-operative day 2. She was discharged on the 3rd post operative day.

Case-3:

A 34 year old female, hypertensive presented with a sore throat for the last 4-5 years, tingling sensations in the legs, palpitations and a short temper for the last two months. Her blood pressure had also been consistently uncontrolled over the period. She also complained of inability to lose weight despite her best efforts to intentionally reduce. Parathyroid scintigraphy showed a large parathyroid mass over upper half of the left lobe of the thyroid.

She was electively admitted for a minimally invasive left parathyroidectomy.

Standard U/S localization was performed prior to neck exploration. Minimally invasive left superior

parathyroidectomy was performed with a 3x2 cm adenoma excised from around the superior thyroid pole. The superior thyroid neurovascular pedicle was identified and preserved. Histopathological analysis showed a parathyroid adenoma.

Post operatively the patient developed a small haematoma and complained of tingling sensations in the hands and legs which resolved with a single dose of intravenous 10mg calcium gluconate. Her serum calcium levels were monitored twice daily and ranged between 9.5 mg/dl and 8.2 mg/dl. She was discharged on the 5th post operative day.

Case-4:

A 54 year old female, diabetic, hypertensive presented with pain in the lower extremities for 10 years managed with increasing doses of non steroidal anti-inflammatory drugs (NSAIDs). Her serum parathyroid hormone and vitamin D3 levels were low at 86.5 mg/dl and 20 ng/mL respectively.

She was referred for surgical treatment but she preferred conservative management for a period of about 2 years her disease continued to progress with the parathyroid hormone levels going as high as 158 pg/mL prior to surgery.

Once the patient consented for parathyroidectomy, ultrasound neck and parathyroid scintigraphy were performed which showed a right inferior parathyroid mass just inferior to the thyroid gland anteromedial to the carotid.

A mass of about 1.4x1.1 cm was removed using the 0degree endoscope. Her serum calcium levels were monitored twice daily and ranged between 9.8 mg/dl and 8.7 mg/dl. She was discharged on the 3rd post operative day with no complications.

Case-5:

A 29 year old female, with a history of Road Traffic Accident (RTA), status post internal fixation of left tibia 4 years ago in Kabul; complained of bilateral leg pain for 2 months. She also had difficulty in walking for the last 8 years. Her ambulatory complaints resolved after internal fixation for about a year after which they reappeared.

On examination there were no obvious deformities of the back or legs, no open wounds or signs of osteomyelitis. Range of motion was almost full in both knee and hip joints, but painful sensations were present with decreased muscle bulk. She was referred to orthopaedics where an antalgic waddling gait was observed with painful rotation at the right hip joint. Magnetic resonance imaging(MRI) of the lumbosacral spine was within normal limits. Radiographs of the pelvis, tibia and fibula showed generalized osteopenia with decreased bone density. Three phase skeletal scintigraphy showed focal areas of increased

tracer uptake involving mid shafts of both tibia and fibula bilaterally, suggesting fibrous dysplasia. Her serum thyroid stimulating hormone was 0.6 mg/dl, parathyroid hormone was 1243 pg/mL and vitamin D3 was 46.28 mg/dl, with a serum calcium of 12.2 and phosphate of 2.3. Her spot urinary calcium was 483 while spot urinary phosphate was 262. She was advised a Sestamibi scan which showed a left inferior parathyroid mass.

She was admitted electively for a minimally invasive left inferior parathyroidectomy. On examination she had a power of 4/5 in both upper limbs and 3/5 in her lower limbs.

The procedure was performed by giving a 3 cm incision over the marked area and introducing a 0 degree endoscope and the mass was excised and sent for histopathological examination. Histopathological exam revealed a parathyroid adenoma. Her post operative recovery was uneventful and she was discharged on her 3rd post operative day.

Procedure:

The patient was asked to lie on the operating table in a supine position with the neck extended by using a shoulder roll. After general anaesthesia and endotracheal intubation a senior radiologist performed peri-operative ultrasound localization of the enlarged parathyroid gland [Figure-1(A)]. The incision site was then marked overlying the identified parathyroid gland [Figure-1(B)]. The patient was propped and draped in the usual sterile fashion. A skin incision ranging between 15 - 25 mm was made. The incision was carried through the subcutaneous tissue and platysma [Figure-1(C)]. Subplatysmal flaps were raised superiorly and inferiorly [Figure-1(D)]. A 4mm 0 degree rigid endoscope (Carl Storz, Germany) was passed through

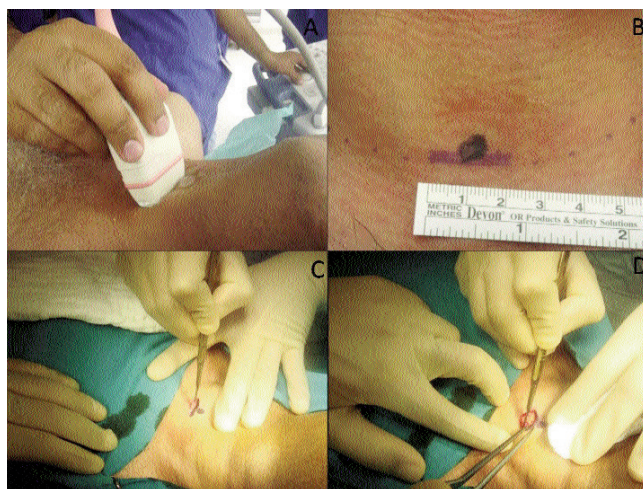


Figure-1: (A) Preoperative high resolution ultrasonography to localize the lesion. (B) Marking the incision site. In our experience incisions should range between 15-25 mm. (C) Skin incision ranging between 15-25 mm. (D) Creating a sub platysmal plane.

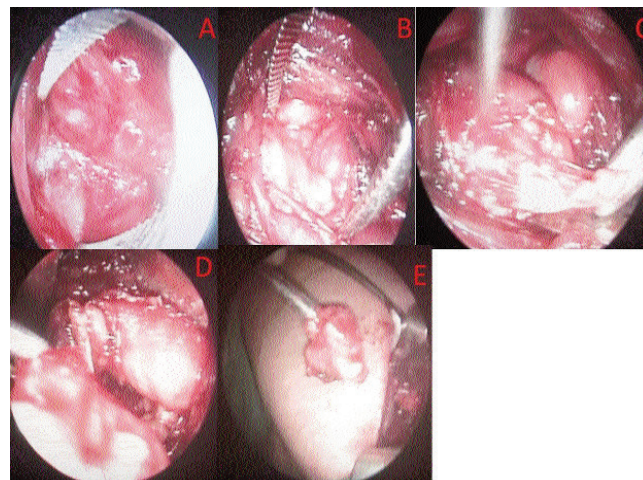


Figure-2: (A) Blunt dissection between the fascia of the sternocleidomastoid and strap muscles. (B) Reaching the thyroid bed. (C) Identifying the parathyroid glands by following the parathyroid arteries. (D) Clamping the blood supply and excision of suspected parathyroid gland. (E) Excised parathyroid gland.

the incision. The endoscope was controlled by the assistant while the primary surgeon performs blunt dissection with micro McCabe forceps, Debakeys and irrigating bipolar electrocautery through the same single incision. Next sternocleidomastoid (SCM) muscle was identified and delineation between the fascia of SCM and strap muscles was carried out [Figure-2(A)]; to reach the thyroid bed [Figure-2(B)]. After reaching the thyroid bed, the gland was retracted anteriorly and medially which lead to the localized parathyroid glands [Figure-2(C)]. The parathyroid vessels were clipped using titanium ligature clips and the lesion excised with its capsule and sent for histopathological examination [Figure-2(D,E)]. Recurrent laryngeal nerve once identified was not followed along its course. It was gently separated from or around the parathyroid mass to avoid unnecessary stretching or trauma. Haemostasis was achieved with the bipolar electrocautery and by individually ligating blood vessels and there was no need for placement of a drain. The wound was closed in layers leaving minimal external scars. The surgery time was an hour.

Discussion

Since the first Minimally Invasive parathyroidectomy (MIP) in 1996 by Gagner at the Cleveland clinic,⁵ parathyroid surgery has come a long way. Although Gangers procedure lasted for 5 hours and his patient developed subcutaneous emphysema he laid the corner stone for the future of minimally invasive parathyroid surgery as from then onwards various procedures have been proposed and carried out successfully. Recent trials have shown that the biochemical outcome of Bilateral Cervical

Enpeovation (BLE) is similar to other minimally invasive procedures.^{6,7} A trial conducted at Philipps-University Marburg, Germany found operating time to be significantly shorter with MIP; serum calcium levels were also slightly higher during the first 4 days after surgery in the patients undergoing MIP when compared to BLE.⁶ Another trial comparing BLE, with minimally invasive video assisted parathyroidectomies (MIVAP) carried out at the Università degli Studi di Pisa, Italy found that MIVAPs were associated with shorter operative times, better cosmetic results, and a less painful postoperative course. However, one patient undergoing MIVAP did suffer a recurrent laryngeal nerve injury.⁷

The success of any surgery is based not just on adequate resolution of the disease, but also restoration of the patient's functional capabilities to a normal or near normal state, preventing recurrence and minimizing complications, risks, morbidity and mortality. Various modalities have been proposed to assist complete excision. With improved imaging such as the Sestamibi scan and high resolution preoperative Ultrasonography, the extent of the lesions can be readily localized without the need of excessive exploration or the risk of residual disease.

Nussbaum et al brought into play another modality for monitoring residual parathyroid lesions during minimally invasive parathyroidectomies; intra-operative PTH assay.⁸ With the plasma half-life of PTH being about 4 minutes,⁹ the iPTH can be seen to drop drastically after complete excision of the abnormal parathyroid gland.¹⁰ The issue with intra-operative PTH monitoring is the lack of availability of the assay and the increased cost.

Although, the use of endoscope assisted parathyroidectomy has already been described and the use of limited neck exploration is gaining wide spread acceptance, this method needs to be promoted in our region where conventional neck exploration is still considered the standard of care. This method is safe, efficient, cost-effective, aesthetically pleasing and has low morbidity with successful disease outcomes.

References

1. Mariani G, Gulec SA, Rubello D, Boni G, Puccini M, Pelizzo MR, et al. Preoperative localization and radioguided parathyroid surgery. *J Nucl Med* 2003; 44: 1443-58.
2. Agarwal G, Barraclough BH, Reeve TS, Delbridge LW. Minimally invasive parathyroidectomy using the 'focused' lateral approach. II. Surgical technique. *ANZ J Surg* 2002; 72: 147-51.
3. Stalberg P, Delbridge L, van Heerden J, Barraclough B. Minimally invasive parathyroidectomy and thyroidectomy--current concepts. *Surgeon* 2007; 5: 301-8.
4. Udelsman R, Donovan PI, Sokoll LJ. One hundred consecutive minimally invasive parathyroid explorations. *Ann Surg* 2000; 232: 331-9.
5. Gagner M. Endoscopic subtotal parathyroidectomy in patients with primary hyperparathyroidism. *Br J Surg* 1996; 83: 875.
6. Bergenfelz A, Kanngiesser V, Zielke A, Nies C, Rothmund M. Conventional bilateral cervical exploration versus open minimally invasive parathyroidectomy under local anaesthesia for primary hyperparathyroidism. *Br J Surg* 2005; 92: 190-7.
7. Miccoli P, Bendinelli C, Berti P, Vignali E, Pinchera A, Marcocci C. Video-assisted versus conventional parathyroidectomy in primary hyperparathyroidism: a prospective randomized study. *Surgery* 1999; 126: 1117-21.
8. Nussbaum SR, Thompson AR, Hutcheson KA, Gaz RD, Wang CA. Intraoperative measurement of parathyroid hormone in the surgical management of hyperparathyroidism. *Surgery* 1988; 104: 1121-7.
9. Bieglmayer C, Prager G, Niederle B. Kinetic analyses of parathyroid hormone clearance as measured by three rapid immunoassays during parathyroidectomy. *Clin Chem* 2002; 48: 1731-8.
10. Irvin GL 3rd, Dembrow VD, Prudhomme DL. Operative monitoring of parathyroid gland hyperfunction. *Am J Surg* 1991; 162: 299-302.