

Presenting Features in Pakistani Patients Suffering from the Antineutrophil Cytoplasmic Antibody - Classical Subtype (c-ANCA) Associated Vasculitis

Tahir Aziz Ahmed, Abdul Halim, Tassawar Hussain, Nadeem Ikram, Shaheen Moin, Hamid Shafique, Liaqat Ali, Karamat A. Karamat (Departments of Immunology, Armed Forces Institute of Pathology (AFIP), Military Hospital, Rawalpindi.)
Abid Farooqi ((MH), Rawalpindi, Department of Rheumatology, Pakistan Institute of Medical Sciences, Rawalpindi.)
Masood Qureshi ((PIMS), Islamabad, Departments of Medicine, Rawalpindi General hospital, Rawalpindi.)
Javaid Malik ((RGH), and Fauji Foundation Hospital (FFH), Rawalpindi.)

Pages with reference to book, From 54 To 56

Abstract

Objectives: To study the clinicopathological features in c-ANCA positive patients suffering from vasculitis with a view to find out the most common mode of presentation.

Study design: Retrospective.

Settings: Department of Immunology, AFIP, Rawalpindi, MH Rawalpindi, CMH Rawalpindi, Department of Rheumatology, PIMS, Islamabad, RGH Rawalpindi, FFH, Rawalpindi.

Subjects: Seventeen patients suffering from vasculitis and found to be positive for c-ANCA. Main outcome measures: Clinico-pathological features at presentation.

Results: There were 9 males in age range 11-60 years (mean age 32.5 years) and 8 females in age range 26-42 years (mean age 32.3 years). Common presenting features were a combination of cough, blocked nose and post nasal drip 14/17 (82%) followed by nose bleed and haematuria 11/17 (65%). Six patients were demonstrated to be suffering from Wegener's granulomatosis after biopsy. C-ANCA was detected by indirect immunofluorescence in the titre range of 8-640. The auto antibody levels related to disease activity.

Conclusion: c-ANCA associated vasculitis is a rare (17 patients in five years) but aggressive form of vasculitis. It must be suspected in patients with persistent respiratory tract related symptoms associated with fever and joint pains which fail to respond to adequate treatment for infections. The c-ANCA estimations can be utilised as sensitive and specific diagnostic and prognostic marker in this form of vasculitis (JPMA 49:54, 1999).

Introduction

The ANCA associated vasculitides are characterised by an element of necrotising vasculitis and in most cases a poor prognosis for the untreated patients. The classical subtype of these autoantibodies is found most often in the sera of the patients suffering from active Wegener's granulomatosis (WG)¹ The classical diagnosis of WG requires the histological demonstration of the granulomatous vasculitis with element of necrosis² The diagnostic yield of the biopsy remains limited, as it is dependent on the site of the biopsy specimen³ In comparison the sensitivity and the specificity of the CANCA for the underlying necrotising vasculitis (in particular active Wegener's granulomatosis) has been demonstrated to be in the range of more than 90%⁴. The usefulness of the c-ANCA as a diagnostic and prognostic marker in WG is well established⁵. Although rare but some cases have been reported in local literature^{6,7} WG is characterised by upper respiratory tract (95%) lower respiratory tract (78%), renal (58%) joints (48%) skin (43%) and peripheral nervous system (32%) involvement⁸. The introduction of the specific immunosuppression with a

combination of steroids and cyclophosphamide has transformed the otherwise dismal prognosis for these patients with 90%, showing remarkable improvement and about 76% of them achieving full remission⁹.

Material and Methods

This prospective study was carried out by the Department of Immunology in the Armed Forces Institute of Pathology (AFIP), Rawalpindi, in collaboration with the teaching hospitals in the city with the primary objective of increasing awareness about this relatively rare disease. Physicians were requested to send in patients with a clinical suspicion of systemic vasculitis or their clinical records to AFIP ;for the relevant investigations and for the maintenance of the records. All patients who showed CANCA type of autoantibodies were included in the study. Patients were treated in the hospitals from where they were originally referred for investigations. However, for all patients their ANCA and related investigations were encouraged to be sent to AFIP for follow up. None of the patients having c-ANCA associated disease were excluded from the study. C-ANCA was detected by the indirect immunofluorescence assay using human neutrophils as substrate according to a standard protocol as already published⁶.

Results

A total of 17 patients were included in this study out of which 9 were males and 8 females (male:female, 1.1:1). The age range at presentation for males was 11-60 years with mean of 32.5 years. The age range at presentation for females 26-45 years with a mean age of 32.3 years. Twelve out of these 17 patients belonged to the Rawalpindi/Islamabad area. The most frequent presenting features are given in Table 1.

Table 1. Clinico-pathological features in c-ANCA positive patients.

Clinico-pathological features	Number of patients positive n=17
Cough, blocked nose, post nasal drip	14
Nose bleed	11
Haematuria	11
Fever, joint pains	9
Haemoptysis	7
Ear perforation	7
Petechial/purpuric rash	7
Conjunctivitis	5

A number of other clinical features as severe muscle aches, periorbital swelling, facial nerve palsy, oral ulcers, pneumonia, oedema feet, pruritis sole of feet, headaches and pain in the submandibular region were seen in individual cases.

Patient survival was 76.5% after 6 months to 4.5 years of follow up (patients were treated in different centers). Two patients died due to infections (suspected septicaemia) during treatment. One patient left the treatment and died due to massive pulmonary hemorrhage. One of the patients expired due to acute renal failure before the specific immunosuppressive treatment could be initiated. A total of 10 biopsy results were available. The results in six patients showed necrotising vasculitis with evidence of granuloma formation thus establishing the diagnosis of Wegener's granulomatosis. The result of one biopsy was granulomatous inflammation without evidence of vasculitis while in the rest of them the result was non-specific inflammation.

Quantitative c-ANCA estimations were used as part of the laboratory work up to monitor disease activity in most of the patients. Elevation of c-ANCA levels occurs in all cases but it occurs earlier in those with systemic disease as shown in the figure.

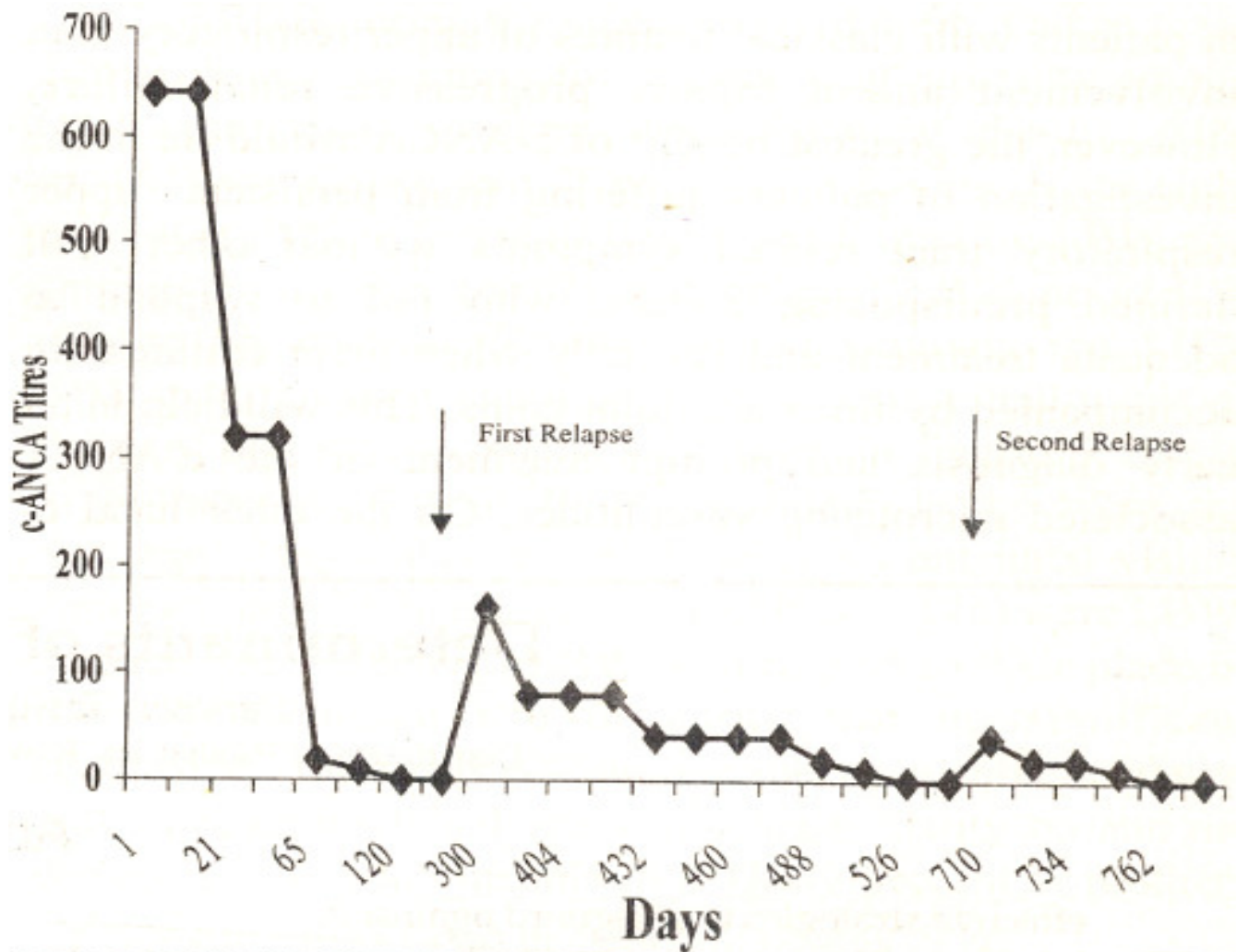


Figure. C-ANCA titres in patients with WG in a 3 year follow up relapses of vasculitis are marked by arrows. Note: The time scale in days has been rounded off to the nearest two weeks.

The c-ANCA levels were raised and helped in early detection of the relapse in two of the patients who are being followed up for the past 4.5 years and for 2 years respectively.

Discussion

Autoantibodies have been utilised as the diagnostic markers in a number of autoimmune diseases. However, the role of autoantibodies in the pathogenesis of these conditions remains to be demonstrated. The c-ANCA type of the autoantibodies has been shown to be a specific diagnostic marker (Table 2)¹⁰.

Table 2. ANCA status in various groups of patients¹³.

Group of patients	ANCA status (Number of patients positive/total tested)
Connective tissue diseases	0/148
Rheumatoid arthritis	0/109
Glomerulonephritis	0/107
Vasculitis	6/101
Granulomatous diseases	0/33
Other internal disease	0/752
Healthy blood donors	0/350

There is some experimental evidence that these autoantibodies can initiate the neutrophil activation in the in-Vitro systems¹¹. However, the exact mode of the pathogenesis remains unknown in WG or other c-ANCA associated vasculitides.

The c-ANCA associated vasculitides are characterised by their rapidly progressive nature, which may prove fatal in a vast majority of patients. The mean survival of the untreated patients was calculated to be 5 months with 82% mortality in one year¹². The results of our study show that some of the patients suffering from seemingly trivial presenting features such as cough, blocked nose, postnasal drip and the nose bleed may actually be suffering from c-ANCA associated vasculitis. The most common presenting features in our patients were cough, blocked nose, postnasal drip, nose bleed and haematuria. These features were frequently accompanied by fever, rash and joint pains.

The disease is rare but the fact that twelve out of these seventeen patients belonged to the Rawalpindi/Islamabad area highlights the point that a large number of patients may be overlooked in other cities. Our findings demonstrate that c-ANCA is a non invasive, relatively inexpensive, sensitive and specific investigation in patients with classical features of upper respiratory tract involvement and a rapidly progressive renal failure. However, the greatest benefit of c-ANCA would lie in the investigation of patients suffering from persistent upper respiratory tract related symptoms without other well defined predisposing factors, who fail to respond to adequate treatment and specially when these features are accompanied by fever and joint pains. This will help in an early diagnosis and prompt

treatment of the c-ANCA associated necrotising vasculitides. On the other hand cANCA must be a part of the laboratory work up for all patients presenting with rapidly progressive renal failure alone or in combination with respiratory tract related features.

References

1. Goeken JA. Anti neutrophil cytoplasmic antibody. A useful serological marker for vasculitis. *J. Clin. Immunol.*, 1991;11(4): 161-74.
2. Piercy S, Montanaro A. Recurrent Wegener's granulomatosis: A case report and review *Ann. Allergy Asthma Immunol.*, 1996;76:317-20.
3. Leavitt RY, Fauci AS. Wegener's granulomatosis and other systemic granulomatous conditions. *Current opinions in rheumatology*, 1990;2:55-59.
4. Nolle B, Specks U, Ludemann J, et al. Anti cytoplasmic auto antibodies: Their immunodiagnostic value in Wegener's granulomatosis. *Ann. Int. Med.*, 1989;111:28-40.
5. Wilk A, van Es LA. ANCA: Clinical association and role in disease monitoring. *Netherlands Journal of Medicine*, 1990;36:146-51.
6. Ahmed TA, Malik IA, Khan AA, et al. Anti neutrophil cytoplasmic auto antibodies (ANCA) in Pakistani patients with systemic vasculitides. *J. Pak. Med. Assoc.*, 1994;44:272-75.
7. Shah STA, Haleem A. Wegener's granulomatosis in an adult with single functioning kidney. *Pak. Armed. Forces, Medical Journal*, 1995;45(1):80-83.
8. Le thi Huong D, Papo T, Piette JC, et al. Urogenital manifestations of Wegener's granulomatosis. *Medicine*, 1995;74(3): 152-60.
9. Faud AS, Hayanas E, Katz P. et al. Wegener's granulomatosis. Prospective clinical and therapeutic experience with 85 patients for 21 years. *Ann. Int. Med.*, 1983;98:76-85 Cited in Talar Williams C, Hijazi YM, Walther MM, Linehan WM, Hajlahan CW, Lubensky I, Kerr GS, et al. Cyclophosphamide induced cystitis in patients with Wegener's granulomatosis. *Ann. Int. Med.*, 1996;124(5):477-84.
10. Gross WL, Csemok E. Immunodiagnostic and pathophysiological aspects of antineutrophil cytoplasmic antibodies in vasculitis. *Current opinions in rheumatology*, 1995;7: 11-19.
11. Falk RJ, Terrel RS, Charles LA, et al. Anti-neutrophil cytoplasmic auto antibodies induce neutrophils to degranulate and produce oxygen-radicals in Vitro. *Proc. Natl. Acad. Sci., USA*, 1990;87:41 15-19.
12. Hoffman OS, Randi YL, Fleisher TA, et al. Treatment of Wegener's granulomatosis with intermittent high dose intravenous cyclophosphamide. *Am. J. Med.*, 1990;89:403-10.