

Management of chronic symphysis pubis pain following child birth with spinal cord stimulator

Ahsan Idrees

Department of Anaesthesia & Pain, Our Lady of Lourdes Hospital, Drogheda, Ireland.

Abstract

The case of a 39 year old woman who had diastasis of pubic symphysis following childbirth and later developed severe chronic neuropathic pain and disability is presented. She received extensive surgical and medical treatment for 6 years with no improvement of symptoms. The VNRS (Visual Numerical Rating Scale) pain score was 7/10 or more most of the time. This was quite disabling in terms of her quality of life. A spinal cord stimulator was inserted after failure of other modalities of pain management which resulted in dramatic improvement in the quality of life measured with SF-36 questionnaire. Her pain score became 0/10 VNRS and she was free from opioids and psychotropic medications within 3 months post insertion. Spinal cord stimulator can be considered for the management of pain due to diastasis of pubic symphysis, not amenable to other therapies.

Keywords: Spinal Cord Stimulator, Chronic Pain, Diastasis Symphysis Pubis, Neuromodulation, SF-36.

Introduction

There are a number of case reports of acute and chronic pain following diastasis of pubic symphysis after normal vaginal delivery.¹ The reported incidence of diastasis (defined as abnormal wide gap >10mm between the two pubic bones) of pubic symphysis following child birth is very low and varies from 1 in 600 to 1 in 3400 deliveries.² This abnormal gap results in difficulty in walking and local tenderness. Although 42% of postpartum women have widening of symphysis pubis but few would develop this condition along with painful symptoms.³

Pathophysiology of this condition is not clearly defined in literature. The proposed mechanism is the injury to ligaments and nerves of the joint by the pressure of foetal head passing through the pelvic canal. As the pelvic ligaments are relaxed or weakened during the birth process by relaxin and progesterone, there is more instability of the pelvic joints including pubic symphysis which sometimes lead to abnormal widening and injury followed by pain and disability.

Case Report

The case of a young 39-year-old woman, an artist by profession who developed diastasis of symphysis pubis

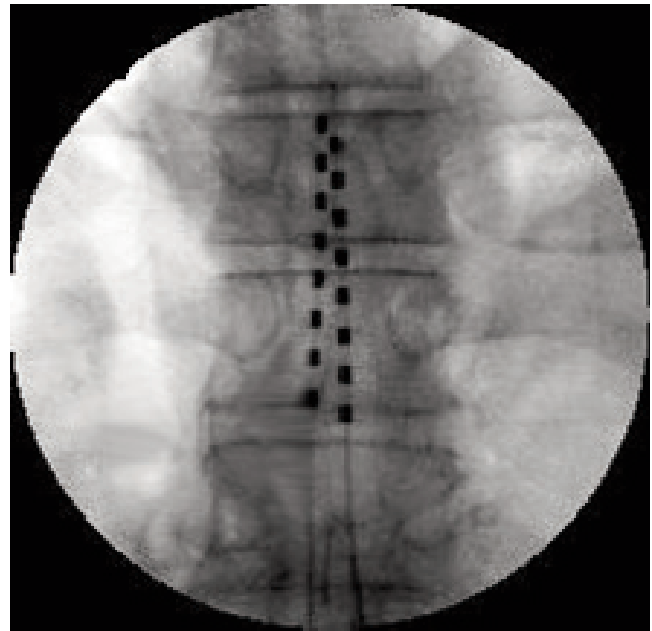


Figure: Dual Octrode Leads at T10 Level.

following normal vaginal delivery is presented. The gap of 21mm was confirmed by pelvic X-ray and ultrasound.

Clinically, she had severe pain on palpation of symphysis pubis, unable to stand on one leg and pain on walking and lifting objects. Her daily routine life was profoundly disturbed by this unexpected illness. Her pain score was 10/10 VNRS post delivery. She was initially treated conservatively. Strict bed rest was advised along with NSAIDs (Non Steroidal Anti Inflammatory Drugs) and Opioids for the management of severe acute pain. After 3 months of conservative management, condition did not improve and she underwent plating of symphysis pubis to stabilize the joint. It improved the pain score by about 20% but her quality of life did not improve. She still suffered severe burning pain, allodynia at the pubic symphysis joint and hyperaesthesia around pubic symphysis. Her mobility was limited due to severe pain on walking. Sleep had been poor due to pain. She was started on a number of medications which included Pregabalin (150-600mg per oral daily), Amitriptyline (25-100mg per oral daily), Venlafaxine

Table: Short Form Health Survey Pre and Post Spinal Cord Stimulator.

Evaluation	RESULTS (Out of 100)	
	Pre Spinal Cord Stimulator Insertion	6 Weeks Post Spinal Cord Stimulator Insertion
Physical Functioning	33.33	72.22
Role Limitation	0	75
Bodily Pain	32.5	77.5
Social Functioning	25	75
General Mental Health	48	72
Role Limitations due to		
Emotional Problems	0	66.66
Vitality, Energy or Fatigue	45	70
General Health Perceptions	30	70

(150-200mg per oral daily), Tramadol (100-400mg per oral daily), Diclofenac Sodium (150mg per oral daily) and Opioid skin Patches (Buprenorphine 5-20 mcg/hr). A score of 7/10 on VNRS (Visual Numerical Rating Scale) was observed. Despite all these medical management, assessment by a psychologist and physiotherapist was done in a multidisciplinary meeting and a management plan was devised. Diagnostic and therapeutic procedures were planned and performed, that included IV Lignocaine which gave good pain relief for few days. Peripheral nerve stimulation procedures SENS (Subcutaneous Electrical Nerve Stimulation) single shot (one session of 20 minutes) and SENS Wires (dual octrode leads) placement in the area of pain for one week trial were done but achieved no benefit.

After detailed discussion with the patient, spinal cord stimulator with dual octrode leads were put in at T10 level with good coverage of area of pain (Figure).

The procedure was completed uneventfully. Stimulation and programming of the spinal cord stimulator was done next day. The results were remarkable and pain score was 0/10 on VNRS. Over the course of 6 weeks, she was taken off from opioid patches, Pregabalin, Tramadol, Diclofenac Sodium and Venlafaxine. Her quality of life improved dramatically with no pain on walking and good sleeping pattern. Most of her daily routine was back to normal.

A Short-Form-36 (SF-36) Health Survey was performed one day before treatment with Spinal Cord Stimulator.⁴ She completed the same questionnaire 6 weeks post spinal cord stimulator insertion. The results were compared and calculated using the software QualityMetric Health Outcomes™ Scoring Software 2.0 for 8 dimensions measured pre and post spinal cord stimulator insertion. These are shown in the Table.

Discussion

This is an example of rare occurrence of chronic pain

condition following diastasis of pubic symphysis associated with normal term vaginal delivery. Diastasis is defined as an abnormal wide gap > 10mm between two pubic bones. It results from high levels of relaxin and progesterone during pregnancy, which causes relaxation of ligaments along with pressure exerted by passage of child through the birth canal in the process of delivery.⁵

A wide variation of its incidence (1:600 to 1:3400 deliveries) has been reported in the literature. The normal gap is usually 4 to 5 mm and in pregnancy it can be increased to 9mm. The symptomatic gap >10mm is abnormal. The strong association of pain and gap is reported if it is around 20mm. However, the gap was 21 mm in the present case.

Diagnosis of the condition is usually done by clinical findings and investigations. The usual clinical findings are inability to stand on one leg, aggravation of pain around pubic symphysis, which is supplied by genitofemoral (L1-2) and pudendal nerves (S2-4) with lifting of heavy objects and on walking. These symptoms were typically present in this case. This is usually accompanied by tenderness, allodynia, hyperaesthesia or hyperalgesia at and around the joint site. X-rays, ultrasound or MRI scan of pelvis can confirm the diagnosis.

In the literature, two ways of treatment are described for this condition. It consists of conservative management and surgical intervention. Conservative management include pain medications (e.g. NSAIDs & Opioids), strict bed rest, use of pelvic binders or braces, later on physiotherapy and pelvic exercises.⁶⁻⁸ The rationale behind this management is that during the period of puerperium, the hormonal levels decrease and ligaments tighten to stabilize the joint. The majority of women have shown good results with this treatment. However, a few cases do not respond to conservative management and therefore require surgical intervention. Surgical intervention includes plating or other instrumentations to fix and stabilize the joint.

In this case, after going through extensive conservative medical management and surgical intervention, she continued to suffer from severe chronic pain with poor quality of life. A thorough Pubmed and Medline search did not bring up any case that was managed by spinal cord stimulator for this condition. She had been on pain medications for quite a long time with not much benefit. She was tested with lignocaine infusion. Although data is sparse for the effectiveness of Lignocaine infusion for neuropathic pain, few patients do respond to this modality of treatment.⁹ The Neuromodulation techniques such as SENS single shot and SENS wires also failed to improve her condition. Management with dual octrode leads spinal cord stimulator successfully treated her pain and she

returned to a normal life. The representation of the dermatomal level in the dorsal columns of the spinal cord is much higher than the corresponding vertebral level.¹⁰ A good response at T10 level, which corresponds to lower lumbar and sacral roots, indicates that main branches of the pudendal nerve might be involved in the pain.

The Short-Form-36 (SF-36) Health Survey was originally developed by Dr John Ware and was derived from the Rand Corporation's Medical Outcomes Study (MOS).¹¹ The results of the survey questionnaire showed a dramatic improvement in quality of life post spinal cord insertion for this condition as shown in the Table. The comparison of scores in the Table clearly showed improvement in all dimensions. The major improvement was in role limitations and role limitations due to emotional problems (the difference of score of about 70). The difference of score in other dimensions was around 40.

This case report might incite further investigations in management of chronic pain in patients with diastasis of symphysis pubis. Further studies may be needed to find out true incidence of chronic pubic pain following diastasis of pubic symphysis and the effectiveness of medical therapy for its treatment. Furthermore, spinal cord stimulator may be included as one of the treatment options available to these patients for successful management of chronic pain, which is not amenable to other therapeutic modalities. Its value has not been explored in chronic pubic pain following other traumatic and non-traumatic causes, which may not respond to conventional treatment.

The results for SF-36 questionnaire clearly showed dramatic clinical improvement in this case with marked change in physical and mental behaviour post

spinal cord stimulation.

Conclusion

A neuromodulation technique with spinal cord stimulator is a good option to be considered for management of chronic pubic pain following diastasis of pubic symphysis, which is a rare condition. There is a need to explore its value for chronic pubic pain of other causes such as posttraumatic injuries, which fail to respond to other therapies.

References

1. Snow RE, Neubert AG. Peripartum pubic symphysis separation: a case series and review of the literature. *Obstet Gynecol Surv* 2001; 56: 447-8.
2. Senechal PK. Symphysis pubis separation during childbirth. *J Am Board Fam Pract* 1994; 7: 141-4.
3. Garagiola DM, Tarver RD, Gibson L, Rogers RE, Wass JL. Anatomic changes in the pelvis after uncomplicated vaginal delivery: a CT study on 14 women. *Am J Roentgenol* 1989; 153: 1239-41.
4. QualityMetric Incorporated and Medical Outcomes Trust. *Your Health and Well-Being*. (Online) 2000 (Cited 2009 Aug 20). Available from URL: http://www.sf-36.org/tools/pdf/SF-36v2_Standard_Sample.pdf.
5. Lindsey RW, Leggon RE, Wright DG, Nolasco DR. Separation of the symphysis pubis in association with childbearing. A case report. *J Bone Joint Surg Am* 1988; 70: 289-92.
6. Scriven MW, Jones DA, McKnight L. The importance of pubic pain following childbirth: a clinical and ultrasonographic study of diastasis of the pubic symphysis. *J R Soc Med* 1995; 88: 28-30.
7. Snow RE, Neubert AG. Peripartum pubic symphysis separation: box series and review of literature. *Obstet Gynecol Surv* 1997; 52: 438-43.
8. Penning D, Gladbach B, Majchrowski W. Disruption of the pelvic ring during spontaneous childbirth. *J Bone Joint Surg Br* 1997; 79: 438-40.
9. Carroll I. Intravenous lidocaine for neuropathic pain: diagnostic utility and therapeutic efficacy. *Curr Pain Headache Rep* 2007; 11: 20-4.
10. Kunnumpurath S, Srinivasagopalan R, Vadivelu N. Spinal cord stimulation: Principles of past, present and future practice: A review. *J Clin Monit Comput* 2009; 23: 333-9.
11. Ware JE Jr, Sherbourne CD. The MOS 36-item short-form health survey (SF-36). *Med Care* 1992; 30: 473-83.