

Dextrocardia with situs inversus totalis: Coronary Artery Bypass Grafting

Salila Hashmi,¹ Mariam Anis,² Umer Darr³

Department of Cardiothoracic Surgery, Aga Khan University Hospital,^{1,2} Department of Cardiothoracic Surgery, Tabba Heart Institute,³ Karachi.

Abstract

Dextrocardia with situs inversus is a rare congenital abnormality involving a left-handed mal rotation of the visceral organs. The incidence of coronary artery disease is the same as that in the general population.

Performing coronary artery bypass surgery on patients with dextrocardia poses a more challenging task. It is recommended that the right internal mammary artery be the first choice of graft for the anterior descending artery for a "situs inversus" situation.

We report 2 cases of patients with Dextrocardia who developed coronary artery disease and underwent coronary artery bypass grafting. Also mentioned is the slight difference in our technique.

Keywords: Dextrocardia situs inversus, Coronary artery bypass graft, Left anterior descending, Coronary angiography, Grafts.

Introduction

Dextrocardia with situs inversus is a rare congenital abnormality involving a left-handed mal rotation of the visceral organs. It occurs in approximately 1/10,000 patients.¹ The incidence of coronary artery disease in these individuals is the same as that in the general population.^{2,3} The clinical presentation and subsequent course of treatment seem does not differ from those of similar patients with normal cardiac position except that in most cases the chest pain is usually located on the right side.

We report 2 cases of patients with Dextrocardia who developed coronary artery disease and underwent coronary artery bypass grafting (CABG).

Case-1:

The first case was a 64-year-old male, a known case of Dextrocardia. The cardiac risk factors included diabetes, hypertension and hyperlipidaemia. He was a tobacco chewer. No family history of premature coronary artery disease was present. He presented to the emergency room with complaints of shortness of breath and sudden onset of chest pain, radiating to the left arm associated with sweating. Physical examination was unremarkable. ECG showed inverted P waves and depression of the ST segment in leads V1 to V3. Cardiac enzymes revealed Trop-I 59,

later increasing to 93, CK-MB 620, CPK-3239. He was admitted and treated as non - ST Elevation Myocardial Infarction. Aspirin, Clopidogrel, Beta blockers and

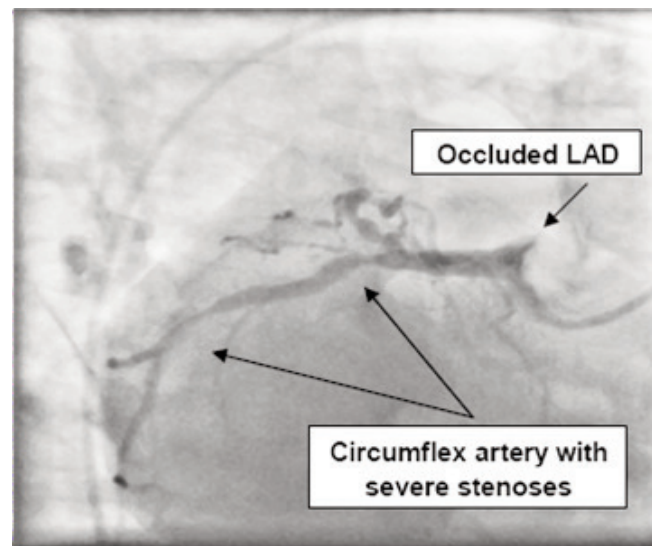


Figure-1: Coronary Angiography showing disease in the proximal LAD (Case 1).

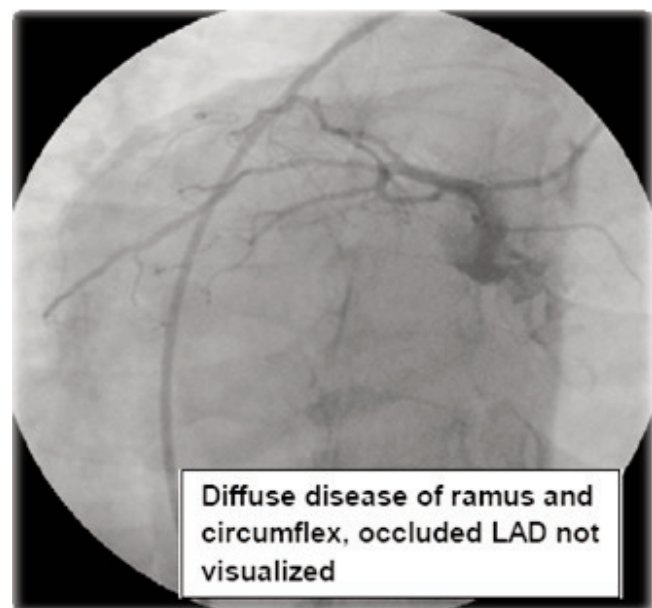


Figure-2: Cardiac cauterization for case 2 revealed diffuse disease at the ramus and almost total occlusion of LAD.

Enoxaparin were administered. His echocardiogram revealed an ejection fraction of 45%. He underwent dipyrimadole stress test which showed large size infarct of moderate intensity involving the apex, septum and inferior wall. Medium sized inducible ischaemia of moderate intensity was noted over the apical to mid anterior wall. The stress ECG was negative for myocardial ischaemia.

Cardiac catheterization was then performed. Coronary angiography revealed 70% disease in the proximal left anterior descending artery (LAD) and circumflex had proximal 90% disease. The first obtuse marginal branch was 100% blocked proximally. The Right coronary artery had 40% blockage proximally and approximately 60% distally.

The patient was then referred for coronary artery bypass grafting. After a median sternotomy, the apex of heart was found to be on the right; the pulmonary artery was on the right in relation to the aorta; the right atrium was on the left side, and the left ventricle on the right. Only saphenous vein grafts were used. The extracorporeal circulation was established through cannulation of the ascending aorta and the right atrium at normothermia. Saphenous vein grafts were anastomosed with the Left Anterior Descending, Obtuse Marginal (OM1) and Right Posterior Descending Artery (RPDA) respectively. Cardiopulmonary bypass (CPB) time and aortic cross-clamp time were 98 and 74 minutes respectively. The patient was weaned from CPB in normal sinus rhythm without inotropic support.

The patient had an uneventful postoperative course and was discharged on the fifth post operative day.

Case-2:

The second patient was a 49 year old male, known case of hypertension and diabetes mellitus with a positive family history of premature coronary artery disease. He was a non-smoker but had a habit of chewing tobacco for the last 30 years.

Thallium scan showed inducible ischaemia of moderate intensity. Coronary angiography revealed left Anterior Descending blocked almost 100% proximally. The ramus showed severe diffuse disease proximally, total occlusion in the obtuse marginal branch of Left Circumflex and 80% ostial disease in the Posterior Descending Artery. Ejection fraction was estimated to be about 30-35% with moderate left ventricular dysfunction.

During the coronary artery bypass the Right Internal Mammery Artery was used for left anterior descending anastomosis and reverse saphenous veins graft were

established at Obtuse marginal (OM-1) and Right Posterior Descending Artery(R-PDA).

The total clamp time amounted to 73 minutes whereas the cardio pulmonary bypass time was 94 minutes. The patient was weaned off from the cardio pulmonary bypass satisfactorily.

He was discharged on the third post operative day and continues to do well.

Discussion

Performing coronary artery bypass surgery on patients with dextrocardia poses a greater challenge compared to in patients with conventional positioning of the heart on the left. It is recommended that the right internal mammary artery be the first choice of graft for the anterior descending artery for a "situs inversus" situation. However in case 1, an attempt was made to harvest the right coronary artery but was abandoned due to difficult position and the unusual angle of the artery and only the saphenous vein grafts were used.

Dextrocardia was the first of the cardiac mal positions described by Fabricious in 1606.⁴ Situs inversus totalis with mirror-image Dextrocardia was described by Severinus in 1643.⁵ The first coronary artery bypass graft in Dextrocardia was performed in 1980.⁶

There has been a report of percutaneous coronary intervention done previously in a patient following a non ST Elevation Myocardial Infarction.⁷ However, to our knowledge this is the first reported case from Pakistan of coronary artery bypass grafting to be done on patients with Dextrocardia situs inversus.

Furthermore a point of difference in our method was that the surgeon stood on the right hand side of the patients unlike other Dextrocardia procedures earlier noted in literature.⁸

References

1. Rosenberg HN, Rosenberg IN. Simultaneous association of situs inversus, coronary artery disease and hiatus hernia. *Ann Intern Med* 1949; 30: 851-9.
2. Hynes KM, Gau GT, Titus JL. Coronary heart disease in situs in versus totalis. *Am J Cardiol* 1973; 31: 666-9.
3. Ptashkin D, Stein E, Warbasse JR. Congenital Dextrocardia with anterior wall myocardial infarction. *Am Heart J* 1967; 74: 263-7.
4. Cleveland M. Situs inversus viscerum: anatomic study. *Arch Surg* 1926; 13: 343.
5. Brown JW. *Congenital Heart Disease*. London: Staples Press Ltd, 1950.
6. Irvin RG, Ballanger JF. Coronary Artery Bypass Grafting in patient with Situs Inversus. *Chest* 1982; 81: 380-1.
7. Soofi MA, Pathan A. Percutaneous coronary intervention for acute coronary syndrome in Dextrocardia and Situs inversus. *J Coll Physicians Surg Pak* 2007; 17: 749-50.
8. Bonde P, Campalani GF. Myocardial revascularization for situs inversus totalis and dextrocardia. *Interact CardioVasc Thorac Surg* 2003; 2: 486-8.