
Mammographic Criteria for determining the Diagnostic Value of Microcalcifications in the Detection of Early Breast Cancer

M. Yunus, N. Ahmed, I. Masroor, J. Yaqoob
Radiology Department, The Aga Khan University and Hospital, Karachi.

Abstract

Objective: To evaluate the importance of microcalcifications in the detection of breast carcinoma in conventional mammography.

Methods: This prospective study was carried out at Aga Khan University Hospital (AKUH). Mammograms of 68 patients with microcalcifications were evaluated. Craniocaudal and oblique views of both breasts were acquired on routine basis with cone compression and magnified views when required.

Results: Among 68 patients with microcalcifications, 61 (89%) had clustered microcalcifications while 7 patients (10.29%) had scattered microcalcifications. Microcalcifications can occur in benign and malignant diseases. While evaluating clustered microcalcifications, few criteria have been established to determine malignant clustered microcalcifications, these include specific and nonspecific criteria. Among specific and statistically significant criteria for malignant microcalcifications, which were identified in this study, were irregularity of size, irregularity of density, linear or branched shape and Le Gal's type V distribution. In a cluster total number of >30 microcalcifications and at least 10 microcalcifications/cm² of a cluster are also important in diagnosing a malignant cluster, but are included in nonspecific criteria because they can be present in benign diseases also. Scattered bilateral microcalcifications are usually present in benign breast diseases, but in this study, two patients with breast cancer had profuse bilateral scattered microcalcifications.

Conclusion: This study shows that specific and statistically significant criteria for malignant microcalcifications, are irregularity of size, irregularity of density, linear or branched shape and Le Gal's type V distribution. Scattered bilateral microcalcifications are usually present in benign breast diseases, but irregular shape and development of new calcifications among diffusely scattered bilateral calcifications, on follow up study, should also raise suspicion for being malignant. (JPMA 54:24;2004).

Introduction

Primary breast carcinoma is one of the commonest causes of cancer deaths among females¹⁻² and with many advances mortality rate for breast cancer remains challenging. Mammography using high resolution and low dose film screen is the established method for early detection of breast cancers.³⁻⁵ Approximately 25-43% of non-palpable cancers are detected on mammography as a

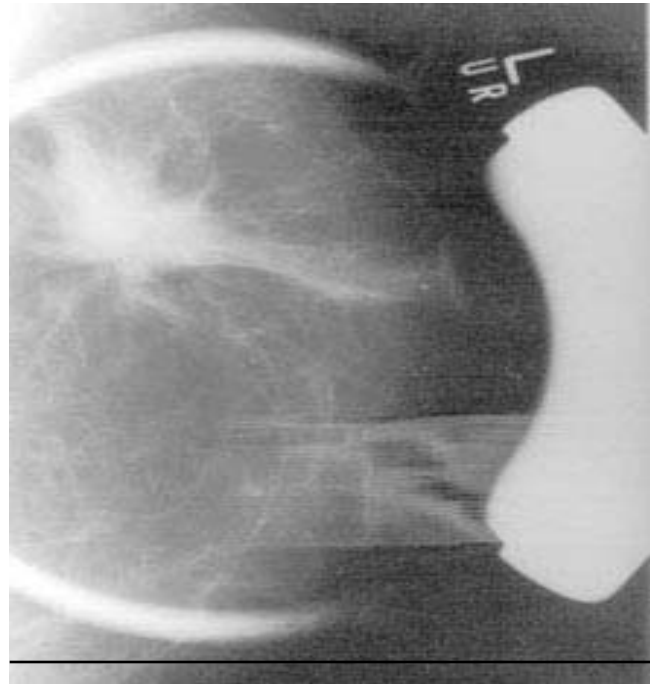
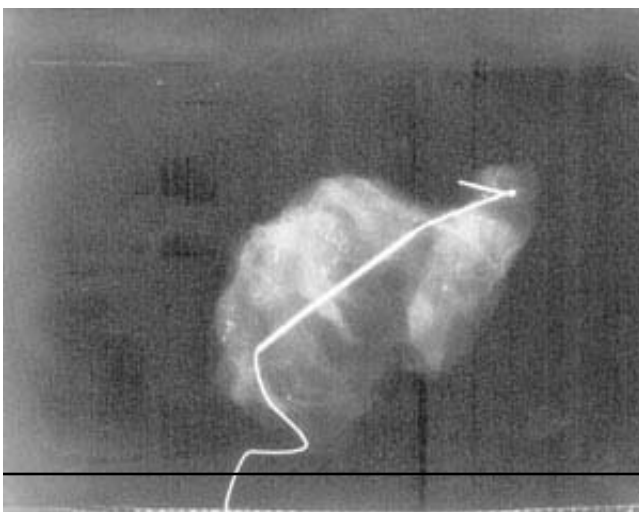
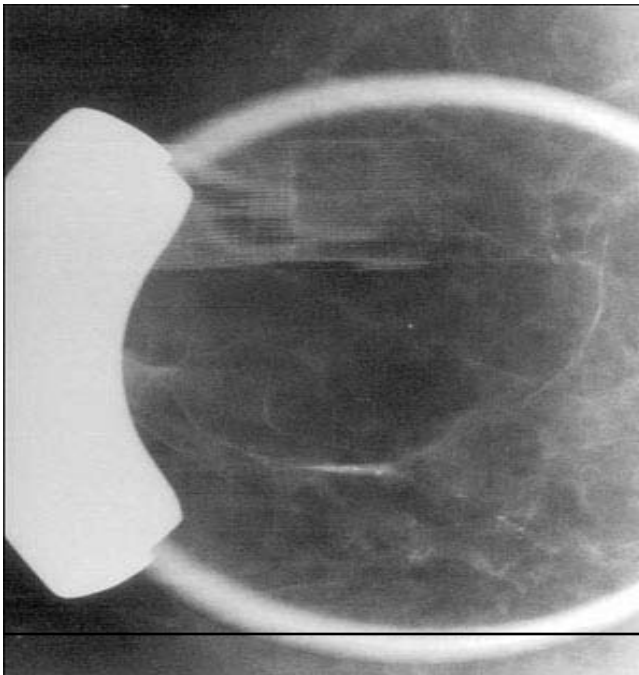
result of calcifications⁶⁻⁹ (Figure 1). The presence of multiple fine, clustered, pleomorphic calcifications increases the suspicion of malignancy whereas large, solitary, round or ring like calcifications are unlikely to be associated with malignancy.

Materials and Methods

Mammograms of 68 patients with microcalcifications AKUH during 1/11/1996 to 30/5/1999. Mammograms were

included in this study, which was carried out at obtained with Senographe 500 T Senix General Electric Machine. Craniocaudal and oblique views of each breast were performed on routine basis with cone compression and magnified views when required. In all patients, preoperative needle localization was done with a Kopan's hook wire. Mammography was performed in the resected surgical specimens along with magnified views to ensure that microcalcifications have been removed (Figure 2). Diagnosis was confirmed on histopathological examination of resected specimen.

Indications for mammography were mass in the breast in 28 patients (Figure 3), routine check up in 21, screening in 7, nipple discharge in 4, follow-up in 3, mammography before Hormone Replacement Therapy in 2,



mass in the breast with nipple discharge in 2 and mass in axilla in one patient.

Clustered and scattered microcalcifications were included in the study. Among clustered microcalcifications, the eight analytic mammographic criteria have been chosen for determining the diagnostic value of isolated clustered microcalcifications.¹⁰ These included the number of calcifications per square centimeter which are described as <10, 10-20, >20. The total number of microcalcifications per square centimeter was determined by moving a sheet of 1cm square hole in it over the mammogram. The count was made where number of microcalcifications was greatest. Total number of microcalcifications in the cluster are grouped as <10, 10-30, >30. The Irregularity of microcalcifications' density and size in the same cluster is evaluated by the experts (yes or no). The morphologic aspect of each cluster was classified by using Le Gal's classification, often used throughout Europe.¹⁰ Observations were recorded as Linear, branched or vermicular disposition, mean density of microcalcifications (high or low) and opinion of experts on the possible malignancy of the lesions.

Results of the study were correlated with the histopathological analysis.

Results

Age of 68 patients included in this study ranged from 30-80 years (mean 48 years). Sixty-one patients (89.7%) had clustered microcalcifications and 7(10.29%) had scattered microcalcifications.

Table 1. Distribution of microcalcification in 68 patients.

| Microcalcifications Type | Distribution | No. of patients |
|--------------------------|----------------------------------|-----------------|
| Clustered | Single cluster | 55 |
| | Multiple clusters (same breast) | 3 |
| | Multiple clusters (both breasts) | 3 |
| | Total | 61 |
| Scattered | Scattered (unilateral) | 5 |
| | Scattered (bilateral) | 2 |
| Total | | 7 |

Nineteen (31.14%) of sixty-one patients with clustered microcalcifications and two (28.5%) of seven patients with scattered microcalcifications had breast cancer (Table 1).

Number of Microcalcifications/cm² in a Cluster in 61 Patients

Results are described in Table 2, which shows that chance of malignancy increases with increased number of microcalcifications.

Total number of Microcalcifications in a Cluster in 61 Patients

Results are described in Table 2. As the total number of microcalcifications increases in a cluster, chances of

malignancy also increases.

Irregularity of Density of Microcalcification in a Cluster in 61 Patients

Results are described in Table 2. Irregularity in density of microcalcification in a cluster is one of the reliable criteria to diagnose breast cancer. Out of 61 patients with clustered microcalcifications, 19 were proven to have breast cancer. Of these 19 patients, 14 (73.68%) had irregularity in density while 5 (26.31%) had same density. Forty two patients were diagnosed to have benign disease, of whom 25 (59.52%) had similar density of microcalcification in a cluster while 17 (40.47%) had irregular density.

Irregularity of size of Microcalcifications in a Cluster in 61 Patients

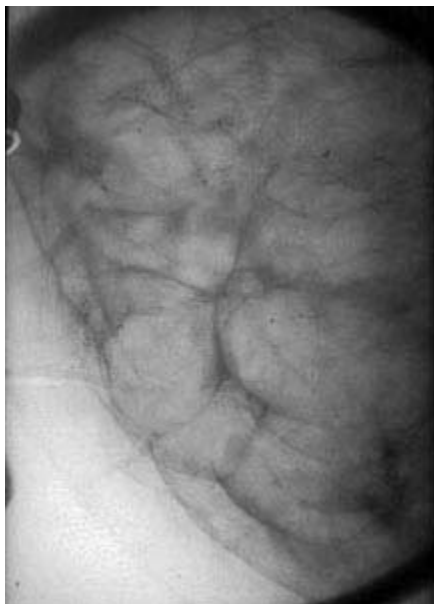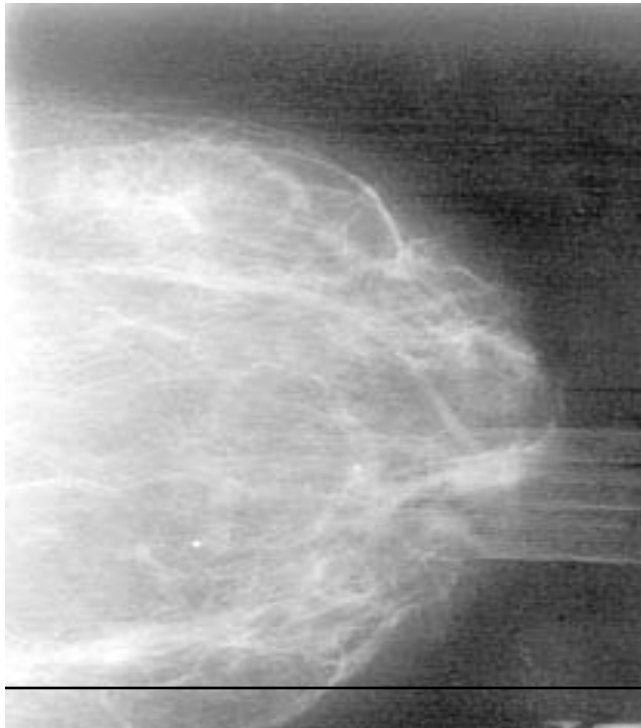Results are described in table 2. Irregularity in size of microcalcifications in a cluster is one of the reliable criteria. Out of 19 patients with breast cancer, 16 had irregularity in size of microcalcifications. Of these 42 patients with benign diseases, 23 had microcalcifications of same size.

Line/Branched/Vermicular disposition of Microcalcifications in a Cluster in 61 Patients

Results in Table 2, which shows that linear, branched or vermicular shape is one of important criteria in diagnosing a malignant cluster (Figure 4a and 4b). Out of 19 patients with malignant disease, 15 had linear, branched or vermicular calcifications. Of the 42 patients with benign

Table 2. Clustered microcalcifications in 61 patients.

| Clustered microcalcifications | No. of patients | Benign | | Malignant | | |
|--|-----------------|--------|----|-----------|----|-------|
| | | No. | % | No. | % | |
| No. of microcalcifications/ cm ² | <10 | 35 | 30 | 85.7 | 5 | 14.28 |
| | 10-20 | 19 | 10 | 52.6 | 9 | 47.4 |
| | >20 | 7 | 2 | 28.5 | 5 | 71.5 |
| Total number of microcalcifications in a cluster | <10 | 35 | 30 | 85.7 | 5 | 14.3 |
| | 10-30 | 22 | 11 | 50 | 11 | 50 |
| | >30 | 4 | 1 | 25 | 3 | 75 |
| Irregularity in density of microcalcifications in a cluster | Yes | 31 | 17 | 54.8 | 14 | 45.2 |
| | No | 30 | 25 | 83.33 | 5 | 16.67 |
| Irregularity of size of microcalcifications in a cluster | Yes | 35 | 19 | 54.28 | 16 | 45.72 |
| | No | 26 | 23 | 88.46 | 3 | 11.54 |
| Linear/branched/ vermicular disposition of microcalcifications | Yes | 25 | 10 | 40 | 15 | 60 |
| | No | 36 | 32 | 88.88 | 4 | 11.11 |
| Mean density of microcalcifications in a cluster | Low | 32 | 22 | 68.75 | 10 | 31.25 |
| | High | 29 | 20 | 68.96 | 9 | 31.03 |



diseases, 32 had granular microcalcifications while 10 had curved or linear appearance.

Mean density of Microcalcifications in a Cluster in 61 Patients

Results are described in table 2, which shows that mean density of microcalcification in a cluster is not a

Table 3. Le Gal's classification of Microcalcification in 68 patients.

| Le Gal's | Total No. of patients | Patients with breast cancer |
|--------------|-----------------------|-----------------------------|
| 1 | 27 | 2 |
| 2 | 13 | - |
| 3 | 4 | - |
| 4 | 5 | - |
| 5 | 19 | 19 |
| Total | 68 | 21 |

Table 4. Histopathological results.

| H/P results | No. of patients | Percentage |
|-------------------------------|-----------------|------------|
| Fibrocystic change | 27 | 39.7 |
| Sclerosing adenosis | 2 | 2.9 |
| Ductal hyperplasia | 11 | 16.2 |
| Atypical ductal hyperplasia | 4 | 5.9 |
| Ductectasia | 1 | 1.5 |
| Ductal carcinoma in Situ | 5 | 7.4 |
| Infiltrative ductal carcinoma | 17 | 25.0 |

reliable criterion in detection of malignant calcifications.

Le Gal's Classification of Microcalcifications and its relationship with Breast Cancer

Le Gal's type 5 is strongly associated with Ca breast as described in literature.¹⁰ In this study, 19 patients had Le Gal's type 5 microcalcifications and all of these patients were proved to have breast cancer (Table 3). Hence, there is a strong relationship between Le Gal's type 5 microcalcifications and breast cancer.

Expert Radiologists' opinion on the necessity for biopsy of Breast with Microcalcifications

Above-mentioned criteria are reliable enough for an expert radiologist to diagnose malignant calcifications. In our department, among 68 patients with microcalcifications biopsy was advised for 35 patients by radiologist. Of these 16 patients were proven to have breast cancer by histopathology. Hence, yield of biopsy after expert radiologist opinion was 45.71% which is at par with the results described in literature¹⁰, where the biopsy yield advised by radiologist is 34.6%.

Histopathological Results

Histopathological results of biopsy in 68 patients are

described in Table 4.

Discussion

Breast cancer is one of the commonest cause of cancer death among females.^{1,2} Mammography is the only investigation proven to be effective for the detection of early occult (T0) breast cancers. In this study 61 out of 68 (89%) had clustered microcalcifications while 7 out of 68 patients (10.29%) had scattered microcalcifications. Clustered microcalcification can occur in benign as well as malignant conditions. In this study clustered microcalcifications were present in 68.8% of benign and 31.1% of malignant conditions. Certain criteria have been established to determine malignant clustered microcalcification. This study shows certain criteria are nonspecific while others are more specific and statistically significant.

The non-specific criteria are:

Number of Microcalcifications/CM² of a Cluster

A compact cluster of microcalcifications (>20/cm²) was statistically more frequent in malignant lesions (71.4%), while loose clusters (<10/cm²) were more frequent in benign lesions (85.7%), but this criterion did not allow elimination of cancer in calcifications <10/cm² of a cluster.

Total number of Microcalcifications

As the total number of microcalcifications increases in cluster, chances of malignancy increases. 73.6% of malignant lesions had >10 microcalcifications /cluster while 85.7% of benign diseases had <10/cluster. The criterion of 30 or fewer microcalcifications was statistically significantly indicative of benignity (81% of benign lesion Vs 44% of cancer). The criterion of greater than 30 microcalcifications was found in 75% of cancers and in only 25% of benign mastopathies.

Mean Density of Calcifications

This is nonspecific in the detection of malignant calcifications. 52.6% of patients with malignant disease had low mean density of calcifications while 47.3% of malignant diseases had high mean density.

The specific and statistically significant criteria are:

Irregularity of Size of Microcalcifications

Eighty four point two percent of malignant lesions with clustered microcalcifications had irregularity in size of microcalcifications. Irregularity in size was statistically significant; it was found in 8 of every 10 cancers, but can also be present in 45% of benign lesions.

Linear, Branched and Vermicular shape of Microcalcifications

Seventy nine percent of malignant diseases with microcalcifications had linear, branched or vermicular configuration, which is rare in benign diseases. Linear or branched disposition is a statistically significant criterion in diagnosing malignant calcifications. 60% of such microcalcifications are malignant, but 40% of benign microcalcifications can have linear or branched configuration.

Irregularity of Density in Benign and Malignant Diseases in Cluster

More than 74% of malignant diseases with clustered microcalcifications had irregularity in the density of microcalcifications. Irregularity of density of microcalcifications was positive in approximately 1 cancer in 2.

Le Gal's Type 5 Calcification

This type of calcification is highly suggestive of malignancy. In this study all patients with Le Gal's type 5 calcifications had breast cancer, i.e., result is 100%. According to Le Gal's classification malignancy could be suspected only in type 5 lesions.

Statistically significant criteria in diagnosis of breast cancer were only five:

1. Vermicular, linear or branched disposition of calcifications
2. type 5 in Le Gal's classification
3. Irregularity of size (polymorphism)
4. Total number of calcifications
5. Number of microcalcifications greater than 20/cm²

An association between above mention variables enhances the risk of cancer and several criteria multiply the risk by a factor of greater than two.

Three criteria from above mentioned variables were statistically significant and even presence of only one of these permits correct diagnosis in 90% of all breast cancers.

Diffusely Scattered Microcalcifications in Breast Cancer

One interesting finding in this study was that 7 patients out of 68 had profuse scattered microcalcifications (10.29%), out of which 5 (71.4%) were proved to be benign, but two patients (28.57%) had malignancy. Both these patients had bilateral infiltrating ductal carcinoma in situ.

Diffusely and randomly distributed microcalcifications in a large volume of breast are usually

associated with benign breast disease. Morphologically, a central area of lucency in a calcium deposit is virtually always associated with benign processes. Certain patterns, however should arouse concern, for example, extensive comedocarcinoma is associated with large areas of mammographically visible calcium deposits. Their mammographic pattern was characterized by a strikingly wild, chaotic appearance with profuse deposition of calcium. Many deposits may have typically benign morphology.¹¹ Shape of microcalcifications is again important in such cases. The radiological suspicion should be raised, when these calcifications are interspersed with more irregular appearances resulting in overall heterogeneity. When such patterns occur, diffuse breast cancer should be suspected and follow up or biopsy of that area should be considered.

In this study, 21 out of 68 patients with microcalcifications were histopathologically proven to have breast cancer hence, biopsy yield in Radiology department at AKUH is 30.88%. According to Lawrence Bassett¹², 27% of biopsies yield malignancy at pathological evaluation. In another article, Edward Sickles¹³ has stated that biopsies carried out for indeterminate calcifications, about 20-30% cases are proved to be cancer, and this percentage for positive biopsy result is given in several studies.^{14,15} Experts opinion on the necessity for biopsy about suspicious microcalcifications in the Radiology Department at AKUH yielded 45.71% results positive for malignancy while in another study¹⁰ it is about 34.6%.

References

1. Smith RA, Giusti R. Epidemiology of breast cancer, chapter 21 pg. 295 (table 21-A) - Diagnosis of diseases of the breast - Data is taken from Parkin DM, et al. Cancer incidence in five continents. Vol VI, IARC scientific publications No 120, Lyon, France - 1992.
2. Donegan WL, Spratt JS. Cancer of the breast - Epidemiology and etiology. Philadelphia: W.B. Saunders, 1995, p. 121.
3. Basset LW, Gold RH. Introduction to mammography. In: Mitchell GW Jr.; Basset L. W. (eds). The female breast and its disorders. Baltimore: Williams and Wilkins, 1990, pp. 120-9.
4. Basset LW, Mangikion V, Gold RH. Mammography and breast cancer screening. Surg Clin North Am 1990;70:775-800.
5. Bassett LW. Mammographic analysis of calcifications. Radiol Clin North Am 1992; 30:93-105.
6. Ciatto S, Cataliotti L, Distante V. Non palpable lesions detected with mammography: review of 512 consecutive cases. Radiology 1987; 165: 99-102.
7. Murphy WA, De Schryver-Kecsckemeti K. Isolated clustered microcalcifications in the breast: radiologic pathologic correlation. Radiology 1978; 127: 335-41.
8. Sickles EA. Mammographic features of 300 consecutive nonpalpable breast cancers. Am J Roentgenol 1986; 146: 661-3.
9. Hermann G, Janus C, Schwartz IS. Occult malignant breast lesions in 114 patients: relationship to age and the presence of microcalcifications. Radiology 1988; 169: 321-4.
10. de La Fontan B, Daures JP, Salieru B, et al. Isolated clustered microcalcifications: diagnostic value of mammography: series of 400 cases with surgical verification. Radiology 1994; 190: 479-83.
11. Kopans DB, Nguye PL, Koerner FC, et al. Mixed form, diffusely scattered calcifications in breast cancer with apocrine features. Radiology 1990;177: 807-11.
12. Bassett LW. Mammographic analysis of calcifications. Radiol Clin North Am 1992; 30:93-104.
13. Sickles EA. Breast calcifications: mammographic evaluation. Radiology 1986;160: 289-93.
14. Egan RL, MsSweeney MB. Intramammary calcification without an associated mass in benign and malignant diseases. Radiology 1989; 137: 1-7.
15. Homer MJ. Breast imaging: pitfalls, controversies and some practical thoughts. Radiol Clin North Am. 1985; 23: 459-72.