Original Article

Immunohistochemical detection of hepatitis C virus (HCV) in liver biopsies of hepatitis C patients

Shuja Izhar Syed,[1] Saleem Sadiq[2]

Department of Pathology, Baqai Medical University,[1] Department of Pathology, Basic Medical Sciences Institute, Jinnah Postgraduate Medical Center,[2] Karachi.

Abstract

Objective: Immunohistochemical detection of Hepatitis C virus (HCV) in liver biopsies of hepatitis C patients and to find its association with the histological parameters of grading and staging.

Methods: This was a prospective study based on liver biopsies of hepatitis C patients. Haematoxylin and Eosin (H and E) stained slides were examined to determine the histological activity, and fibrosis score. The HCV NS3 antigen was detected with Immunohistochemical technique using monoclonal antibody against HCV NS3 protein.

Results: Cases which had a positive immunoreactivity for HCV- NS3 were 47 (94%). A total of 29 (58%) cases had shown grade 3 positivity for HCV-NS3 immunostaining; out of which, 16 cases had grade 3 necroinflammatory activity and 8 cases had fibrosis to the extent of cirrhosis ($P<0.05$). Out of the total 3(6%) cases with negative immunoreactivity for HCV-NS3, 2 cases had grade 1 activity and all of these 3 patients had minimal fibrosis amounting to stage 1 ($P<0.05$).

Conclusion: There is a positive association between HCV immunopositivity and the histological parameters of grading and staging, suggesting that greater amounts of virus are present in more advanced chronic liver disease.

Keywords: Liver biopsy, Hepatitis C, Necroinflammatory activity grade, Immunohistochemistry (JPMA 61: 1198; 2011).

Introduction

Hepatitis C virus (HCV) is a major cause of chronic hepatitis, liver cirrhosis and hepatocellular carcinoma (HCC) worldwide.[1] HCV infection is the leading cause of chronic liver disease in Pakistan. The prevalence of anti-HCV antibodies in chronic liver disease has been reported to be between 20-75%.[2]

Patients with chronic hepatitis C typically undergo liver biopsy to determine the severity of disease and thereby assess the urgency of treatment. Liver histology provides direct evidence of hepatic necroinflammatory activity, fibrosis, and progression to cirrhosis, and is a surrogate endpoint of the long term efficacy of interferon treatment.[3]

Inflammation is more severe in liver tissue with

HCV infection. In advanced chronic liver disease with hepatitis C virus infection, greater amounts of virus are present.[4] For this, immunohistochemistry (IHC) is a feasible and sensitive morphological and semiquantitative technique for the detection of HCV in tissues.[5] Insitu hybridization for viral RNA has proved somewhat insensitive or has yielded contradictory results in comparison with histologic examination. Immunohistochemical staining has often been successfully performed.[6]

The monoclonal antibody against HCV appeared to be suitable for identifying HCV in tissues by a simple IHC stain and can be used to explore the pathogenesis of liver injury induced by this virus.[7] Hepatocytes with positive staining have been found in the same region, irrespective of whether the antibody to core antigen, to envelope antigen, or to non structural protein (NS3) antigen was used.[4]

NS3 is one of the nonstructural proteins of HCV. It is a multifunctional protein because it harbours a serine protease responsible for the downstream cleavage in the non structural region and also for inhibition of the innate cellular host defense. This observation renders the NS3 protease particularly attractive as an antiviral target. The enzymatic activity of the NS3 region is indispensable for RNA replication; therefore recent advances in the understanding of its enzymatic activity could enable a specific inhibition as a novel antiviral strategy.[1] Pal et al[8] found that while core and NS3 antigens are equally associated with HCV infection, NS3 antigen is more closely associated with HCV replication than is core antigen.

To our knowledge no study is available from Pakistan in which the detection of HCV in chronic hepatitis C patients by using immunohistochemical methods has been done. It was therefore decided to carry out this study on immunohistochemical detection of HCV in liver biopsies of hepatitis C patients by using HCV NS3 antibodies and to find the association between HCV immunopositivity and the histological parameters of grading and staging.

Materials and Methods

This was a prospective study based on liver biopsies of hepatitis C patients received at the Department of Pathology at Basic Medical Sciences Institute (BMSI), Jinnah Postgraduate Medical Center, Karachi during the period from 2007 to 2008 and was carried out in collaboration with the Department of Radiology, Jinnah Postgraduate Medical Center.

Fifty patients who were serologically positive for hepatitis C i.e. HCV RNA positive by qualitative PCR method were included in the study. These patients after consent underwent ultrasound guided liver biopsies at the department of Radiology.

These biopsies were received at the Department of Pathology, BMSI for histopathological evaluation. The formalin fixed specimens were embedded in paraffin after tissue processing. Sections were taken initially for routine stains. The stained slides were examined under the microscope. METAVIRS' system was followed.[9] The following parameters were recorded in the proformas:

1- Histological activity or the necroinflammatory score

2- Fibrosis score.

Sections on silane coated slides were subjected to HCV NS3 (clone V/1859), mouse monoclonal antibody against HCV NS3 protein, which was procured from GeneTex, Inc. USA. Catalogue no.GTX78171.

The HCV NS3 antigen staining profiles were classified according to the localization and distribution of stain within liver tissue and thereafter the percentage of positive cells was semiquantitated.

Localization was categorized into: Intracytoplasmic or Intranuclear.

The percentage of positive cells was graded as:

- 0 , 0%
- 1+ , <10% positive cells
- 2+ , 10-50 % positive cells
- 3+ , >50% positive cells.[5]

Controls:

Highly positive case on the basis of high percentage of positive cells selected as a positive control. Whereas, a liver biopsy of person not having Hepatitis C and seronegative for HCV RNA was selected as a negative control.

Statistical Analysis:

Chi-square test was used as a method for statistical analysis. 'P' values of < 0.05 were considered significant.

Results

Majority of the patients i.e. 47 (94%) out of 50 were above 20 years, with a maximum number of patients i.e. 18 (36%) patients in their 4th decade of life (Table-1). Out of the total 50 cases, 47 (94%) cases had positive immunoreactivity for HCV- NS3 (Table-2). Among these positive cases the maximum number i.e. 29 cases had shown grade 3 positivity for HCV-NS3 immunostaining; out of these, 16 cases had grade 3 necroinflammatory activity while 10 cases had grade 1 necroinflammatory

Table-1: Gender Distribution of hepatitis C patients according to age groups.

Age groups (%)	Number of patients (%)	Gender	
		Male (%)	Female
10-20 years	3 (6%)	1 (2%)	2 (4%)
21-30 years	15 (30%)	7 (14%)	8 (16%)
31-40 years	18 (36%)	7 (14%)	11(22%)
41-60 years	14 (28%)	7 (14%)	7 (14%)
Total	50	22 (44%)	28 (56%)

Mean age : 35 years
Range :16-55 years
p > 0.05

Table-2: Distribution of immunoexpression of HCV NS3 according to necroinflammatory scores.

Grade	HCV NS3 Immunoexpression				Total
	0	+	++	+++	
1 (mild)	2(4%)	4(8%)	6(12%)	10(20%)	22 (44%)
2 (moderate)	1(2%)	1(2%)	2(4%)	3(6%)	7 (14%)
3 (severe)	-	1(2%)	4(8%)	16(32%)	21 (42%)
Total	3(6%)	6(12%)	12(24%)	29(58%)	50

p<0.05.

Table-3: Distribution of immunoexpression of HCV NS3 according to fibrosis score (stage).

Stage	HCV NS3 Immunoexpression				Total
	0	+	++	+++	
0	-	1(2%)	5(10%)	9(18%)	15 (30%)
1	3(6%)	4(8%)	6(12%)	5(10%)	18 (36%)
2	-	-	-	4(8%)	4 (8%
3	-	-	1(2%)	3(6%)	4 (8%)
4	-	1(2%)	-	8(16%)	9 (18%)
Total	3(6%)	6(12%)	12(24%)	29(58%)	50

p<0.05.

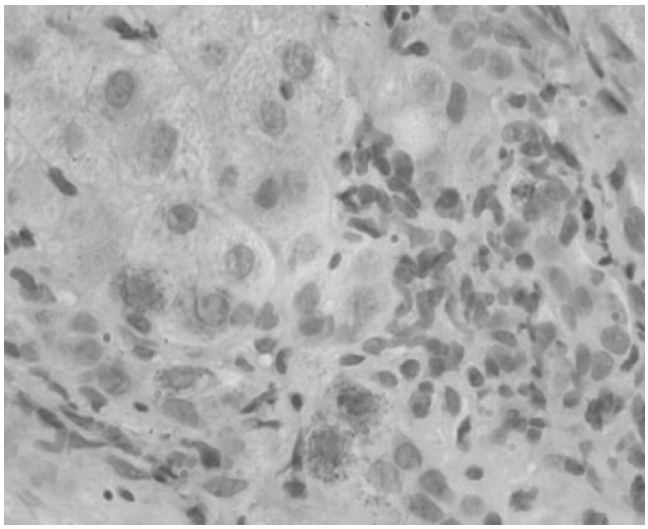

Figure-1: Liver, Positive 1+ for HCV-NS3, IHC, x400.

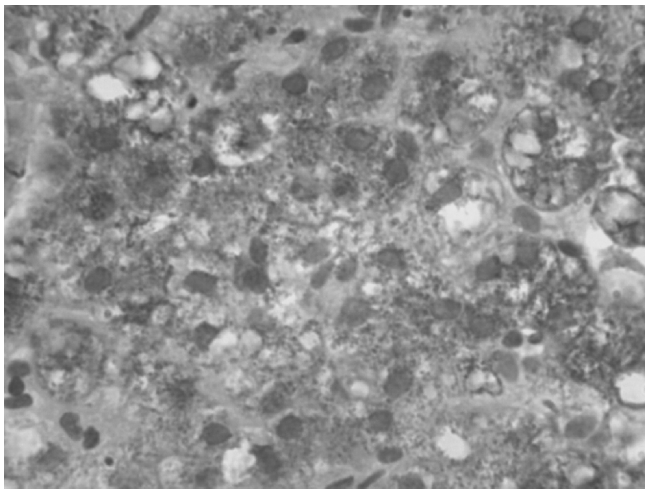

Figure-2: Liver, Positive 2+ for HCV-NS3, IHC, x400.

activity (P<0.05). In this study, the immunopositivity was solely localized to the cytoplasm of hepatocytes.

Out of the total 3(6%) cases with negative immunoreactivity for HCV-NS3, 2 cases had grade 1 activity and the remaining 1 case had grade 2 activity (P<0.05) (Table-2).

Out of the total 29 (58%) cases of grade 3 immunopositivity for HCV-NS3, 9 cases had no fibrosis, while 8 cases had cirrhosis (P<0.05) (Table-3).

All of the 3 (6%) immunonegative cases for HCV-NS3 had minimal fibrosis amounting to stage 1 (P<0.05).No cases in stage 2, stage 3, and stage 4 were found who had negative immunoreactivity for HCV-NS3 (Table-3).

Discussion

The present study has shown that majority of patients (97%) are more than 20 years old. This is in accordance with the third National Health and Nutrition Examination Survey (NHANES), who have found 76% of cases older than 20 years.[10] Our study showed female preponderance i.e. 56%, however large cross sectional studies like the NHANES study have not demonstrated gender differences in the rate of chronicity in hepatitis C infection; they had reported similar rates of HCV chronicity among both men and women.[10]

In our series, 47 out of 50 patients i.e. 94% have demonstrated HCV-NS3 antigen positivity (Table-2). This is in accordance with Nouri-Aria et al,[11] who had reported 93% positivity. Brody et al,[6] Nayak et al,[7] and Hiramatsu et al[4] had found HCV positivity in 44%, 57%, and 26% respectively. This difference with our study could be due to the fact that we have used monoclonal antibodies

specifically targeting NS3 region, while other workers had used different variants for detection of HCV like TORDJI-22 specific for C-100 protein (a product of NS3 region) was used by Brody et al.[6] According to Blight et al,[12] by using 10% formalin fixed tissues as compared to frozen sections, intense staining patterns were observed.

In our study, the immunopositivity was solely localized to the cytoplasm of hepatocytes. This was in accordance with Brody et al,[6] Nouri-Aria et al,[11] Blight et al,[12] and Hiramatsu et al,[4] who had demonstrated immunopositivity in the cytoplasm of hepatocytes.

Our study showed that out of 29 (58%) cases of grade 3 immunopositivity , maximum number i.e. 16 patients had severe necroinflammatory score ; whereas 11 patients had higher stage of fibrosis ($p<0.05$) (Table-2 and 3). Similarly out of 6 (12%) patients with grade 1 immunopositivity, 4 have mild necroinflammatory score; whereas 5 patients have minimal or no fibrosis.

However mild activity and fibrosis has been found in 3 cases showing negative immunoexpression (Table-2 and 3). These findings suggest that greater amounts of virus are present in more advanced chronic liver disease. This is in accordance with Hiramatsu et al,[4] who had observed that severe necroinflammation and fibrosis were found in positive samples containing more HCV infected hepatocytes.

Therefore, it can be concluded that there is a positive association between HCV immunopositivity and the histological parameters of grading and staging, suggesting that greater amounts of virus are present in more advanced chronic liver disease.

This relationship of necroinflammation and fibrosis with hepatocyte content of HCV could be elaborated further, in the context that NS3 is associated with HCV replication and keeping in view the role of NS3 as a possible antiviral target in future.

References

1. Brass V, Moradpour D, Blum HE. Molecular virology of hepatitis C virus (HCV): 2006 Update. Int J Med Sci 2006; 3: 29-34.
2. Umar M, Bushra H, Shoaib A, Anwar A, Shah NH. Spectrum of chronic liver disease due to hepatitis C virus infection. J Coll Physicians Surg Pak 2000; 10: 380-3.
3. Camma C, Bona D, Schepis F, Heathcote EJ, Zeuzem S, Pockros PJ, et al. Effect of Peginterferon alpha-2a on liver histology in chronic hepatitis C: A meta analysis of individual patient data. Hepatology 2004; 39: 333-42.
4. Hiramatsu N, Hayashi N, Haruna Y, Kasahara A, Fusamoto H, Mori C, et al. Immunohistochemical detection of hepatitis C virus-infected hepatocytes in chronic liver disease with monoclonal antibodies to core, envelope and NS3 regions of the hepatitis C virus genome. Hepatology 1992; 16: 306-11.
5. Rullier A, Trimoulet P, Urbaniak R, Winnock M, Zauli D, Ballardini G, et al. Immunohistochemical detection of HCV in cirrhosis, dysplastic nodules, and hepatocellular carcinomas with parallel-tissue quantitative RT-PCR. Mod Pathol 2001; 14: 496-505.
6. Brody RI, Eng S, Melamed J, Mizrachi H, Schneider RJ, Tobis H, et al. Immunohistochemical detection of hepatitis C antigen by monoclonal antibody TORDJI-22 compared with PCR viral detection. Am J Clin Pathol 1998; 110: 32-7.
7. Nayak NC, Sathar SA. Immunohistochemical detection of hepatitis C virus antigen in paraffin embedded liver biopsies from patients with chronic liver disease. Acta Histochem 1999; 101: 409-19.
8. Pal S, Shuhart MC, Thomassen L, Emerson SS, Su T, Feuerborn N, et al. Intrahepatic hepatitis C virus replication correlates with chronic hepatitis C disease severity in vivo. J Virol 2005; 80: 2280-90.
9. Bedossa P, Poynard T and the French METAVIR Cooperative Study Group. An algorithm for grading activity in chronic hepatitis C. Hepatology 1996; 24: 289-93.
10. Chen SL, Morgan TR. The natural history of hepatitis C virus (HCV) infection. Int J Med Sci 2006; 3: 47-52.
11. Nouri-Aria KT, Sallie R, Mizokami M, Portmann BC, Williams R. Intrhepatic expression of hepatitis C virus antigens in chronic liver disease. J Pathol 1995; 175: 77-83.
12. Blight K, Lesniewski R, LaBrooy J, Gowans E. Detection and distribution of hepatitis C- specific antigens in naturally infected liver. Hepatology 1994; 20: 553-7.