

Bulbar Urethral Stricture repair with Buccal Mucosa Graft Urethroplasty

Hussain Ahmad, Arshad Mahmood, Waqar Azim Niaz, Muhammad Akmal, Badar Murtaza, Amir Nadim
Department of Urology, Armed Forces Institute of Urology, Rawalpindi.

Abstract

Objective: To evaluate the use of buccal mucosa graft in single stage urethral reconstruction of bulbar urethral stricture.

Methods: In Armed Forces Institute of Urology Rawalpindi, from Jan 2008 to Oct 2009, 56 patients underwent single stage dorsal onlay urethroplasty using buccal mucosa graft for long bulbar urethral strictures (>2cm). Urethra was incised along the strictured segment in the 12 o'clock (dorsal) position starting from the distal end. A buccal mucosa graft of required length was harvested. The graft was anchored in a spread fixed fashion to the corporal bodies opposing the dorsally incised strictured urethra. The urethra was rotated back to the normal anatomic position. The margins of urethral incision were sutured to the fixed graft edge and corporal body using interrupted 4-0 vicryl. After completion of right margin's stitches, a 16 Fr silicon catheter was placed and then left margin stitches were completed.

Results: Only 54 out of 56 patients could be evaluated because 2 patients were lost to follow up. Mean age of the patients was 48±11.32 years (range 19-67 yrs). Mean length of the buccal mucosa graft was 3.4±0.6 cm (range 2.6 - 5.5cm). Duration of follow up was 4-20 months, mean 16.3±3.65 months. In 47 (87%) patients, the procedure was successful, 7(13%) patients developed recurrence, out of these 7 patients, 2 (3.7%) required optical urethrotomy and 5 (9.25%) patients responded to urethral dilatation. Mean operative time was 92±13.22 minutes.

Conclusion: Buccal mucosa graft urethroplasty produces encouraging results in long bulbar urethral strictures. Longer follow up is required.

Keywords: Bulbar urethral stricture, Buccal mucosal graft, Urethroplasty (JPMA 61:440; 2011).

Introduction

Reconstruction of Urethra has continued to present a formidable and enormous challenge to urologic surgeons.¹ A wide array of techniques is used in reconstructive surgery of bulbar urethral stricture disease, and modifications are continuously added to them. Stricture excision and anastomotic repair is appropriate only for short and untreated lesions of traumatic origin, following a blunt perineal trauma.² End to end urethroplasty for adult bulbar urethral stricture has greater than 95% durable cure rate and low complication rate.³ The use of flaps and grafts are mandatory in patients with longer and complex strictures. Split and full thickness skin graft from scrotum, penis and extra genital sites, bladder mucosa and more recently oral mucosa have been used.⁴⁻⁷ Over the past few years, buccal mucosa grafts (BMG) have been a reliable and popular substitute for use in urethroplasty.^{8,9} Buccal mucosa obviates most of the problems associated with other graft harvesting, providing easy accessibility and concealed donor site scar. Buccal mucosa is easy to harvest, resistant to infection, compatible with wet environment. It has thick epithelium, thin lamina propria and high capillary density.¹⁰

Patients and Methods

In Armed Forces Institute of Urology Rawalpindi, from Jan 2008 to Oct 2009, 56 patients underwent single stage dorsal onlay urethroplasty using buccal mucosa for long bulbar urethral strictures (>2cm). It was descriptive type of study. Retrograde urethrography (RUG) was performed in all patients to define the length, location, caliber and multiplicity of stricture. If the stricture was obliterative and suprapubic catheter (SPC) was in place, a descending urethrogram was also performed to evaluate urethra proximal to the stricture. Urethra distal to stricture was also evaluated by urethroscopy. All patients were given general anaesthesia for buccal mucosa harvest. A broad spectrum antibiotic and infusion Metronidazole was given at the induction of anaesthesia.

The patient was placed in the lithotomy position with buttocks at the edge of the table. A midline perineal incision was made and bifurcated posteriorly 2cm above the anus. Subcutaneous tissue was divided to expose the underlying bulbospongiosus muscle. The bulbospongiosus muscle was divided in the midline to expose the underlying bulbar urethra. Circumferential mobilization of bulbar urethra was performed with blunt and sharp dissection. An 18 Fr Catheter was advanced to the site of narrowing and urethra was rotated 180

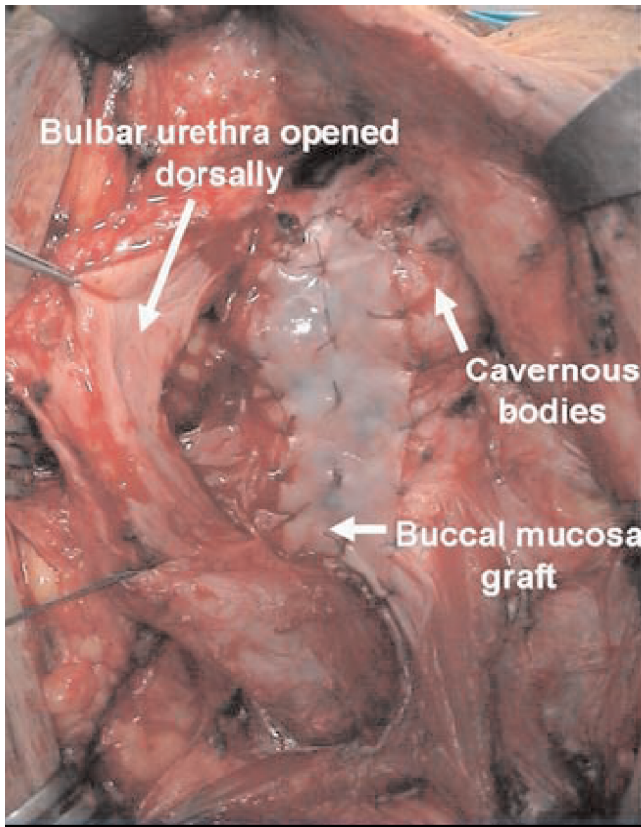


Figure-1: Graft is anchored to the corporal bodies opposing the dorsally incised strictured urethra.

degrees to expose the dorsal aspect of the urethra. Stay sutures of 4-0 chromic catgut were placed along the exposed dorsal aspect of the urethra. Then urethra was incised along the strictured segment in the 12 o'clock (dorsal) position starting from the distal end. Lignocain gel was pushed in the strictured urethra after opening the distal end to define the narrow lumen. The incision was extended 1cm into the healthy urethra proximal and distal to the stricture. Proximal and distal patency was confirmed by 24Fr bougie. A buccal mucosa graft of required length was harvested from the inner cheek. The graft was defatted and anchored in a spread fixed fashion to the corporal bodies opposing the dorsally incised strictured urethra (Figure-1). The urethra was rotated back to the normal anatomic position. The margins of urethral incision were sutured to the fixed graft edge and corporal body using interrupted 4-0 vicryl. After completion of right margin's

stitches, a 16 Fr silicon catheter was placed and then left margin stitches were completed. Depending on haemostasis, a Redivac drain was placed. The operation was labeled successful if no further procedure was required e.g. urethrotomy or urethral dilatation.

Results

Fifty six patients with bulbar urethral stricture underwent single stage urethroplasty using buccal mucosa graft whereas 2 patients were lost to follow up and only 54 patients could be evaluated. Mean age of the patients was 48 ± 11.32 years (range 19-67 yrs). Mean length of the buccal mucosa graft was 3.4 ± 0.6 cm (range 2.6 - 5.5cm). Regarding donor site morbidity, no patient suffered from parotid duct injury. Seven (12.96%) patients suffered from infection and swelling of the cheek which settled in a weeks time. Duration of follow up was 4-20 months (mean: 16.3 ± 3.65 months). In all 32 (59.29%) patients completed 20 months follow up. In 47 (87%) patients, the procedure remained successful, and no further intervention was required (Figure-2a,b). Post operative peak flow rates were markedly improved as compared to pre operative peak flow rates (Table). Seven (13%) patients developed recurrence, of whom 2 (3.7%) required optical urethrotomy and 5 (9.25%) responded to urethral dilatation. Three (5.55%) patients developed superficial wound infection which responded to oral antibiotics and sitz baths within a week. Mean operative time was 92 ± 13.22 minutes.

Patients were followed up with uroflometry, and those with $Q_{max} < 15$ ml/Sec underwent urethrogram. Seven (13%) patients developed restructure, of whom 2 patients required optical urethrotomy and 5 responded to urethral dilatation.

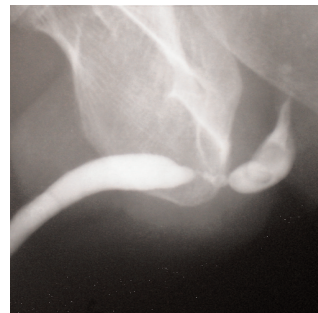


Figure-2a: Preoperative urethrogram showing stricture.

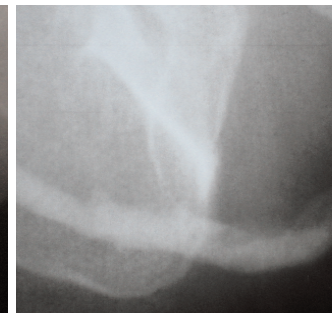

Figure-2b: Postoperative urethrogram.

Table:

S. No	Pre Operative Peak Flow Rate			S. No	Post Operative Peak Flow Rate		
	Q max (ml/sec)	No. of patients	%		Q max (ml/sec)	No. of patients	%
1	5- 10	17	31.48%	1	15-20	13	18.51%
2	< 5	26	48.14%	2	20-25	32	51.85%
3	Unable to void	11	20.37%	3	25-30	9	16.66%

Discussion

Numerous urethroplasty techniques have been described and but it is known that no single technique is appropriate for all strictures. Techniques are broadly grouped into anastomotic and substitution repairs. Strictures in the bulbar urethra are most often of traumatic origin from straddle injury, endoscopic instrumentation or catheterization. When less than 1cm in length, these are best managed by stricture excision and primary anastomosis . Excision of 1cm of urethra and associated 1cm spatulated repair results in a total of 2cm of urethral shortening, an amount that can be easily accommodated by the elasticity of mobilized bulbar urethra. If bulbar urethral stricture is more than 1cm in length it is repaired by primary anastomosis as there is a risk of causing penile chordee. If a 2cm stricture is excised and a 1cm spatulated anastomosis is performed, the total shortening would be 3cm and this may be excessive. We also prefer not to mobilize the urethra beyond the suspensory ligament of the penis, as this can increase the risk of chordee. Hence, a variety of alternative procedures that avoid penile shortening, chordee and tension on anastomosis may be used for strictures more than 1cm in length. For strictures up to 2cm in length, stricture excision and augmented anastomotic repair is a good option.¹¹ In more extensive bulbar strictures (>2cm in length), it is rarely possible to complete any type of anastomotic repair without causing some penile chordee and tension on the anastomosis. In these situations we have found success using a buccal mucosa graft applied to the dorsal aspect of the strictured portion of the bulbar urethra.

Mean operation time was 92 min in our study which is shorter than 123min mentioned by Arlen et al.¹² In our study single team harvested the graft and applied at stricture site. This operation time can be made better if two teams are employed. In 47 (87%) patients the procedure was successful. Success means no further procedure was required e.g. urethrotomy or dilatation. It is comparable with studies carried out by Barbagli.¹³ Andrich¹⁴ and Arlen.¹² Patients with urethral stricture who will need urethroplasty should not be subjected to unnecessary optical urethrotomies before urethroplasty because it will have adverse effects on outcome of urethroplasty.

The dorsal onlay graft (Barbagli procedure) has many advantages.² The dorsal approach to strictures of bulbar

urethra is anatomically simpler than the ventral one, requiring less extensive opening of spongy tissue since the urethral lumen is located dorsally in this region. Graft uptake is excellent. A serious complication of free graft urethroplasty is necrosis of the patch, caused by vascularization failure from its bed. When this occurs in ventrally placed graft, an urethro perineal fistula of considerable size is inevitable, this effect did not occur in patients treated with dorsal graft apposition.

Conclusion

Buccal mucosa graft urethroplasty produces excellent results in long bulbar urethral strictures which are not suitable for anastomotic urethroplasty. It is simple and quick to perform. Follow up, results are encouraging but a longer follow up is required to label it a gold standard procedure.

References

1. Mungadi IA, Ugboko VI. Oral mucosa graft for urethral reconstruction. *Ann Afr Med* 2009; 8: 203-9.
2. Barbagli G, Selli C, di Cello V, Mottola A. A one-stage dorsal free graft urethroplasty for bulbar urethral strictures. *Br J Urol* 1996; 78: 929-32.
3. Santucci RA, Mario LA, Mc Aninch JW. Anastomotic urethroplasty for bulbar urethral stricture: analysis of 168 patients. *J Urol* 2002; 167: 1715-9.
4. Dessanti A, Rigamonti W, Merulla V, Falchetti D, Caccia G. Autologous buccal mucosa graft for hypospadias repair: an initial report. *J Urol* 1992; 147: 1081-3.
5. Filipas D, Wahlmann U, Hohenfellner R. History of oral mucosa. *Eur urol* 1998; 34: 165-8.
6. Bhargava S, Chapple CR. Buccal mucosal urethroplasty: Is it a new gold standard? *BJU Intl* 2004; 93: 1191-3.
7. Webster GD, Brown MW, Koeft RB, Sihelnick S. Suboptimal results in full thickness skin graft urethroplasty using an extra penile skin donor site. *J Urol* 1984; 131: 1082-3.
8. Xu YM, Qiaoy, Sa YI, Wu DL, Zhang XR, Zhang J, et al. Substitution Urethroplasty of Complex and Long Segment Urethral Strictures: A Rationale for Procedure Selection. *Eur Urol* 2007; 51: 873-1154.
9. Markiewicz MR, Lukose MA, Margarone JE 3rd, Barbagli G, Miller KS, Chuang SK. The Oral mucosa graft: a systematic review. *J Urol* 2007; 178: 387-94.
10. Markiewicz MR, Margarone JE 3rd, Barbagli G, Scannapieco FA. Oral Mucosa Harvest: an Overview of Anatomic and Biologic Consideration. *Eur Assoc Urol* 2007; 5: 179-87.
11. Flynn BJ, Webster GD. Urethral stricture and disruption. In Graham SD, Glenn JF, Keans TE, eds. *Glenn's urologic surgery*. 5th ed. Philadelphia: Lippincott Williams and Wilkins, 2004; pp 394-407.
12. Arlen, Angela M , Charles R. Buccal mucosa graft urethroplasty. *Sci W J* 2010; 10: 74-9.
13. Barbagli G, Palminteri E, Guazzoni G, Montorsi F, Turini D, Lazzar M. Bulbar urethroplasty using buccal mucosa grafts placed on ventral, dorsal or lateral surface of the urethra: Are results affected by the surgical technique? *J Urol* 2005; 174: 955-8.
14. Andrich DE, Mundy AR. Substitution urethroplasty with buccal mucosal free grafts. *J Urol* 2001; 165: 1131-4.