

A critical step in the operative management of non-functioning asymptomatic Incidentaloma

M. H. Ather (Section of Urology, The Aga Khan University Hospital, Karachi.)
S. Altaf,A. Memon (Department of Surgery, The Aga Khan University Hospital, Karachi.)

Introduction

Incidentalomas are more frequently diagnosed now due to easy availability of radiological diagnostic techniques. These tumors pose a new challenge for development of therapeutic and preoperative evaluation strategies.

The natural course of adrenal incidentalomas and the risk that such lesions lead to hormonal hypersecretion and malignancy are still under evaluation. Factors influencing transformation of a truly non-functioning incidentaloma into a hypersecretory or a malignant tumor are not entirely known. Surgery is recommended on the basis of functional type of the tumor and the potential for malignancy. Tumor size is being recommended to be the most reliable criterion for malignant potential. Surgery for adrenal tumors is fraught with perioperative complications unless the patient has been preoperatively prepared. The worst case scenario is seen in cases of pheochromocytoma, which are not preoperatively prepared as this case demonstrates.

There are no clear recommendations in contemporary literature as to the pre-operative preparation of non-secretory, asymptomatic incidentaloma in normotensive individuals with normal biochemical and endocrinological profile.

Case Report

A 61-year-old normotensive man, with recently diagnosed diabetes mellitus presented with urinary tract infection and poorly controlled diabetes. The initial management was focused on his uncontrolled diabetes, which required very high doses of insulin. To rule out secondary diabetes besides other investigations an abdominal ultrasound was done. This revealed a 6 x 4 cms. mass on the upper pole of the left kidney. Fine needle biopsy of this mass was inconclusive. CT scan Figure 1

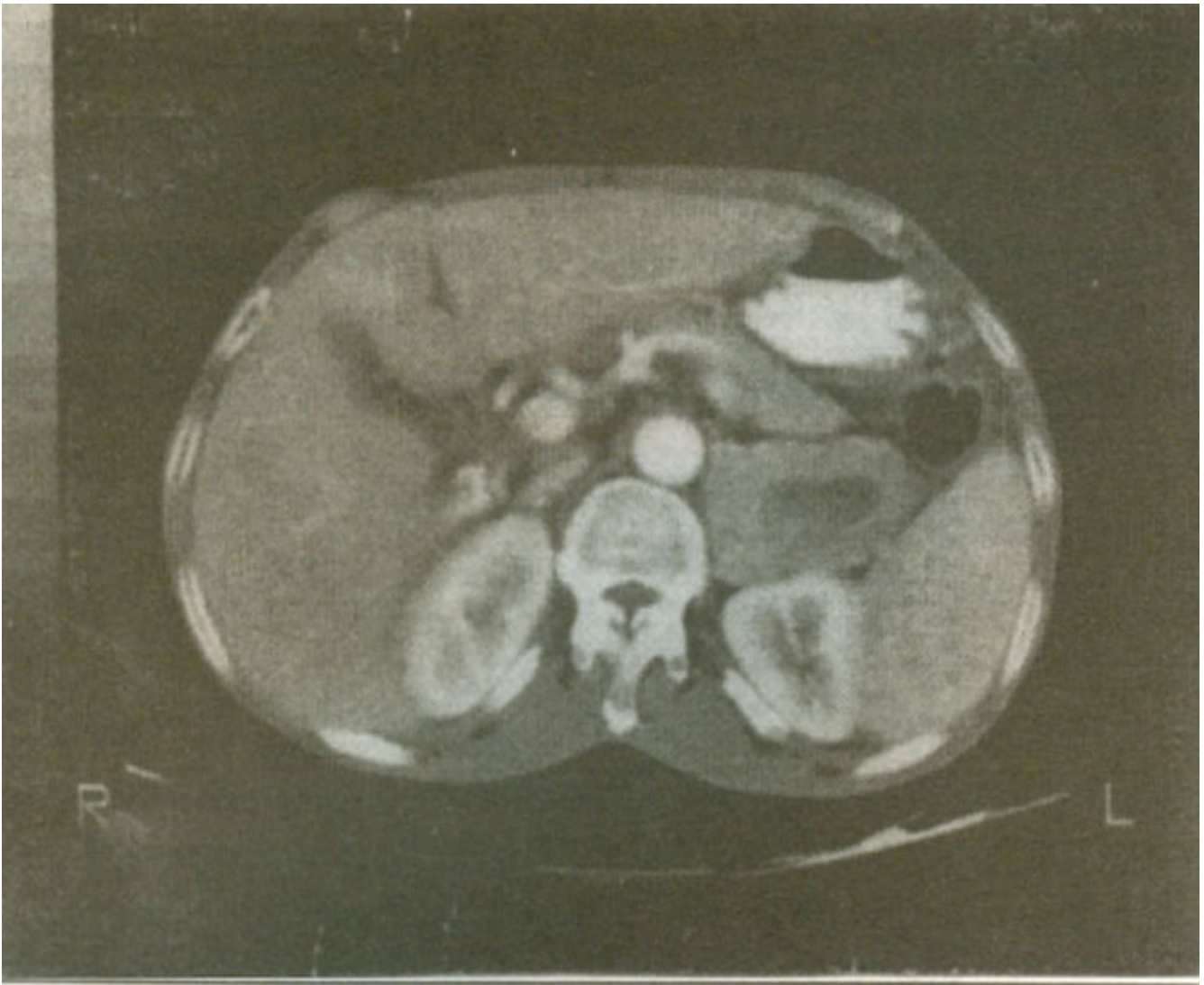


Figure 1. CT scan of the abdomen showing left supra-renal with necrotic center

confirmed the impression of localized well-circumscribed left adrenal mass. Extensive serum and urinary endocrinological work-up was normal. Based upon the criteria of tumor size alone, he was offered adrenalectomy for a non-secretory, non-functioning incidentaloma. By an 11th rib incision left lumbar space was opened and tumor approached retro peritoneally. His blood pressures at the time of induction was 120/80 mmHg. However when the adrenal gland was handled, blood pressure shot up to 210/140 mmHg requiring aggressive management by anesthetic and pharmacological agents. Soon after the ligation of pedicle and removal of the tumor the blood pressure dropped down to 60/40 mmHg (Figure 2).

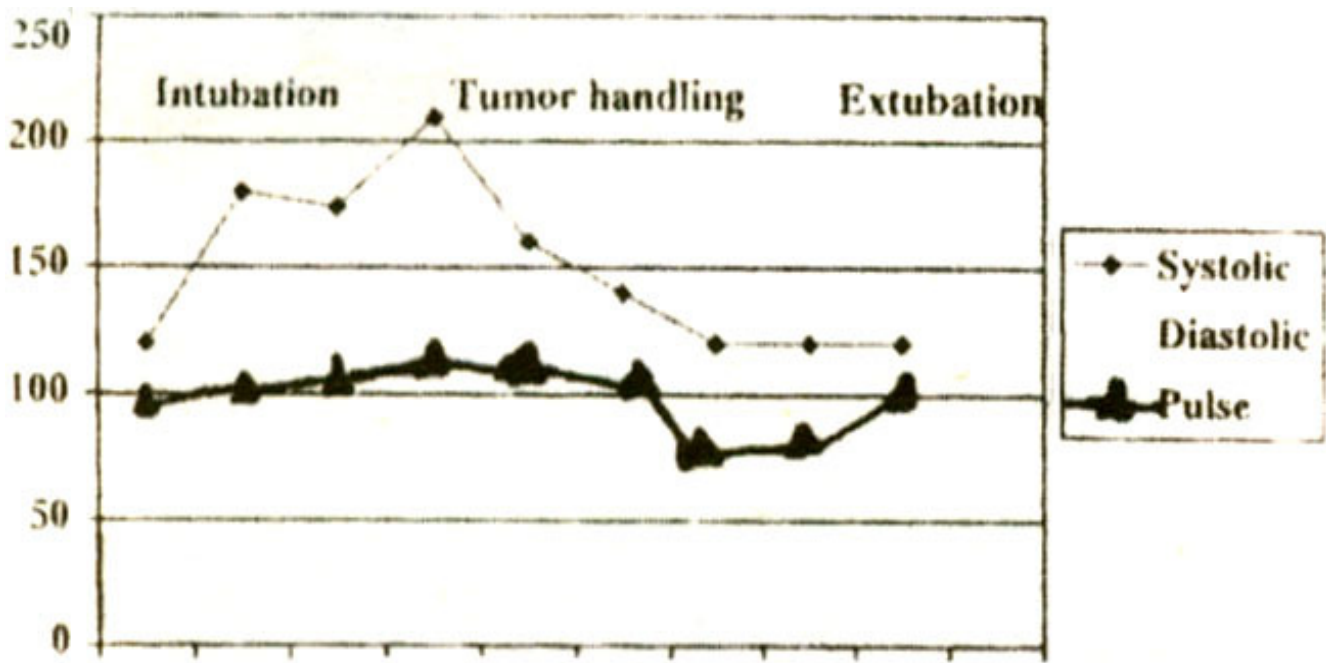


Figure 2. Hemodynamic alterations during surgery, showing blood pressure and pulse variation between intubation and extubation.

Preoperative behavior and histological picture confirmed the diagnosis of pheochromocytoma. For the first 24 hours he stayed in the ICU where his blood pressure stabilized with volume replacement alone and without pressor agents. His blood sugar however remained normal without the use of insulin. He made an unremarkable recovery and was discharged on the 8th postoperative day. At six months of follow-up, he is euglycemic and normotensive.

Discussion

There is no information about the preoperative preparation of an asymptomatic non-functioning adrenal incidentaloma. Based upon the criteria of size, the cut-off value varies in literature from 5-6 cm concerning decision for conservative versus operative management¹. The preoperative preparation of pheochromocytoma is mandatory with the use of α and β adrenergic blocking agents and volume expansion with preoperative intravenous fluids. Routine use of β blocking agents is not recommended unless, patients have cardiac arrhythmias or tachycardias.

Use of β -blockade without α -blockade can cause a hypertensive crises. Use of agents like α -methyl L-tyrosine (metyrosine), which blocks synthesis of norepinephrine can also be used in selected patients. This approach has advantage of reducing the catecholamine levels to normal but has the disadvantage of causing sleepiness and diarrhea. Intraoperative arterial lines and ready access to nitroprusside and phentolamine are essential to manage hypertension related manipulation of the tumor. The anesthetic agent of choice is enflurane, which does not stimulate catecholamine secretion or increase risk of catecholamine induced cardiac variability.

Following the removal of tumor hypotension is common as is seen in this case and it should be treated with large volumes of crystalloid. Pressor agents should be reserved for instances when volume expansion fails to correct hypotension. This is often due to down regulation of α adrenergic receptors. In such a situation volume expansion alone is inadequate.

Based upon ours and reported experience of other investigators^{2,3}, we recommend that they should be preoperatively prepared like pheochromocytoma, to avoid potentially life threatening hemodynamic

fluctuations, and be given a blocking agents as well as adequate volume expansion.

References

- 1.Barzon L, Scaroni C, Sonino N, Fallo et al. Risk factors and long term follow up of adrenal incidentaloma. *J. Clin. Endocrinol Metab.*, 1999;84:520-6.2.
- 2.Fischler L, Ensner R, Berhardi D Preoperaiively asymptomatic left adrenal incidentaloma. *Schweiz Med. Wochenschr.* 1999;129 1033-8.3.
- 3.Huang YC, Yang TC. Ho WM. Unexpected pheochromocytoma: a case report of anesthesia in a uremic patient. *Acta Anaesthesiol Sin* 1998.36 169-72.