

Dynamic contrast enhanced MRI breast for lesion detection and characterization with histopathological co relation: Preliminary experience at tertiary care hospital

Gulnaz Shafqat,¹ Ajmal Agha,² Imrana Masror,³ Mahwash Rehan,⁴ Shaista Afzal⁵

Department of Radiology,^{1,3-5} Department of Community and Health Sciences,² Aga Khan University Hospital, Karachi.

Abstract

Objective: To determine the morphological and enhancement characteristics significantly associated with malignant breast lesions on dynamic contrast enhanced MRI by considering the histopathological findings as a gold standard.

Methods: A retrospective analysis was performed on 70 patients who underwent MRI breast during the study period because of suspicious mammographic abnormalities. MR imaging was performed on 1.5 tesla machine with dynamic contrast enhancement by using dedicated breast coil. MR Images of breast were evaluated on a workstation and reported on the basis of morphological appearance of lesion and time activity curves. Histopathological analysis of the lesion was done either after mastectomy or biopsy. About 66 MR suspicious lesions were biopsied in 58 patients.

Results: Total number of MRI breast performed from Jan 2007- June 2009 for suspicious abnormality was 70. Histopathology of 66 lesions was available in 58 patients. Twelve patients were lost to follow. On multiple logistic regression analysis, lesions with irregular margins and strong heterogeneous enhancement were associated with higher odd of malignancy than lesions with smooth margins and homogenous enhancement. The next most important feature was the qualitative assessment of kinetic curve. Type 111 and 11 curves showed significant association with malignancy with higher odd values and 95% CI.

The sensitivity, specificity, positive and negative predictive values of MRI for breast lesions was found to be 94%, 85%, 90%, and 82% respectively. Overall accuracy of MRI breast was 90%.

Conclusion: On dynamic contrast enhanced MR imaging morphological appearance of lesion and qualitative assessment of time activity curves are two major factors for differentiation of breast lesion as benign or malignant.

Keywords: Breast cancer, MR mammography, Dynamic contrast enhancement (JPMA 61:252; 2011).

Introduction

Breast cancer the most common cancer of women, is the second leading cause of death among women in the developed world.¹ Risk in United States was 1 in 20 in 1960 to 1 in 8 today. The average 5 years survival rate for breast cancer in developed countries is 73% and in developing countries 57%.² In Pakistan, Karachi reports the highest incidence of breast cancer for any Asian population except Israel.³ According to KCR data set from 1995-1997 most common malignancy in females was breast (53.1%) The data set from 1998-2002 showed a rising incidence to 69.1% which is the highest recorded rate of breast cancer in Asia.³⁻⁵

At present the conventional mammography, ultrasonography and physical examination are the most widely employed non invasive screening methods for the detection of breast cancer and are invariably integral parts of routine examination. However, these techniques have limited sensitivity and specificity for the detection and diagnosis of breast cancer.⁶ Mammography is a sensitive tool for the detection of early breast cancer.⁷ The sensitivity of

mammography for index cancer varies from 63% to 98%^[8] and has been reported to be as low as 30% to 48% in dense breasts which are more frequently associated with increased risk of breast cancer.⁹⁻¹¹ Due to high false positive rates of mammography, biopsies are often performed unnecessarily and result in complications.^{7,8}

Early detection of breast cancer with appropriate staging is very essential for specific treatment and good prognosis. A less invasive test is needed to reduce patient's anxiety and suffering.

Breast magnetic resonance imaging is emerging as an important tool for the detection and characterization of breast cancer¹¹⁻¹³ It has the ability to image in three dimensions and provides good physiologic and morphologic information. In recent years results of many studies have shown that the non invasive techniques of MRI breast have a strong potential to improve sensitivity in the diagnosis and evaluation of breast cancer.⁷⁻¹⁵

Purpose of our study was to evaluate the morphological and enhancement characteristics of benign

and malignant breast lesions on dynamic contrast enhanced MRI by considering the histopathological findings as a gold standard.

Material and Method

This cross sectional analytical study was conducted at Aga Khan University Hospital Karachi. Duration of study was from Jan 2007- Jun 2009. Total 70 patients had an MRI breast because of known palpable or mammographic abnormality Clinically palpable lesions were 49 and suspicious mammographic abnormality in 21 lesions. Patients with known breast malignancy, recent breast surgery and radiotherapy were excluded. During the study period. 12 patients were lost to follow. Biopsied lesions were 66 in 58 patients and these were included in our study.

Dynamic contrast enhanced MR imaging was performed on 1.5tesla magnet (avanto; Siemens, Erlangen, Germany) by using dedicated bilateral breast surface coil. In premenopausal patients imaging was done from day 7 - 13 of menstrual cycle to prevent false positive results due to normal parenchymal enhancement.

All patients were imaged in prone position with breast pendent in the cups of the coil. Gentle compression device was used to minimize motion and transmitted vibration. Prior to positioning intravenous line was maintained with 20-22 gauge cannula which was connected to an automatic injector. The contrast agent magnevist was injected in a dose of 0.1mmol (0.2ml) per kilogram body weight as bolus, and was followed by saline flush.

MRI sequences were those which improve the lesion conspicuousness such as fat suppression, computer subtraction technique, three dimensional techniques to generate thin slices and to allow multiplanar reconstruction and a dedicated breast coil to optimize signal- to- noise ratios.

Breast MR imaging sequences prior to contrast administration, includes T2 axial stir (fat sat), Plain T2 axial, T1 flash non fat sat, Diffusion reveal, T2 sagittal fat sat and axial T1 weighted 3D fat suppressed gradient echo sequences before and four times after rapid injection of contrast with maximum slice thickness of 2-3 mm. The total duration of the dynamic study was approximately 6-7minutes. After the examination, subtraction images were obtained on a pixel by pixel basis and followed by Delayed coronal images. Volume acquisitions enabled re-formatting in other planes and maximum intensity projection.

Breast MR Scan was reviewed by three radiologists in consensus at workstation. The radiologists were aware of the patient breast quadrant containing the clinical or mammographic abnormality.

Lesions were characterized on the basis of morphology which includes pre contrast visualization of lesion, lesions margins and type of enhancement. The dynamic parameters were degree of enhancement and time-signal intensity curves, which were acquired with the help of dedicated soft ware on computer. These curves assessed the initial slope of enhancement, occurring generally within the first two minutes after contrast administration, and later enhancement behaviour. Three types of time signal intensity curves were obtained. Type-I (progressive) curve; enhancement continues to increase with each post contrast sequence. Type-II (plateau) curves; enhancement levels off after the first post contrast sequence. In the Type-III (washout) curve; enhancement decreases after initial rise. These curves were obtained with the use of region of interest (RIO) method.

Results

Patient age range from 22-72 years with the mean age of 44.4 ± 12.2 years. Biopsy proven lesions were 66 in 58

Table: Multiple logistic regression analysis.

	Malignant n (%)		Benign n (%)		OR	95% CI	AOR	95% CI	
Precontrast									
No	3	7.9	9	32.1	1.00		1.00		
Yes	35	92.1	19	67.9	5.53	(1.3-22.9)	9.97	1.32	75.18
Margins									
Smooth	7	18.4	17	60.7	1.00		1.00		
Lobular	3	7.9	7	25.0	17.00	(4.3-66.8)	6.4	1.01	40.56
Irregular	28	73.7	4	14.3	16.33	(3.0-90.4)	19.3	1.72	216.08
Enhancement									
Homo or non mass	8	21.1	22	78.6	1.00		1.00		
Hetero	30	78.9	6	21.4	13.75	(4.2-45.3)	6.28	1.05	37.47
Degree of enhancement									
Mild or moderate	13	34.2	19	67.9	1.00		1.00		
Strong	25	65.8	9	32.1	4.06	(1.4-11.5)	1.85	0.3	10.93
Curves									
One	3	7.9	18	64.3	1.00		1.00		
Two or three	35	92.1	10	35.7	21.00	(5.1-86.0)	13.6	2.13	86.26

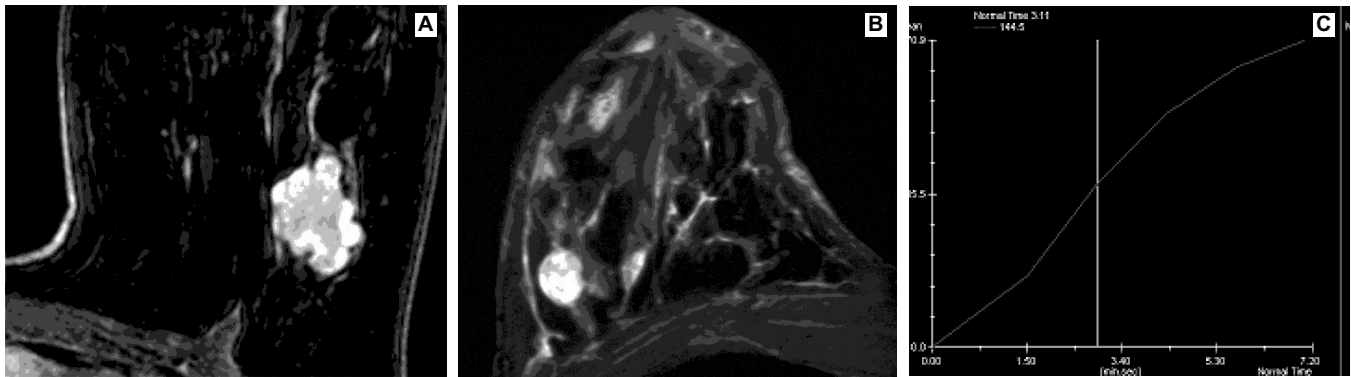


Figure-1: T1 post contrast subtraction image showing: Enhancing well defined. A- lobulated B- round mass C- Type 1 TAC. Biopsy proven cases of fibroadenomas.

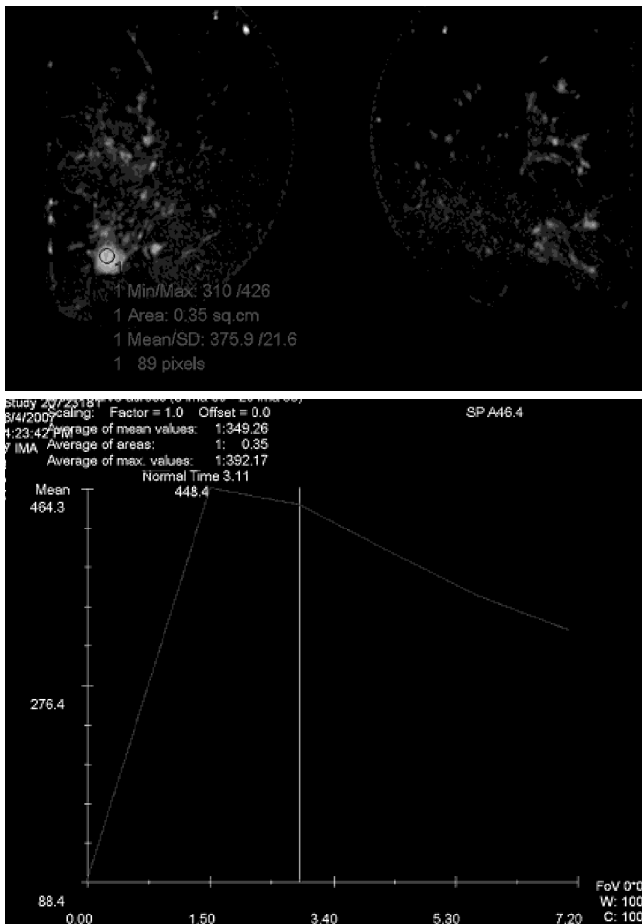


Figure-2: Post contrast subtraction image showing: A- Strongly enhancing mass in RT breast. B- Type 111 TAC.

patients. Mean lesion size was 1.9 ± 0.82 cm. There were 38(57.5%) malignant and 28(42.2) benign lesions on histopathology. Of the 38 malignancies 26 were invasive ductal carcinoma, 7 invasive lobular carcinoma, 3 mucinous carcinoma and 2 were ductal carcinoma in situ. Benign lesions were 18 fibroadenomas, 3 papillomas, and 5 were atypical ductal and 2 lobular hyperplasia. On pre contrast

images 35 (92.1%) malignant were visualized as focal masses. Out of 38 lesions, 3 (7.9%) malignant lesions were not picked on pre contrast study and visualized on post contrast study only as area of diffuse segmental enhancement. On histopathology two of them were ductal carcinoma in situ while one lesion was invasive lobular carcinoma. Benign lesions visualized on pre contrast imaging were 18 (67.8%). Out of 28 benign lesions 9 (32.1%) were not seen on pre contrast imaging and were visualized as focal enhancement less than centimeter or non mass like enhancement on post contrast study. These were lobular and ductal hyperplasia, fibroadenomatoid change and papilloma. All focal masses either benign or malignant were visualized on pre contrast imaging.

On post contrast imaging, heterogeneous enhancement was noted in 30 (78.9%) malignant while homogenous enhancement was a feature of benign lesions in 22 (78.6%) (Figure-1). Moderate to strong enhancement was the feature of 34 (94.4%) malignant and 18 (75%) benign lesions. Irregular margins of lesions was noted in 28 (73.7%) malignant lesions (Figure-2) while smooth and lobulated margins were associated with benign lesions in 24 (95.7%). Out of 38 malignant lesions, 35 (97.2%) were exhibiting type 11 and 111 curves as compared to benign lesions in 19 (79.1%).

The sensitivity, specificity, positive and negative predictive values of MRI for breast lesions was found to be 94 %, 85%, 90%, and 82% respectively. Overall accuracy of MRI breast was 90%. In multiple logistic regression analysis Tab 1, margins [Lobular vs Smooth (AOR 6.4; 95% CI, 1.01-40.56) and Irregular vs. Smooth (AOR 19.3; 95% CI, 1.7-216.1)], enhancements [Heterogeneous vs. Homogenous (AOR 6.28; 95% CI, 1.05-37.5)], presence of precontrast [Yes vs. No (AOR 9.9; 95% CI, 1.3-75.2)] and Time Activity Curves (TAC) [Type Two-three vs. Type One (AOR 13.6; 95% CI, 2.1-86.2)] were found significant.

Finally it was observed that 66 lesions identified as suspicious by mammography and clinical examination, MRI breast correctly picked 24 (36%) benign and 36

(55%) malignant lesions. Our study determined that MRI breast as an adjunct to mammography can reduce an invasive procedure by 36%. In all 38 (58% of all nodules) were malignant on histopathology and out of them 36 (55% of all nodules) were picked correctly by MRI. It was thus concluded that MRI can reduce an invasive procedure by 42%.

Discussion

Detection of breast cancer is the primary aim of breast imaging. The combination of decreased mammographic sensitivity and increased prevalence of breast cancer in denser breasts has prompted interest in the investigation of supplemental screening with ultrasound or even MRI. Advantages attributes of MR imaging for diagnostic evaluation of breast cancer includes high soft tissue contrast, multiplanar sectioning, which permits the acquisition of contiguous thin sections that enable a full three-dimensional representation of breast; and the absence of ionizing radiation.

The sensitivity of MR imaging for detection of breast cancer is very high, and approaches 100% for invasive carcinoma. However the specificity is low and varies between 37-70.^{6,11} The factors associated with this wide range of specificity are differences in the study population, strength of magnet, imaging protocols, and interpretation criteria.¹⁶ Multiple studies were done in the past to improve specificity. Study done by Khatri et al¹⁷ showed that improved specificity could be obtained by quantification of lesion enhancement. This method involved complex mathematical analysis. Another Study done by Siegman et al¹⁸ showed that both qualitative and quantitative lesion characteristics were required for lesion differentiation. In our study we found that morphological appearance of lesion on post contrast study and qualitative assessment of time signal intensity curves are most useful imaging parameters for breast MRI. Our results are comparable to most of studies^{19,20} done in the past.

In our setup MR imaging is in its evolving phase. Although our results are comparable to most of the previous studies, still there are a few limitations. It is a retrospective study. The sample size is small, (as during the two and half year period only 70 patients underwent MR examinations). This is because of cost factor and lack of awareness regarding usefulness of MR imaging for the diagnosis of breast cancer.

Conclusion

MR imaging of breast is a new evolving modality. The basic drawback of this modality was low specificity for breast malignancy. Multiple studies have shown that with the

improvement in equipment and technique there is gradual increase in specificity. However more such studies are needed to develop confidence in this emerging imaging modality for better patient management and to avoid unnecessary biopsies.

References

1. Soliman AS, Samadi S, Banerjee. Brief Continuing Medical Education Module Raises Knowledge of Developing Country Physicians. *Int Elect J Health Education* 2006; 9: 31-41.
2. Bray F, McCarron P, Parkin DM. The changing global patterns of female breast cancer incidence and mortality. *Breast Cancer Res* 2004; 6: 229-39.
3. Ahmed F, Mahmood S, Hatcher J, Khan SM. Breast cancer risk factor knowledge among nurses in teaching hospital of Karachi, Pakistan: a cross sectional study. *BMC Nurs* 2006; 5: 6.
4. Bhurgari Y. Karachi Cancer Registry Data-Implications for the National Cancer Control Program of Pakistan. *Asian Pac J Cancer Prev* 2004; 5: 77-82.
5. Malik IA. Clinico-pathological features of breast cancer in Pakistan. *J Pak Med Assoc* 2002; 52: 100-4.
6. Pedicini F, Catalano C, Occhiato R, Veditti F, Fraioli F, et al. Breast lesion detection and characterization with contrast-enhanced MR mammography: gadobenate dimeglumine versus gadopentetate dimeglumine. *Radiology* 2005; 237: 45-56.
7. Boetes C, Mus RD, Holland R, Barentsz JO, Strijk SP, Wobbes T, et al. Breast tumors: comparative accuracy of MR imaging relative to mammography and US for demonstrating extent. *Radiology* 1995; 197: 743-7.
8. Oriol SG, Schnall MD. MR Imaging of the breast for the detection, diagnosis and staging of breast cancer. *Radiology* 2001; 220: 13-30.
9. Kerlikowske K, Grady D, Barclay J, Sickles EA, Ernster V. Effect of age, breast density, and family history on the sensitivity of first screening mammography. *JAMA* 1996; 276: 33-8.
10. Mandelson MT, Oestreicher N, Porter PL, White D, Finder CA, Taplin SH, et al. Breast density as a predictor of mammographic detection: comparison of interval and screen-detected cancers. *J Natl Cancer Inst* 2000; 92: 1081-7.
11. Kolb TM, Lichy J, Newhouse JH. Comparison of the performance of screening mammography, physical examination, and breast US and evaluation of factors that influence them: an analysis of 27,825 patient evaluations. *Radiology* 2002; 225: 165-75.
12. Jacobs MA, Barker PB, Blumke DA, Maranto C, Arnold C, Herskovits EH, et al. Benign and malignant breast lesions: diagnosis with multiparametric MR imaging. *Radiology* 2003; 229: 225-32.
13. Shnall MD, Rostan S, Englander S, Oriol SG, Nunes LW. A combined architectural and kinetic interpretation model for breast MR images. *Acad Radiol* 2001; 8: 591-7.
14. Szabo BK, Aspelin P, Wiberg MK, Bone B. Dynamic MR imaging of the breast: analysis of kinetic and morphologic diagnostic criteria. *Acta Radiol* 2003; 44: 379-86.
15. Lehman CD, Blume JD, Weatherall P, Thickman D, Hylton N, Warner E, et al. Screening women at high risk for breast cancer with mammography and MR imaging. *Cancer* 2005; 103: 1898-905.
16. Bedrosian I, Mick R, Orel SG, Schnall M, Reynolds C, Spitz FR, et al. Changes in the surgical management of patients with breast carcinoma based on preoperative magnetic resonance imaging. *Cancer* 2003; 98: 468-73.
17. Khatri VP, Stuppino JJ, Esponia MH, Pollack MS. Improved accuracy in differentiating malignant from benign mammographic abnormalities: a simple, improved magnetic resonance imaging method. *Cancer* 2001; 92: 471-8.
18. Siegman KC, Muller Schimpfle M., Shick F, Remy TC. MR imaging detected breast lesions: histopathological correlation of lesion characteristic and signal intensity data. *Am J Roentgenol* 2002; 178: 1403-9.
19. Nunes LW, Schnall MD, Orel SG. Update of breast MR Imaging Architectural Interpretation Model. *Radiology* 2001; 219: 484-94.
20. Shnall MD, Blums J, Blumke DA, De Angelis GA, De Bruhl N, Harms S, et al. Diagnostic architectural and dynamic features at breast MR imaging: multicenter study. *Radiology* 2006; 238: 42-53.