

Lumbar Disc Prolapse: Management and Outcome Analysis of 96 Surgically treated Patients

A. Akbar (Department of Neurosurgery, Chandka Medical College, Larkana.)

A. Mahar (Department of Orthopedic Surgery, Chandka Medical College, Larkana.)

Abstract

Objective: To evaluate the presentation, diagnosis and management outcome of surgically treated patients of lumbar disc prolapse.

Design: This is a prospective study.

Setting and duration of study: The study was conducted at Department of Neurosurgery, Chandka Medical College Hospital, Larkana over a period of three years.

Subject and Methods: Patients were selected using following neuroimaging like plain radiographs, myelograms, CT myelograms and MRI Scan of lumbosacral spine. The operative procedure applied was hemilaminectomy and removal of herniated disc material. Postoperatively patients were analyzed for outcome by standard subjective analysis (Mac nab criteria), objective examinations and radiographic studies.

Results: There were 96 patients, 70 males and 26 females. Predominant mode of presentation was low back pain with radiation to leg (46.9%), neurogenic claudication in 18 patients (18.7%). Eighty Six percent of the disc prolapses were found at L4 L5 and L5 SI levels. Complication rate was 14.6% with infections being commonest. Excellent to good outcome was found in 85.4% of the cases. Mean follow up period was 18 months. **Conclusion:** Surgery for cauda equina syndrome and motor deficits has a good outcome with hemilaminectomy and is the best surgical option for large disc prolapses (JPMA 52:62,2002).

Introduction

Low back pain with or without sciatica is a major cause of morbidity throughout the world. The life time incidence is 50-70% and the incidence of sciatica may be as high as 40%. However clinically significant sciatica due to disc prolapse occurs in 4-6% of the population¹.

The degeneration of intervertebral disc from a combination of factors can result in herniation, particularly at the L4 L5 and L5 Si levels in more than 90% of the cases. The L3 L4 and L2 L3 accounts for the majority of remaining herniations². The presence of pain radiculopathy and other symptoms depend on the site and degree of herniation, detailed history, physical examination supplemented by neuroimaging can differentiate herniated lumbar disc prolapse from other causes of low back pain and sciatica³. The outcome from disc surgery depends upon the number of factors, such as careful selection of the patients⁴.

The aim of this study was to evaluate the presentation, diagnosis, management and outcome of lumbar disc prolapse in our surgically treated patients.

Patients and Methods

This study was conducted in the department of Neurosurgery, Chandka Medical College Hospital, Larkana from 1st June 1998 to 31st May 2001. It is a 1500 bedded tertiary care hospital which provides care to upper Sindh (Larkana and Sukkur divisions), vast areas of Baiochistan and some areas of Punjab (district Rajanpur).

Data of the patients who were selected for surgery were entered in the proforma which included, age, sex, profession, detailed history of low back pain, findings of clinical examination, details of routine baseline investigations, neuroimaging, operative details, postoperative complications and outcome on follow up. Neuroimaging included plain radiographs of lumbosacral spine, myelogram, computed tomography with myelogram (C.T. myelogram) and MRI scan of lumbosacral spine. Patients selected for surgery in this study were suffering from Cauda Equina syndrome, progressive neurological deficit, profound neurological deficits such as foot drop and severe and disabling pain refractory to 4-6 weeks of conservative treatment. Conservative treatment consisted of steroid or non steroid anti inflammatory agents combined with bed rest and followed by physiotherapy. The above criteria for selection of the patients was strictly adhered and patients were treated by standard surgical technique (Hemilaminectomy and removal of herniated disc material)⁴. All surgeries were performed by the principal author. Postoperatively patients were analyzed for outcome by standard subjective analysis (Macnab's criteria⁵) objective examinations and radiographic studies including dynamic views to establish vertebral instability.

Results

A total of 96 patients were studied with the youngest being of 18 years age and oldest 58 years. Majority of the patients were between 31 to 45 years age group (Table 1).

Table 1. Age and sex distribution.

Age group	Sex		Total	
	Male	Female	No.	%
18-30 years	10	3	13	13.5
31-45 years	40	15	55	57.3
46-58 years	20	8	28	29.2
Total	70	26	96	100

Male to female ratio was 2.6:1. Mode of presentation was predominantly low back pain with radiation to leg as shown in Table 2.

Table 2. Mode of presentation of patients.

Presentation	No.	%
Low back pain with radiation to leg	45	46.9
Neurogenic claudication	18	18.7
Low back pain with sensory impairments	15	15.6
Low back pain with motor deficit (Foot drop)	12	12.5
Sphincter dysfunction	6	6.2

Neuroimaging consisted of mainly plain radiographs and myelogram, plain radiographs were taken in all patients (100%), myelogram in 86 (89.6%), C.T. myelogram in 3 (3.1%) and MRI scan in 7 patients (7.3%).

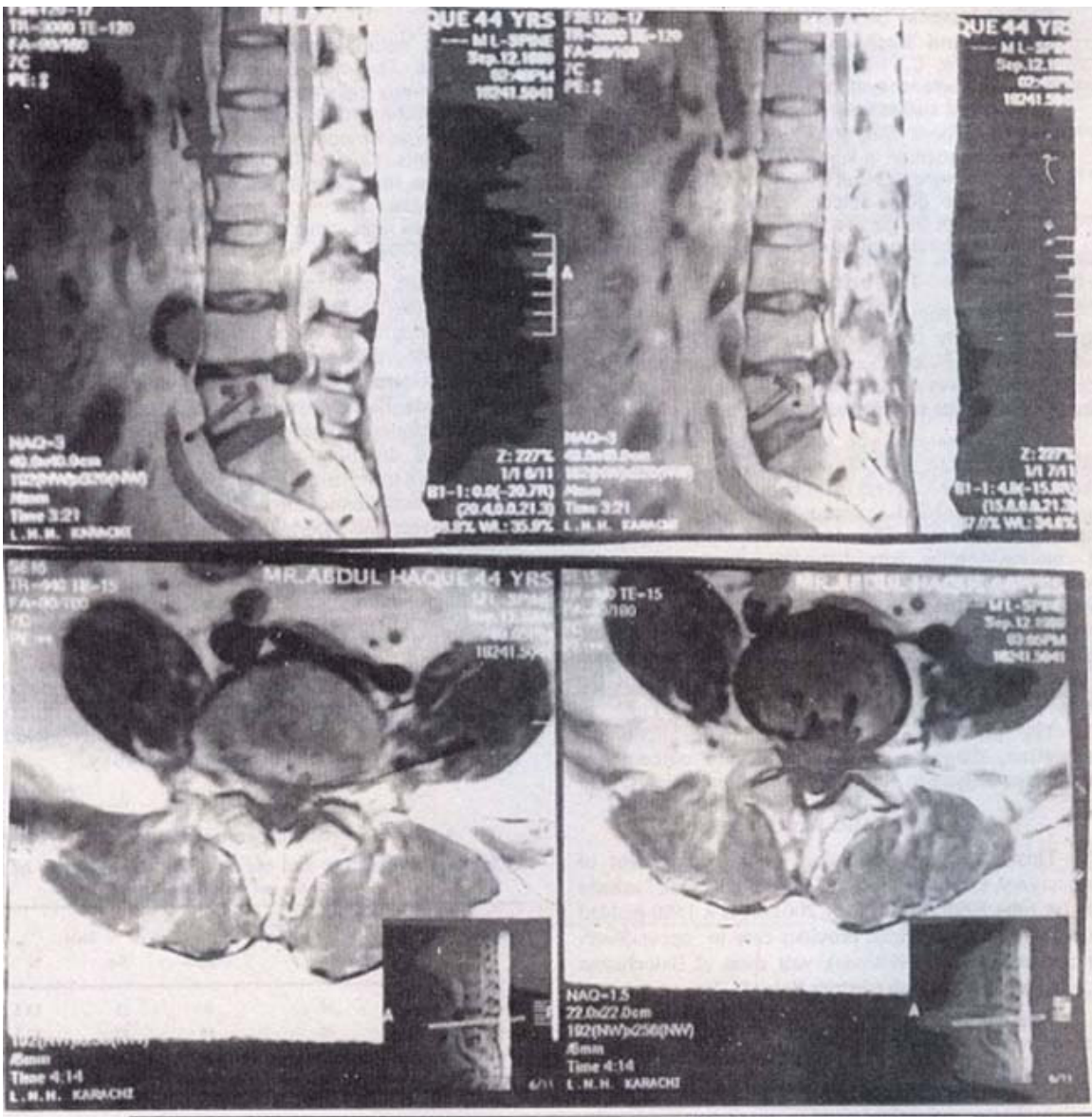


Figure 1. Midline sagittal and transverse MR images of the lumbosacral spine revealing disc herniation at L4-L5 region with thecal sac compression.

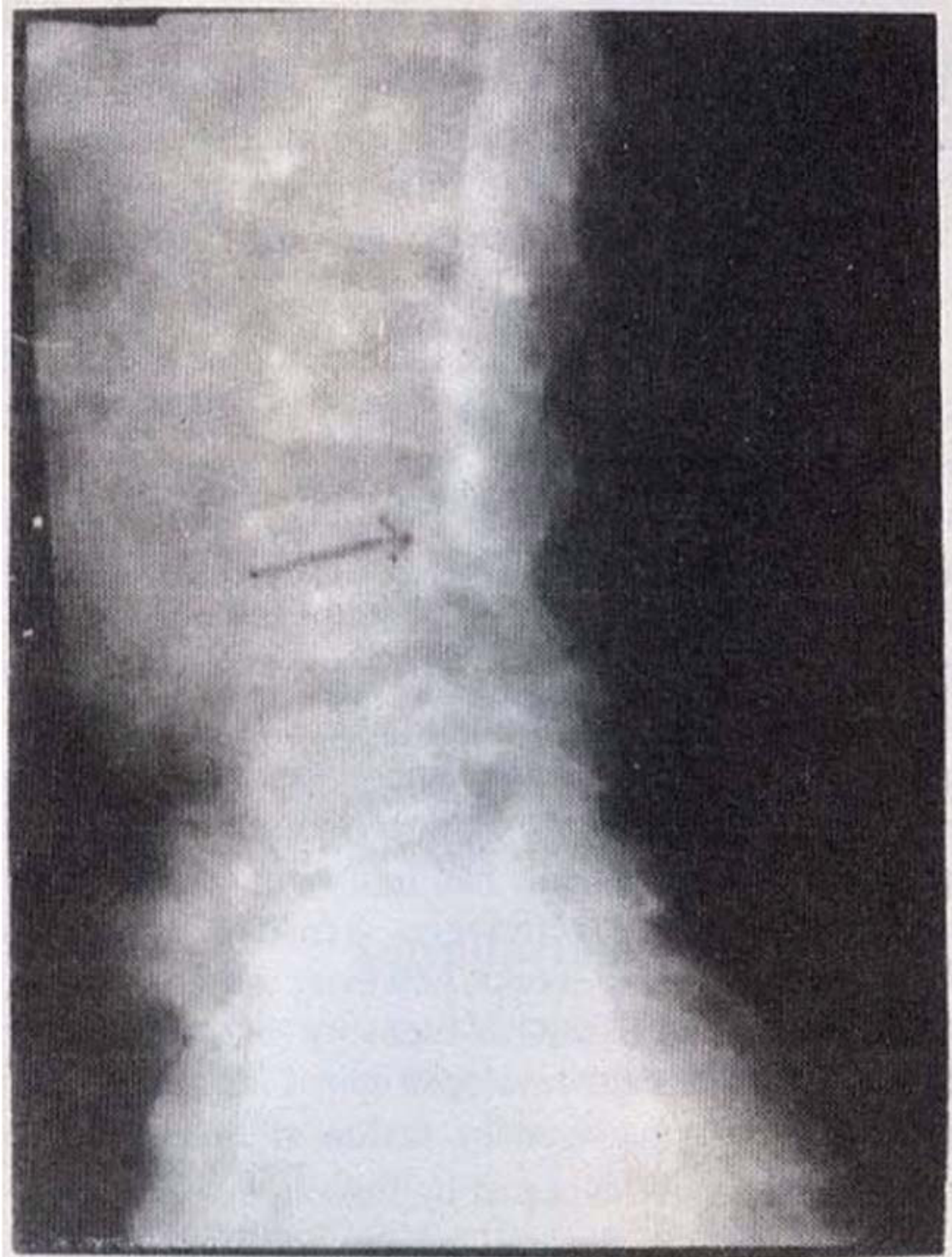

Figure 2. Lateral projection myelogram revealing L4, L5 disc prolapse with extruded disc fragment which has shifted upward to the posterolateral waist of vertebral body.

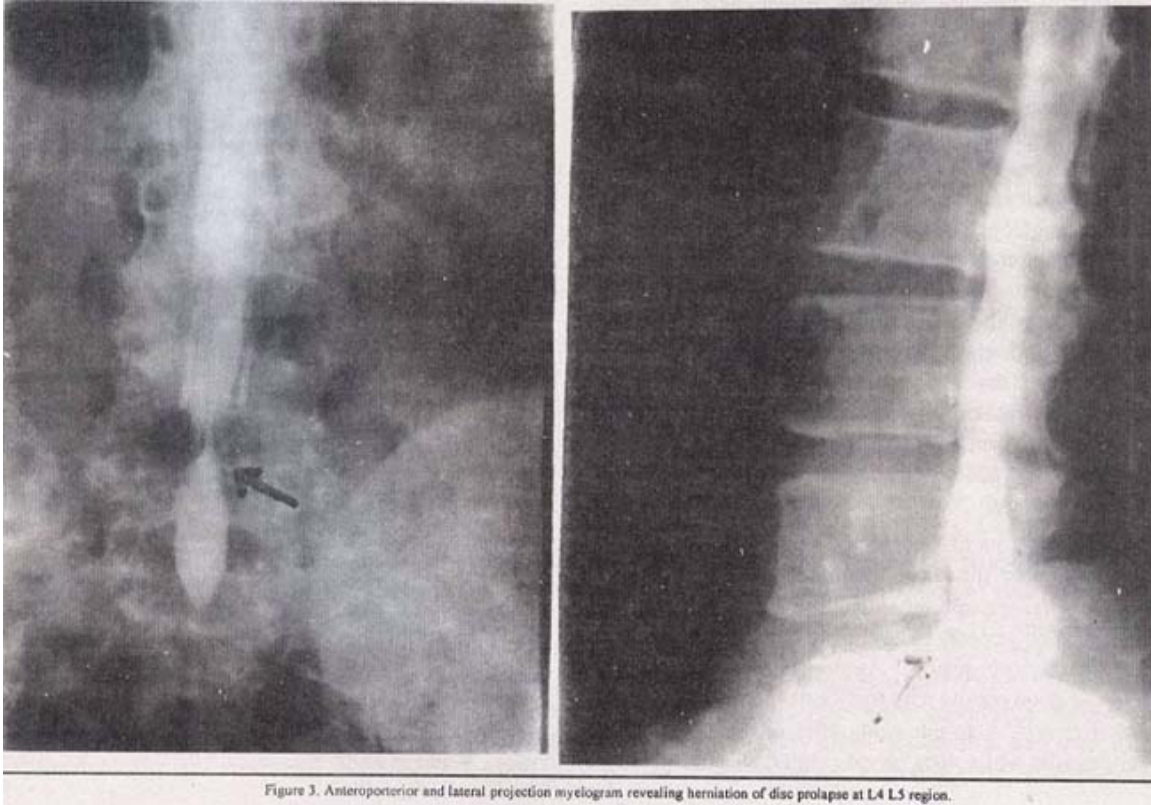


Figure 3. Anteroposterior and lateral projection myelogram revealing herniation of disc prolapse at L4 L5 region.

Figure 1, 2 and 3 reveal disc prolapse at various levels on myelogram and MRI scan of lumbosacral spine. Levels involved for disc prolapses in this study were L4, L5 in 48 patients (50%), L5 Si in 35 (36.4%), L3 L4 in 10 (10.4%) and L2 L3 in 3 cases (3.1%) . Per and postoperative complications encountered were dural tears in 5 cases (5.2%), disc space infections (diskitis) in 3 cases (3.2%), superficial wound infections in 4 cases (4.2%) while reexploration due to retained fragment causing significant postoperative pain was done in one case only. The mean-follow up period was 18 months (range 10 to

24 months). Treatment outcome was assessed by Macnab's criteria as shown in Table 3.

Table 3. Outcome of patients according to Macnab's criteria.

Macnab's Criteria	No.	%
Excellent	48	50.0
Good	39	40.6
Fair	5	5.2
Poor	4	4.2
Total	96	100

Discussion

Management of lumbar disc prolapse has been extensively studied because of its economic impact in the society¹⁻³. Age group mainly affected in this study was between 30 to 45 years, the main bread earners of families.

The reported frequency of occurrence of lumbar disc prolapse is highest at L⁴ L⁵ and L5 SI levels in 90% of the cases² while in our study it was seen at these levels in 86.4% of the cases. This is due to anatomy of the lumbar spine. In the upper lumbar spine extraforaminal space is proportionally larger than in the lower lumbar levels, other factors contributing to disc prolapse are increased mobility of lower segments resulting in earlier degeneration and disc prolapse⁶.

Myelogram was found useful, and a less expensive investigation in our study, because of its high reliability. However MRI scan is the gold standard investigation for the diagnosis of disc prolapses⁷. The major findings on plain radiographs of the patients with herniated disc is a decreased disc height. Radiographs have a limited diagnostic value because degenerative changes are age related and are equally present in symptomatic and asymptomatic cases⁷. MRI scan may reveal bulging of degenerative discs in asymptomatic cases because of its high sensitivity, therefore any management decision should be based on the clinical findings corroborated by diagnostic test results⁸.

The treatment of lumbar disc disease is the most controversial topic in the spine literature, as to whether surgical treatment should be attempted and if so which surgical approach is optimal. Since 1934, surgical treatment for lumbar radiculopathy due to disc prolapse has consisted of hemilaminectomy and removal of herniated material, which is called the standard surgical procedure⁴. In most of the cases in our study, a free fragment had shifted upward and was found in the posterolateral waist of respective superior vertebral body as in figure 2. This requires an important upward and lateral enlargement

of the intra laminar renestration. This is only possible with the hemilaminectomy which was found an effective surgical method in our study.

Outcome from disc surgery has generally been good, attempts have been made to determine factors that predict the success or failure of lumbar disc surgery^{10,11}. In general patients selection appears to be the most important factor to achieve satisfactory results. Approximately 80 to 90% usually have good results with traditional hemilaminectomy and diskectomy^{12,13}. In our study 50% of the patients had excellent results while 40% good results, because most of the patients presented for surgery after utilizing all other modes of therapies except surgery. Complication rate in our study was 14.6% with infection, remaining on the top (7.3%) followed by dural tears, as most of the disks were adherent to the spinal dura matter.

A diagnosis of cauda equina syndrome remains an absolute indication for urgent surgery. In the series of Buchner and Schiltenswolf^{14,12} of 17 patients had a complete recovery of urinary function. In our study 4 out of 6 patients had good control over urinary sphincters while 2 got partial control (stress incontinence) after 10 months of follow up. Motor deficit such as foot drop recovery was very slow and incomplete. Only 2 out of 12 cases had good recovery, 6 had partial recovery and 4 had no improvement after 6 months of follow up, indicating long term capacity of recovery. These 4 patients had foot drop Of more than 3 months duration preoperatively. Sensory impairment improved within 8 to 10 weeks, however, saddle anesthesia was found to be resistant to recovery in cauda equina lesions. One patient who developed spinal instability due to facet damage was managed by fusion after 3 months of hemilaminectomy as advocated by Epstein¹⁵.

References

- 1.Frymoyer J. Back pain and sciatica. N. Eng. j. Med., 1988;318:291-8.
- 2.Brandenberg GA, Traynelis VC. Disc disease of the spinal column. In: Grossman RG, Loftus CM (eds). Principles of neuro surgery. 2nd ed. 1999, pp.577.593.
- 3.Klein 3D, Garfin Sr. Clinical evaluation of patients with suspected spine problems. In: Frymoyer JW (ed). The adult spine 2nd ed. Phildeiphia: Lippencoit-Raven, 1997. PP. 319-40.
- 4.Padua R, Padua S. Romanini E, Ten to 15 year outcome of surgery for lumbar disc hemiations: radiographic instability and clinical findings. Eur, Spine J., 1999;8:70-81.
- 5.Mancnab I. Negative disc exploration: an analysis of causes of nerve root involvement in sixty eight patients. J. Bone Joint. Surg. 197 1;53A: 891-903.
- 6.Schneck CD, The anatomy of the lumbar spondylosis. Clin. Orthop.,1985;193:20.37.
- 7.Bell GR, Ross JS. Diagnosis of nerve root compression myelography, computed tomography and MRI. Orthop Clin. North. Am., 1992;23:405-19.
- 8.Borden SD, Wiesel SW. Lumbar spine imaging: role in clinical decision making. j. Am. Acad. Orthop. Surg., 1996;4:238-48.
- 9.Nachemson A, Zdeblick TA, O' Brien JP. Lumbar disc disease: what surgical treatment is effective? Spine, 1996;21:1835-8,
- 10.Junge A, Dvorak J, Ahrens S. Predictors of bad and good outcome of lumbar disc surgery: a prospecLive clinical study with recommendations for screening to avoid bad outcomes. Spine, 1995;20:460-8.
- 11.Barrios C, Ahrned M. Arrotegni JI, et al. Clinical factors predicting outcome after

surgery for herniated lumbar disc: an epidemiological multivariate analysis. *J. Spinal Disord.*, 1990;3:205-8.

12.Pappas CT, Harrington T, Sonntag VK. Outcome analysisn 654 surgically treated lumbar disc herinations. *Neurosurg.*, 1992;30:862-6.

13.Davis RA. Long term outcome analysis of 984 surgically treated lumbar discs, 3. *Neurosurg.*, 1994;80:415-421.

14.Buchner M, SchiltewolfM. Cauda equina syndrome caused by intervertebral disc prolapse, mid term results of 22 patients and review of the literature. *Neurothorop.* 2000;27:1 1-27.

15.Epstein NE. Evaluation of varied surgical approaches used in the.management of 170 patients for lateral disc herinations: indications and results. 3. *Neurosurg.*, 1995;83:648-56.