

## Case Report

### Cysticercosis of Soft Tissue

Nausheen Yaqoob,<sup>1</sup> Ershad ul Haq,<sup>2</sup> KhalidThomali,<sup>3</sup> Ali Kamran,<sup>4</sup> Ali Zaharani<sup>5</sup>  
King Abdul Aziz Specialist Hospital,<sup>1</sup> Departments of Pathology and Surgery, King Faisal Hospital,<sup>2-5</sup> Taif, KSA

#### Abstract

Cysticercosis is a systemic illness caused by dissemination of the larval form of the pork tapeworm, *Taenia solium*. A high prevalence has been reported from the developing countries because of the co-existence of poor sanitary conditions and domestic pig raising. Human cysticercosis occurs when eggs are ingested via faecal-oral transmission from a tapeworm host. The human then becomes an accidental intermediate host, with development of cysticerci within organs.

Cysticercosis is a preventable faeco-oral transmitted infection and it is possible to prevent infection by avoiding undercooked food and pork (which is an unlikely cause in muslim countries), and, water contaminated with human faeces.

#### Introduction

Cysticercosis is a systemic illness caused by dissemination of the larval form of the pork tapeworm, *Taenia solium*. A high prevalence has been reported from the developing countries because of the co-existence of poor sanitary conditions and domestic pig raising without veterinary control or surveillance systems.<sup>1</sup> It occurs mainly in Southern Africa, China, India, Central America, Chile, Brazil, Papua New Guinea, and non-Islamic South East Asia where human faeces reach pigs and pork is eaten raw or undercooked.

Humans are the definitive hosts and carry intestinal adult tapeworm. Intermittent faecal shedding of proglottids or free eggs occurs, and the intermediate host (normally pigs) ingests the excreted eggs in contaminated food or water. Embryos penetrate the GI mucosa of the pig and are haematogenously disseminated to peripheral tissues with formation of larval cysts. When undercooked pork is consumed, an intestinal tapeworm is formed again, completing the life cycle of the worm. Human cysticercosis occurs when eggs are ingested via faecal-oral transmission from a tapeworm host. The human then becomes an accidental intermediate host, with development of cysticerci within organs.

#### Case Report

A 32 year old female from Lucknow India, visited the medicine clinic with the complaint of a painless lump in

the neck for the past two years. On examination the mass was 3 x 3 cms in size, soft, mobile, not fixed to the overlying skin. It clinically looked like an enlarged lymph node. Thyroid was normal. No other associated signs or symptoms were seen. The patient also complained of mastalgia and laboratory investigations showed hyperprolactinaemia. Fine needle aspiration was performed which revealed proteinaceous material with acute and chronic inflammatory cells, suggestive of a benign cystic lesion.

The neck mass was surgically removed and sent for histopathological examination which showed milky white cysts containing fluid and a single invaginated scolex. Microscopically the scolex was surrounded by a cyst wall, two suckers were also visible (Figure-1). The cyst wall away from the scolex was thick and thrown into projections

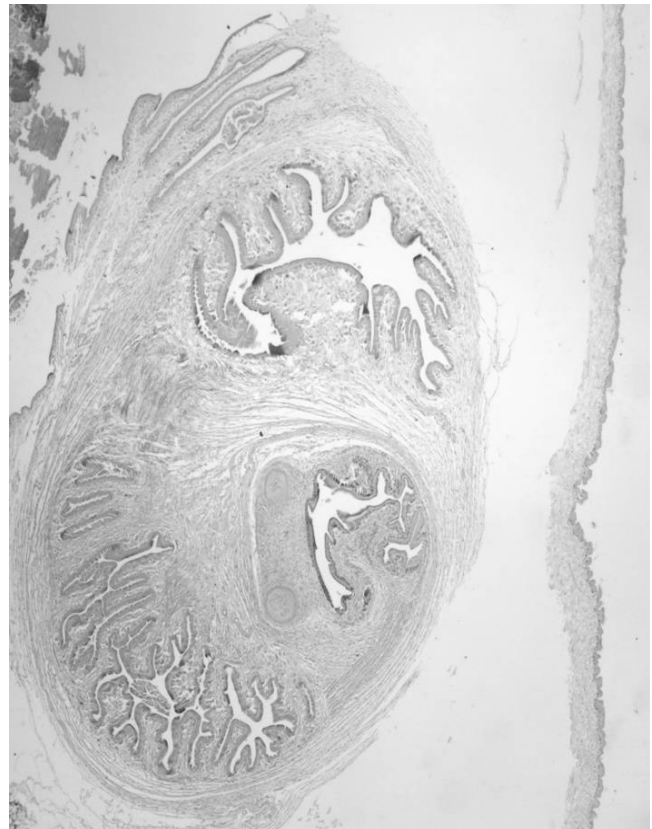


Figure 1: The cysticercus surrounded by fibrous tissue showing invaginated scolex along with two suckers. (Mag 20 x).

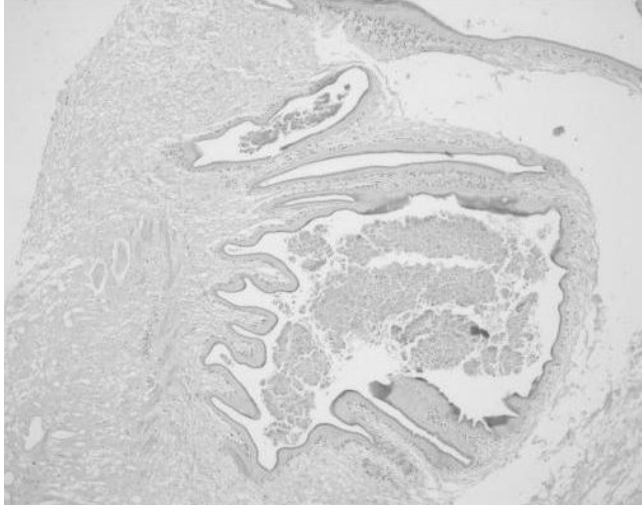


Figure 2: Higher magnification showing thick cyst wall thrown into projections. (Mag 20 x).

(Figure-2). Features were consistent with Cysticercosis. The patient had an uneventful post operative recovery. No medical treatment was given.

Although no neurological symptoms were present, MRI was performed to exclude the possibility of neurocysticercosis. MRI showed mild cerebral atrophy however no cystic lesion or any other abnormality was identified. Rest of the general physical and neurological examination was unremarkable.

## Discussion

Involvement of the central nervous system (CNS), known as neurocysticercosis (NCC), is the most clinically important manifestation of the disease. It may present with dramatic findings, and is an important contributor to neurologic morbidity in developing countries. It is also the major cause of acquired epilepsy in the world.<sup>1</sup> In most non-Muslim developing countries, it accounts for more than one-third of adult-onset epilepsy cases.<sup>2</sup>

Encystment of larvae can occur in almost any tissue. The most frequently reported locations are skin, skeletal muscle, heart, eye, and most importantly, the CNS.<sup>2</sup>

In the CNS, it can localize in the parenchyma (grey matter), ventricles (4th ventricle), cisterns, subarchnoid space and the spinal cord (extramedullary intradural). A special form, termed cysticercosis racemosa is a conglomeration of cysts in the subarchnoid space, is frequently seen in Latin America.<sup>3</sup>

The clinical and pathologic features of neurocysticercosis vary, depending on the inflammatory response around cysticerci, their number, size, and location and the host's immune response to infection.<sup>4</sup> The presence

of viable, living cysticerci in the central nervous system usually does not cause symptoms. Host inflammatory response to cysticerci depends on the parasite's ability to evade host immunity; therefore, inflammation is restricted to degenerating cysts. Cysts in various stages of viability can be seen simultaneously in one host. They calcify and undergo granulomatous change on involution.

Among the neurological manifestations seizures and headaches are the most common symptoms, however, confusion, lack of attention to people and surroundings, difficulty with balance, may also occur. Cysticerci within the basilar cisterns or Sylvian fissures may become quite large and may cause vasculitis and stroke. Spinal NCC is rare.

Kim et al<sup>5</sup> described the case of a 67-year-old man who presented with dizziness, nausea, and ataxia. Magnetic resonance imaging showed a large cystic lesion in the left cerebellar hemisphere. Haemangioblastoma was initially suspected as it is a cystic cerebellar tumour. Histopathology showed cerebellar neurocysticercosis. This case shows that neurocysticercosis should be considered in the differential diagnosis of giant cystic lesions in the cerebellum as surgical intervention may be unnecessary.

Ocular cysts are mostly vitreous, they may be found in subretinal locations. Cysts can impair vision by floating in the eye and can lead to blindness by causing retinal detachment. Visualization of cysts via fundoscopy may be diagnostic of the disease.

Skeletal muscle encystment usually is asymptomatic but may cause muscular pseudohypertrophy with a heavy parasite burden. Cysts may cause spasms, weakness, pain and may create subcutaneous nodules. Abdelwahab et al<sup>6</sup> reported a case of a 40-year-old man with cysticercosis presenting as a solitary tumor in the biceps brachii muscle. Magnetic resonance imaging suggested a cyst and histologic diagnosis was cysticercus. Solitary presentation of muscular cysticercosis is extremely rare. Our case was also of intramuscular cysticercosis.

Mani et al<sup>7</sup> presented a case of a solitary cysticercal cyst that involved the anterior abdominal wall musculature and was diagnosed with sonography. Sonograms revealed a well-defined cystic lesion with an eccentric hyperechoic area within it. An eccentric, echogenic, pedunculated structure was seen within the cystic area of the lesion without calcification. Inflammation and hypervascularity in the surrounding muscle was noted. Cysticercosis should be kept in mind if lesions with similar morphologic characteristics are encountered in the musculature or subcutaneous tissues during sonographic examination. Cardiac cysts may lead to conduction system abnormalities, abnormal rhythms or rarely heart failure.

Oral mucosa is a rare site for cysticercosis. Mazhari

et al<sup>8</sup> described eight cases of cysticercosis involving the oral cavity, all presenting with a solitary superficial mucosal nodule, of these four were in the buccal mucosa, two in the lips, one in the tongue and one in the gums.

Involvement of the breast is a rare presentation. Agnihotri et al<sup>9</sup> reported the case of a 22 years young married woman who presented with a painless mobile swelling in the right breast. Histopathological examination revealed the presence of typical cysticercus larva. Cysticercosis of the breast is rare and it should be considered as a differential diagnosis for a lump in the breast.

Diagnostic tests include laboratory investigations showing eosinophilia in the blood and CSF. Biopsy of the subcutaneous nodules, if any, may help. Only Serological tests are nondiagnostic. These include, indirect haem-agglutination test and enzyme linked immunosorbent assay (ELISA) which is about 80% sensitive in CSF. Lately, the enzyme linked immuno electro transfer blot (EITB) test has been introduced and reported to be 100% sensitive in patients with two or more viable lesions.

Radiological examination may show narrowed ventricles with extensive low attenuated areas in the parenchyma, sparing the cortex. A ring enhancing active lesion with surrounding oedema, is the second common. Radiological finding and a homogeneously enhancing lesion represents a dying larva. Calcified lesions are also common in CT. The racemose type appears as a bunch of grapes. The intraventricular types are better seen in MRI. MRI may reveal scolex as a high intensity inside a cyst.

Vijayaraghavan et al<sup>10</sup> described four different sonographic appearances of cysticercosis. In 2 patients intramuscular fluid collection was seen with a cysticercus cyst in it. In one patient, an irregular cyst with a small fluid collection was seen on one side. Whereas in the last patient,

multiple elliptical millet seed-shaped calcifications were seen in the liver, mesentery, and retroperitoneal fat.

A case of obsolete intramuscular cysticercosis diagnosed definitively by mitochondrial DNA analysis of extremely calcified cysts was reported by Yamasaki et al.<sup>11</sup>

Praziquantel and albendazole, have been used extensively in the treatment of cysticercosis and are the accepted therapies.

Cysticercosis is a preventable faeco-oral transmitted infection. It is possible to prevent infection by avoiding undercooked food and pork (which is an unlikely cause in Muslim countries), and water contamination with human faeces. Care should be taken in places with poor hygiene or meat inspection laws.

## References

1. García HH, Gilman RH, Gonzalez AE, Verastegui M, Rodriguez S, Garidia C, et al. Hyperendemic human and porcine *Taenia solium* infection in Perú. *Am J Trop Med Hyg* 2003; 68: 268-75.
2. Garcia HH, Gilman R, Martinez M, Tsang VC, Pilcher JB, Herrera G et al. Cysticercosis as a major cause of epilepsy in Peru. *Lancet* 1993; 341:197-200.
3. Sorvillo FJ, Portigal L, Degiorgio C, Smith L, Waterman SH, Berlin GW, et al. Cysticercosis-Related Deaths, California. *Emerg Infect Dis* 2004; 10:465-9.
4. Kramer LD, Locke GE, Byrd SE, Daryabagi J. Cerebral cysticercosis: documentation of natural history with CT. *Radiology* 1989;171:459-62.
5. Kim JH, Suh SI, Kim JH, Kwon TH, Chung HS. Giant neurocysticercosis cyst in the cerebellar hemisphere. *Neurol Med Chir (Tokyo)* 2006; 46:412-4.
6. Abdelwahab IF, Klein MJ, Hermann G, Abdul-Quader M. Solitary cysticercosis of the biceps brachii in a vegetarian: a rare and unusual pseudotumor. *Skeletal Radiol* 2003; 32:424-8.
7. Mani NB, Kalra N, Jain M, Sidhu R. Sonographic diagnosis of a solitary intramuscular cysticercal cyst. *J Clin Ultrasound* 2001; 29:472-5.
8. Mazhari NJ, Kumar N; Jain S. Cysticercosis of the oral mucosa: aspiration cytologic diagnosis. *J Oral Pathol Med* 2001; 30:187-9.
9. Agnihotri S, Talwar OP, Pudasaini S, Baral R. Cysticercosis of breast - a case report. *Pol J Pathol* 2006; 57:53-4.
10. Vijayaraghavan SB. Sonographic appearances in cysticercosis. *J Ultrasound Med* 2004; 23:423-7.
11. Yamasaki H, Nagase T, Kiyoshige Y, Suzuki M, Nakaya K, Itoh Y, et al. A case of intramuscular cysticercosis diagnosed definitively by mitochondrial DNA analysis of extremely calcified cysts. *Parasitol Int* 2006; 55:127-30.