

### **Fibromatous Periorchitis**

Khurram Minhas, Abrar Barakzai, Asim Qureshi

Department of Pathology & Microbiology, Aga Khan University, Karachi, Pakistan.

#### **Abstract**

We report a case of diffuse fibrous pseudotumour/fibromatous periorchitis, in a 43 year old male, that completely encased the right testis and was adjacent to a hydrocoele cavity. Although fibrous pseudotumours of this region are uncommon, they are reported to be the second most common benign paratesticular lesion after adenomatoid tumours. These comprise approximately 6 percent of paratesticular lesions, and are accepted as reactive lesions secondary to trauma, hydrocoele, infections or inflammation. Fibrous pseudotumours have a peak incidence in the third decade of life but can occur at any age. Clinically these lesions mimic malignancy resulting in the treatment by radical orchidectomy. Fibrous pseudotumours should be considered in differential diagnosis when one encounters a predominantly fibrocollagenous lesion.

#### **Introduction**

Benign intrascrotal fibrous proliferations are uncommon with most arising from the paratesticular region and have generally been considered variants of fibrous pseudotumours as reflected in the numerous designations, including chronic proliferative periorchitis, inflammatory pseudotumours, nodular and diffuse fibrous proliferations, proliferative funiculitis, fibroma, benign fibrous paratesticular tumour, fibrous mesothelioma, pseudofibromatous periorchitis, nonspecific peritesticular fibrosis, and reactive periorchitis.<sup>1,2</sup> Mostofi and Price suggested the term "fibrous pseudotumours" to encompass all reactive fibroinflammatory lesions of the testicular tunics.<sup>3</sup>

These "tumours" are usually nodular and involve the testicular tunics. Even more uncommon are fibrous pseudotumours that form diffuse band like fibroinflammatory proliferations that encompass the testis, also termed as fibromatous periorchitis. Clinically these lesions mimic malignancy resulting in the treatment by radical orchidectomy.<sup>1,2,4</sup>

We herein report another case of a fibromatous periorchitis/ diffuse fibrous pseudotumour that completely encased the right testis and was adjacent to a hydrocoele cavity.

#### **Case Presentation:**

We received a specimen, from a remote area of Pakistan, of a 43 year old man with clinical history of gradual right testicular enlargement over a period of few months with no significant associated medical history. Provisional clinical diagnosis was Seminoma and a radical orchidectomy was performed. Radiology and Serum AFP levels were not ordered.

The specimen consisted of a right testicular mass that measured 11.5 x 7 x 4 cm, with an attached spermatic cord that measured 3.0 x 1cm. Sections revealed the testis, which measured 2.5 x 2.5 x 2.0 cm in greatest dimension, almost completely encased by a thick, firm, white fibrotic band like tissue involving the tunica albuginea and vaginalis and the epididymis but not the spermatic cord (figure 1). The testicular parenchyma was tan, soft

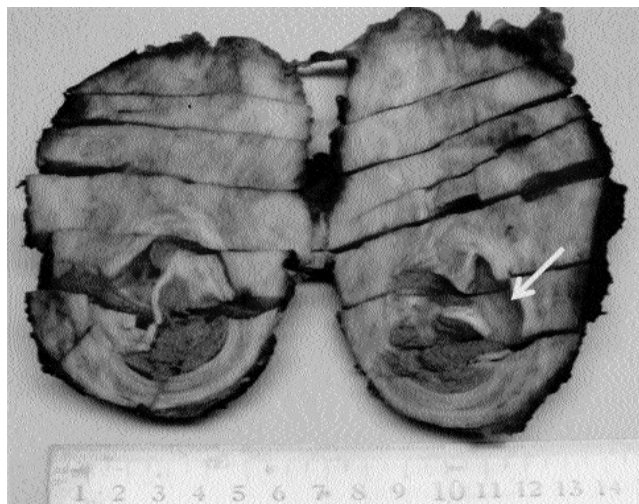

Figure 1: Section through testis and paratesticular mass demonstrating a fibrous lesion, that completely encased the testis. A cystic space compatible with a hydrocoele is present (arrow).

and unremarkable grossly. A hydrocoele cavity, was present adjacent to the testis with in the fibrous band, measuring 2.0 x 1.5 cm and filled with clear serous fluid.

Light microscopy showed a lesion composed of dense fibrous tissue with thick (keloid like) bands of collagen within which there were bland spindle cells and a mixed inflammatory infiltrate that almost totally encased the testis (figure 2). The

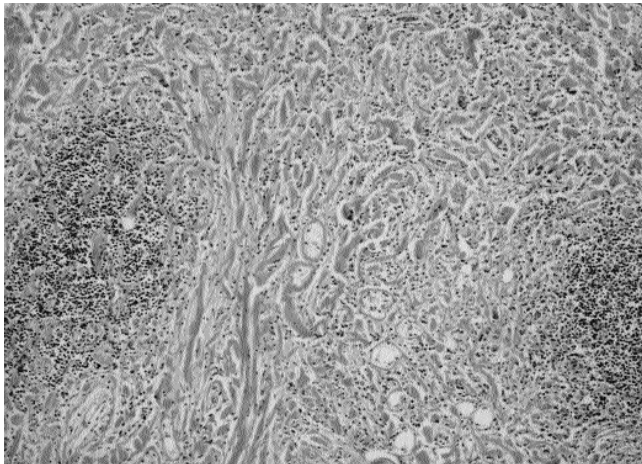


Figure 2: A fibrous lesion with keloid like collagen and foci of inflammation, including perivascular lymphoid aggregates (hematoxylin-eosin, original magnification  $\times 4$ ).

inflammatory infiltrate consisted largely of lymphocytes, plasma cells, and histiocytes with scattered neutrophils and eosinophils and in some areas it was perivascular. In other areas, the inflammatory infiltrate was sparse, was more pronounced and scattered small lymphoid aggregates were noted. No necrosis, increased mitotic activity, or cellular pleomorphism was noted. The lesion involved the tunica albuginea and vaginalis and surrounded the epididymis but did not involve the testicular parenchyma (figure 3) or spermatic cord. The hydrocoele cavity was within the fibrous lesion and contained mixed inflammatory cells and cellular debris. The testis showed

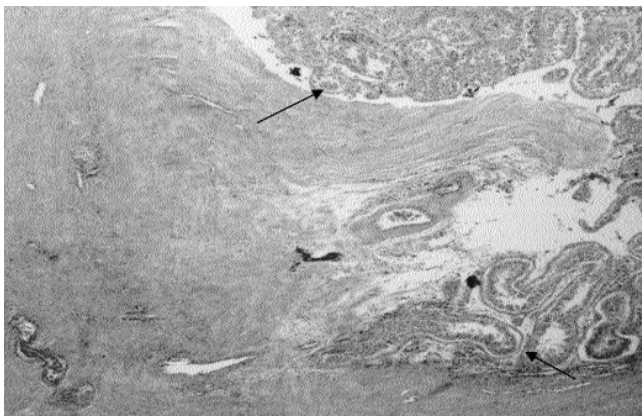


Figure 3: Benign testicular parenchyma (arrow) is seen within densely fibrotic lesion (hematoxylin-eosin, original magnification  $\times 4$ ).

tubular atrophy.

## Discussion

Fibromatous lesions of the testicular tunics were recognized first by Sir Astley Cooper in 1830.<sup>1</sup> The term fibrous pseudotumour, reflecting its non-neoplastic nature was introduced by Mostofi and Price.<sup>2</sup> Gross and microscopic differences, different opinion regarding the cell of origin and the neoplastic vs. non-neoplastic nature of these lesions has resulted in various terms including the following: nodular and diffuse fibrous proliferation, chronic proliferative periorchitis, inflammatory pseudotumour, proliferative funiculitis, fibromatous periorchitis, fibroma, benign fibrous paratesticular tumour, fibrous mesothelioma, pseudofibromatous periorchitis, nonspecific peritesticular fibrosis, and reactive periorchitis.<sup>3,5</sup>

Benign fibromatous proliferations occurring in the testicular tunics and paratesticular region are considered by most as reactive and non-neoplastic. But some authors including Parveen et al<sup>4</sup> and Jones et al<sup>5</sup> believe that at least some intrascrotal fibrous proliferations are truly neoplastic. The morphology of the reactive fibroblastic proliferations in this region may range from cellular pseudosarcomatous lesions to fibrotic hypocellular proliferations, often with calcifications or even with bone formation.

Jones et al<sup>5</sup> proposed a classification for benign fibrous proliferations of the testis and paratesticular region based on the neoplastic or non-neoplastic nature of the lesion and separated the lesions/tumours into various categories based on clinical and pathologic features, location, and immunohistochemical studies.

Although fibrous pseudotumours are uncommon, they are reported to be the second most common benign paratesticular lesion after adenomatoid tumours.<sup>2,6</sup> These lesions have been reported to comprise approximately 6 percent of para testicular lesions and tumours but the exact incidence is not known.<sup>7</sup> Fibrous pseudotumours have a peak incidence in the third decade of life but can occur at any age; only 4 cases have been reported in patients younger than 18 years.<sup>3,8</sup> They usually present as painless scrotal masses and range from 0.5 to 8.0 cm, but a 25.0 cm fibrous pseudotumour has also been reported. Forty-five percent of cases are associated with a hydrocoele, and 30 percent are associated with trauma or epididymo-orchitis.<sup>2</sup> They have also been reported to occur in patients with testicular infarction, schistosomias haematobium infection, retroperitoneal fibrosis, and Gorlin syndrome (nevroid basal cell carcinoma syndrome).<sup>3</sup>

Macroscopically, a clear distinction has been drawn by some investigators between the cases that show nodularity with nodules sometimes reaching several centimeters in diameter and those that show diffuse thickening of the tunics encasing the testis, although these tumours exhibit the same histopathologic

characteristics.<sup>8</sup> Latter was true for our case, as the lesion presented as a diffuse fibrous proliferation that encased the testis and was involving the tunics. This entity has been given the name "fibromatous periorchitis" by Ulbright et al.<sup>1</sup>

Microscopically, fibrous pseudotumours exhibit fibroblastic and myofibroblastic proliferation of cells within a hyalinized collagenous stroma. Mixed inflammatory cell infiltrates, granulation-like tissue, calcification, ossification, and myxoid change may be seen. Some postulate that fibrous pseudotumours represent the "burnt-out" end of a spectrum of reactive lesions, the opposite end of which would be a lesion largely composed of granulation-like tissue or cellular, fasciitis-like tissue.<sup>3,5,6</sup>

Although fibrous pseudotumours of the testicular tunics are accepted as reactive lesions, their pathogenesis is not well understood. They are often associated with a hydrocoele, trauma, or an infection or inflammatory process; however, it is still unclear if they actually initiate this fibrous proliferation. Some suggest that lymphatic obstruction have a role in the development of these lesions.<sup>2</sup> The cell of origin for fibrous pseudotumours appears to be the fibroblast or myofibroblast as suggested by immunohistochemical studies performed.<sup>3,8</sup>

The differential diagnosis for a fibrous pseudotumour of the testicular tunics includes leiomyoma, fibroma of the tunics, and idiopathic fibromatosis. Morphologic appearances of these lesions, the presence or absence of an infiltrative border, and ancillary studies can distinguish them in most instances. As in our case, the diagnosis in most cases was established after a radical orchidectomy, owing to clinical resemblance to malignant testicular lesion, although sometimes preservation of the testicle was possible with the nodular form of the disease.<sup>8</sup>

In summary, we describe another case of a rare testicular lesion, a fibromatous periorchitis/diffuse fibrous pseudotumour

that most often has a nodular growth pattern. An identical case has been reported previously in the English literature.<sup>3</sup> Fibrous pseudotumours are within the spectrum of benign paratesticular lesions and should be considered in the differential diagnosis when one encounters a predominantly fibrocollagenous lesion.

## Conclusion

Fibromatous periorchitis is a distinctly uncommon presumably reactive lesion, with in a broad category of fibrous pseudotumours, clinically simulating malignancy of paratesticular or testicular origin. Radical orchiectomy may be necessary because of difficulty in removing the lesional tissue while preserving the testis. This lesion should be considered in the differential diagnosis when one encounters a lesion with predominantly fibrocollagenous stroma.

## References

1. Ulbright TM, Amin MB, Young RH. Tumors of the Testis, Adnexa, Spermatic Cord, and Scrotum. Atlas of Tumor Pathology. 3rd series. Fascicle 25. Edited by Juan Rosai: Washington, DC: Armed Forces Institute of Pathology; 1999: 317-9.
2. Mostofi FK, Price EB. Tumors of the Male Genital System. In Atlas of Tumor Pathology. 2nd series. Fascicle 8. Edited by Harlan I.Firminger: Washington, DC: Armed Forces Institute of Pathology, 1973:151-4
3. Seethala RR, Tirkes AT, Weinstein S, Tomaszewski JE, Malkowicz SB, Genega EM. Diffuse fibrous pseudotumor of the testicular tunics associated with an inflamed hydrocele. Arch Pathol Lab Med 2003, 127:742-4.
4. Parveen T, Fleischmann J, Petrelli M. Benign fibrous tumor of the tunica vaginalis testis. Report of a case with light, electron microscopic, and immunocytochemical study, and review of the literature. Arch Pathol Lab Med. 1992, 116:277-80.
5. Jones MA, Young RH, Scully RE. Benign fibromatous tumors of testis and paratesticular region: a report of 9 cases with a proposed classification of fibromatous tumors and tumor-like lesions. Am J Surg Pathol 1997, 21:296-305.
6. Oliva E, Young RH. Paratesticular tumor-like lesions. Semin Diagn Pathol 2000; 17: 340-58.
7. Tobias-Machado M, Correa Lopes Neto A, Heloisa Simardi L, Borrelli M, Wroclawski ER. Fibrous pseudotumor of tunica vaginalis and epididymis. Urology 2000; 56 :670-2.
8. Sonmez K, Turkyilmaz Z, Boyacioglu M, Edal? N, Ozen O, Basaklar AC, et al. Diffuse fibrous proliferation of tunica vaginalis associated with testicular infarction: a case report. J Pediatr Surg. 2001, 36:1057-8.