

Adult Unilateral Supraglottitis as a consequence of Acute Submandibular Sialadenitis

Latifi Asrar Ahmed,¹ Syed Shahid Raza,² Naved Alam Ferooqui³

Department of ENT,^{1,2} Department of Radiology,³ Buraidah Central Hospital, Buraidah, Al Qassim, KSA.

Abstract

Acute Submandibular sialadenitis (ASS) may spread to sublingual and submandibular spaces. On rare occasions it can spread along the floor of the mouth, to the base of the tongue and to the pre epiglottic space, valleculae and epiglottis, leading to supraglottitis. Adult supraglottitis is an acute inflammation of the supraglottic structures. Unilateral supraglottitis in an adult as a consequence of ASS is a unique complication as described in this case report. Sore throat with severe odynophagia and tachycardia were the early warning signs. Early suspicion, prompt airway management, antibiotics, proper rehydration and analgesics are the mainstay of treatment.

Introduction

Adult Supraglottitis is an uncommon but potentially life threatening inflammation of the supraglottic region.¹ Rarely infection from the sublingual and submandibular spaces may spread along the floor of the mouth, to the base of the tongue and inferiorly to the pre-epiglottic space, valleculae and epiglottis leading to supraglottitis.^{2,3} ASS leading to unilateral supraglottitis in an adult is a unique complication. This life threatening condition may result in complete upper airway obstruction and sudden death. Early suspicion and proper evaluation is mandatory to prevent emergency airway crisis. Emergency physicians should be aware of the varied ways in which adult supraglottitis can present and always maintain a high index of suspicion.

Case Report

A 25 year old Egyptian man presented to our Emergency Department with severe sorethroat, dysphagia and odynophagia and swelling in the submandibular region for the past 3 days. He had been taking treatment but there was no relief. His symptoms worsened with increased severe dysphagia for liquids and mild respiratory discomfort. The patient was admitted with an impression of acute tonsillopharyngitis. He complained of mild respiratory distress, mild trismus and severe odynophagia. On examination there was a tense right sided submandibular swelling with cellulitis extending down to the thyroid cartilage. He was mildly febrile and had a pulse rate of 100/min. BP was normal with respiratory rate of 25/min. His oxygen saturation was 98% on air. Examination of the throat was difficult because of trismus. A tender swelling on the right posterior side of the tongue was noted. The patient was managed in a high-dependency unit. An urgent x-ray lateral soft tissue neck was done. X-ray revealed thickening of the epiglottis and widening of the vallecular space. (Fig: 1) With a primary diagnosis of supraglottitis with submandibular lymphadenitis, the patient was aggressively treated with Injection Ceftriaxone, Metrogyl, hydrocortisone, analgesics and intravenous fluids. A standing order for immediate intubation in the event of respiratory distress was given.

Blood tests showed leucocytosis with normal haemoglobin. Blood chemistry was normal. Throat swab was negative. A CT scan done on the 2nd day after

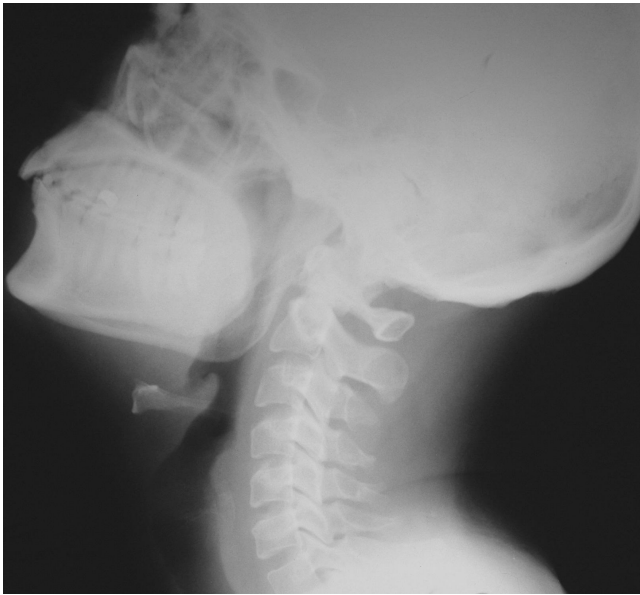

Figure-1: Lateral soft tissue radiograph of the neck shows soft tissue shadow at the base of the tongue obliterating the vallecular space and also a thickened epiglottis.

stabilization showed swelling in the right vallecula extending to the epiglottis and right ary-epiglottic fold. There was also a swelling in the right submandibular gland which enhanced on contrast CT (Fig: 2-3). A submandibular lymph node swelling was noted. On the same day after the CT, patient complained of purulent discharge from the oral cavity. On examination frank pus poured out from the right submandibular duct. The culture report of the discharge was

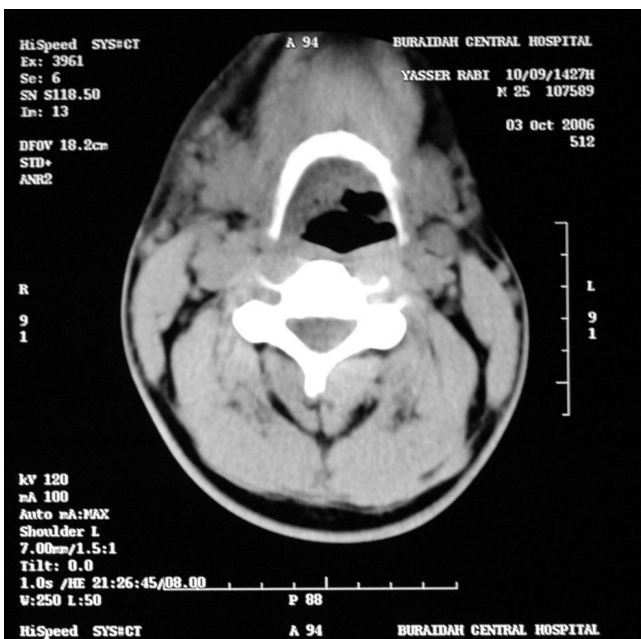

Figure-2: Axial CT Scan of the neck shows edematous tissue in the right vallecular region extending to the epiglottis, and a soft tissue shadow in the submandibular region.

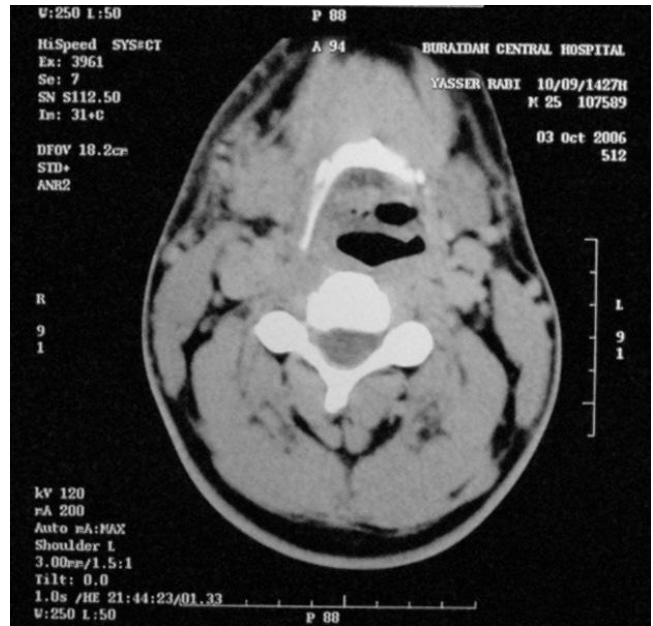


Figure-3: Axial contrast CT scan shows enhancement of the right vallecular region with some air shadow. Right Submandibular gland is also enhanced due to inflammation.

negative. The opening of the duct was inflamed but there was no swelling of the floor of the mouth. Massage of the submandibular gland from outside was advised.

On the 3rd day he improved with marked decrease in the swelling of the neck and the tongue. Trismus also improved. He had no respiratory problems. His voice remained muffled. At this stage examination of the oral cavity was possible. Which revealed mildly congested oropharynx. Indirect laryngoscopy showed mild congestion of the vallecula and thickened epiglottis. Vocal cords were normal. There was mild oedema of

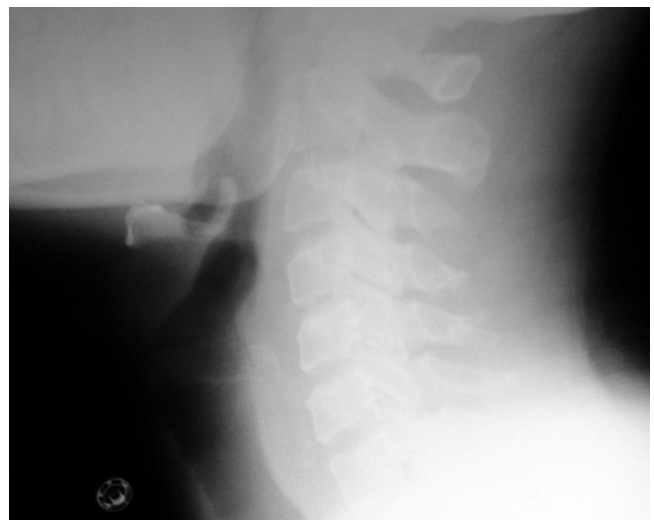

Figure-4: Lateral soft tissue radiograph of the neck after treatment shows the normal epiglottis and vallecular space.

the right aryepiglottic fold. Bimanual examination of the floor of the mouth did not reveal any calculi in the duct or the gland, but was tender on palpation. The posterior tongue on the right side was still oedematous and tender.

On the 4th day of admission, his general condition improved; mild dysphagia and a small swelling in the submandibular region persisted. On the 5th day X-ray of the lateral soft tissue neck was repeated which showed a normal epiglottis with normal vallecular space. (Fig: 3 & 4) Antibiotic and anti-inflammatory drugs were given the time of discharge. Patient was advised excision of the gland in case of recurrence.

Discussion

ASS may affect any of the major salivary glands. Acute bacterial/suppurative submandibular sialadenitis most often occurs in the setting of an obstructed Wharton's duct. Obstruction causes stasis and inspissation of secretions leading to secondary opportunistic bacterial infection. This gives rise to pain, swelling and tenderness of the affected gland. There is considerable degree of spread of infection backwards in the vallecular and pre-epiglottic space causing oedema of the glottis and may cause asphyxia if the infection is not controlled.² The tongue is progressively pushed upwards and backwards due to cellulitis. The infection may extend beyond the posterior tongue leading to oedema of the vallecular space and the epiglottis causing supraglottitis. The inflammation extends by continuity rather than by lymphatics. The lateral view of soft tissue neck and CT scans correlated well with the findings on physical examination.

Supraglottitis,¹ is a potentially life threatening infection. Infection, thermal, caustic injuries, trauma and foreign bodies are the main insults causing supraglottitis.⁴⁻⁶ Our case of unilateral supraglottitis was caused by inflammatory process secondary to acute suppurative submandibular sialadenitis.

A variety of microorganisms are considered as etiological factors in supraglottitis and sialadenitis.^{1,7} In our case the culture was negative probably due to previous antibiotic therapy.

Early recognition of complications of ASS is of paramount importance. Indurated neck swelling, severe dysphagia, swelling of the tongue and respiratory discomfort should suggest an impending complication. If the infection travels forwards it may lead to Ludwig's angina.^{2,8} Whereas posterior spread may lead to epiglottitis and supraglottic oedema — a very rare complication. Airway management is the primary therapeutic concern. Treatment plans should be individualized based on a number of factors. The stage of disease, co-morbidity,

physician experience, available resources, are all critical factors in decision making. Conservative airway management may help in selected cases of lesser severity.

Corticosteroids are often given on the assumption of their anti-inflammatory effect to reduce oedema and cellulitis. They also provide the initial chemical decompression protecting the airway and allow improved antibiotic penetration in to the inflamed area.⁷⁻⁹ High doses of third generation cephalosporins with metronidazole are all good initial agents to control infection. Non steroidal anti-inflammatory drugs are given to reduce pain and inflammation. The patient must be placed in a semi sitting position and should never be left unattended. In addition to adequate hydration, sialogogues and warm fomentation are given to decrease the swelling in the submandibular gland.

CT scan and MRI delineate the extent of swelling in the supraglottic region including the complication in the surrounding areas. They also help to rule out calculi in the salivary glands. CT is also done to confirm the diagnosis when an adequate laryngoscopic examination cannot be performed.¹⁰

Unilateral supraglottitis was secondary to acute suppurative submandibular sialadenitis in our case; it was confirmed by CT scan, plain lateral soft tissue neck x-ray, and purulent discharge from the Wharton's duct. A review of literature did not find acute supraglottitis as a complication of acute submandibular sialadenitis. Patients complaining of severe sore throat with or without neck swelling should be seen by an otolaryngologist. This may enable them to detect milder cases of epiglottitis that might otherwise be ignored. One should always be aware of possible supraglottic complications when presented with a patient with ASS especially when Ludwig's angina is ruled out.

References

1. Shapiro J, Eavey RD, Baker AS. Adult supraglottitis: A prospective analysis JAMA 1988; 259: 563-7.
2. Harrold Ellis. The tongue and floor of mouth in Clinical Anatomy. 8th ed. Oxford: Blackwell Scientific Publication, 1992.
3. Huehns TY, Yentis SM, Cumberworth V. Apparent massive tongue swelling. A complication of orotracheal intubation on the intensive care unit. Anaesthesia 1994; 49: 414-6.
4. Mcqueen CT, Yarbrough WG, Witsell DL, Holmes DK, Shockley WW. Unilateral supraglottitis in adults: facts or fiction. J Otolaryngol 1995; 24: 255-7.
5. Asrar L, Oyetunji N, Roza SS, Zeyalhaque I. Foreign body in the vallecula presenting as acute epiglottitis with unilateral supraglottitis. Saudi Med J 2005; 26: 1449-52.
6. Kornak JM, Freije JE, Cambell BH. Caustic and thermal epiglottitis in the adult. Otolaryngol Head Neck Surg 1996; 114: 310-2.
7. Tveteras K, Kristensen S. Acute epiglottitis in adults: Bacteriology and therapeutic principles. Clin Otolaryngol Allied Sci 1987; 12: 337-43.
8. Bush RF, Shaha D. Ludwig's angina improved treatment. Otolaryngol Head Neck Surg 1997; 117: S 172-5.
9. Freud B, Timon C. Ludwig's angina: a place for steroid therapy in its management. Oral Health 1992; 82: 23-5.
10. Smith MM, Mukherji SK, Thompson JE, Castillo M. CT in adult supraglottitis. Am J Neuroradiol 1996; 17: 1355-8.