

Castleman's disease of the duodenum

Emre Ergul, Birol Korukluoglu, Samet Yalcin, Yigit Mehmet Ozgun, Ahmet Kusdemir
General Surgery Department, Ankara Atatürk Teaching and Research Hospital, Ankara, Turkey.

Abstract

Castleman's disease is a rare lymphoproliferative disorder of uncertain origin. Just two cases of Castleman's disease of the gastrointestinal tract have been reported. These were found in the stomach. However, as far as we know, Castleman's disease of the duodenum has not been reported. This is the first report of hyaline vascular subtype of Castleman's disease at the duodenum.

Introduction

Castleman's disease, or angiofollicular lymphoid hyperplasia, or angiomatous lymphoid hamartoma is a

rare lymphoproliferative disorder of uncertain origin, which was first described in 1956.¹ The pathologic characteristic of this disease is hyperplasia of the lymph follicle, multiple blood vessel penetration, and infiltration of plasma cells in the interfollicular area. In 1972, Keller et al.² named this disease as Castleman's disease and divided into two types: hyaline vascular (HV) type, and plasma cell (PC) type, and this classification is still used.

To our knowledge, only two cases of Castleman's disease of the gastrointestinal tract have been reported and both were in the stomach^{3,4} and no case of duodenal disease has been reported. We report a rare form of this disease with

a literature review.

Case Report

A 49-year-old woman presented with vague abdominal discomfort and nausea for four years. Physical examination was unremarkable, laboratory data and X-rays were within the normal limits. Abdominal ultrasound showed a well-defined, 4x5 cm mass at the tail of the pancreas which was verified in the CT scan lying in the 4th segment of the duodenum (Figure-1).

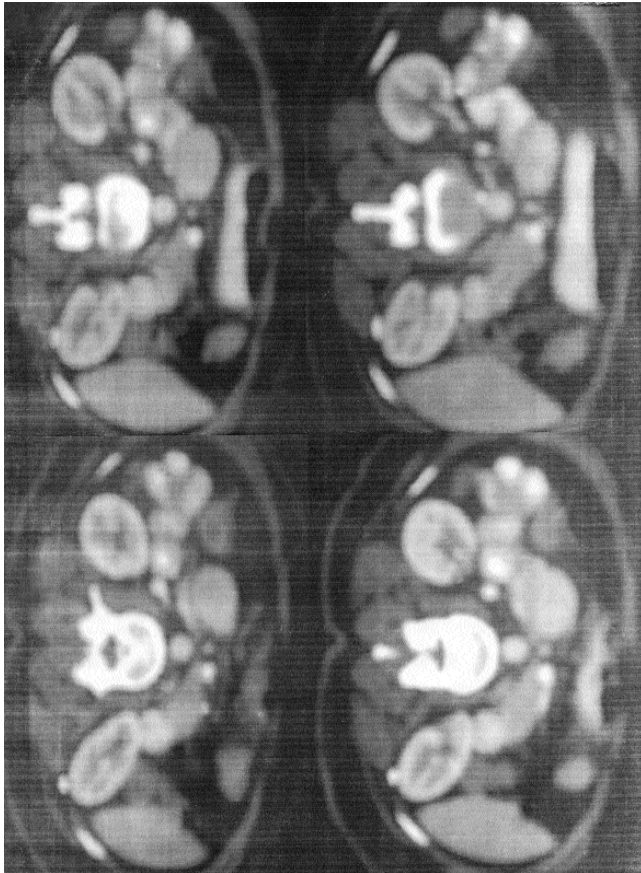


Figure-1: Oral and IV contrasted CT scan. A solid mass with homogeneous contrast enhancement at the duodenal wall.

Upper gastrointestinal system endoscopy was normal as only 2nd part of duodenum could be seen with the scope.

The patient therefore underwent laparotomy. A 4.2 x 4 x 5.5cm tumour was found in the 4th segment of the duodenum (Figure-2) but no intra-abdominal lymphadenopathy or any visceral abnormality was seen. The tumour was dissected from duodenum and duodenum repaired by one layer single sutures. Postoperative recovery was uneventful and patient was discharged on 7th postoperative day.

Histopathological examination of the specimen showed small distinct vascular follicles surrounded by

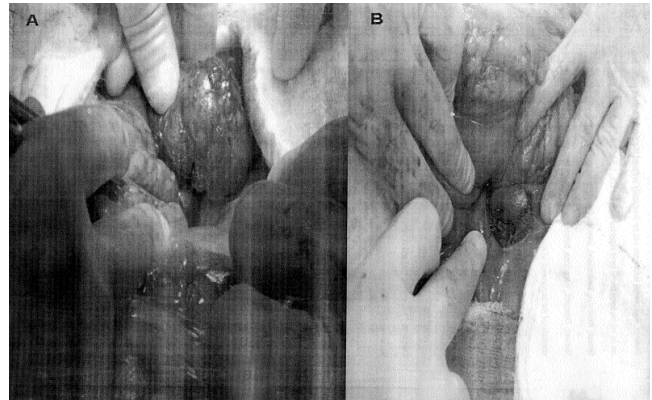


Figure-2: A- Picture of the mass before resection. B- Picture of duodenum after resection of the mass, just before the serosal repair.

palisading layers of small lymphocytes with radially arranged capillaries consistent with the diagnosis of HV variant of Castleman's disease.

Six months after surgery the patient is fine with no relapse.

Discussion

Castleman's disease is characterized by cancerous growth in the lymph node tissue throughout the body. Most often the mediastinal lymph nodes are affected. There are two main types of Castleman's disease i.e. HV type and PC type, HV type accounts for approximately 90% of the cases. Most patients with HV type are asymptomatic and have a solitary lesion. Treatment is surgical resection of the primary lesion and the recurrence rate is low when the resection is complete. PC type frequently occurs in multicentric fashion and is associated with symptoms, like fever, splenomegaly, and leukocytosis. Some cases of PC type transform to malignant lymphoma and Kaposi's sarcoma (KS). Lymphoma and KS occur during the course of multicentric Castleman's disease in 18 and 13 percent of cases, respectively.^{5,6}

Though definitive diagnosis necessitates histological analysis, radiological features may be helpful. HV lesions often demonstrate fine calcification that is evident even on plain X-rays, but our patient had a normal roentgenogram. On CT or magnetic resonance imaging, lymphoid lesions, which are involved, typically demonstrate homogeneous contrast enhancement, as was seen in our case and this distinguishes Castleman's disease from other masses such as thymomas or lymphomas, which generally show no enhancement on CT scan.⁷

The most common site of involvement of hyaline vascular-type Castleman's disease is the mediastinum,² but any lymph node site can be involved⁸ and there are reports of this disease in the porta hepatis and hepatoduodenal

ligament.⁸⁻¹⁰ Complete surgical excision is virtually curative in all cases reported so far however, local recurrence has been observed after subtotal or partial resection.

References

1. Castleman B, Iverson L, Menendez VP. Localized mediastinal lymph node hyperplasia resembling thymoma. *Cancer* 1956; 9: 822-30.
2. Keller AR, Hochholzer L, Castleman B. Hyaline-vascular and plasma-cell types of giant lymph node hyperplasia of the mediastinum and other locations. *Cancer* 1972; 29: 670-83
3. Hata T, Ikeda M, Ikenaga M, Yasui M, Shingai T, Yamamoto H, et al. Castleman's disease of the rectum: report of a case. *Dis Colon Rectum* 2007; 50:389-94.
4. Yebra M, Vargaz JA, Menendez MJ, Cabrera JR, Diaz F, Diego FJ, Durantez A. Gastric Castleman's disease with a lupus-like circulating anticoagulant. *Am J Gastroenterol* 1989; 84:566-70.
5. Soulier J, Grollet L, Oksenhendler E, Cacoub P, Cazals-Hatem D, et al. Kaposi's sarcoma-associated herpes virus-like DNA sequences in multicentric Castleman's disease. *Blood* 1995; 86:1276-80.
6. Peterson BA, Frizzera G. Multicentric Castleman's disease. *Semin Oncol* 1993; 20: 636-47.
7. Ferreiros J, Gomez Leon N, Mata MI, Casanova R, Pedrosa CS, Cuevas A. Computed tomography in abdominal Castleman's disease. *J Comput Assist Tomogr* 1989; 13:433-6.
8. Peck D, Lum PA. Castleman disease in the porta hepatis: biphasic helical computed tomography. *Can Assoc Radiol J* 1996; 47: 410-2.
9. Cirillo RL Jr, Vitellas KM, Deyoung BR, Bennett WF. Castleman disease mimicking a hepatic neoplasm. *Clin Imaging* 1998; 22: 124-9.
10. Sato N, Kondo S, Saito K, Hirano S, Hara T, Tanaka E, et al. Hyaline vascular-type Castleman's disease in the hepatoduodenal ligament: report of a case. *Surg Today* 2006; 36:647-50.