

Treatment of Ureteric Calculi - Use of Holmium: YAG Laser Lithotripsy versus Pneumatic Lithoclast

Salman Ahmed Tipu, Hammad Afzal Malik, Nazim Mohhayuddin, Gauhar Sultan, Manzoor Hussain, Altaf Hashmi, Syed Ali Anwar Naqvi, Syed Adibul Hasan Rizvi
Sindh Institute of Urology and Transplantation (SIUT), Karachi.

Abstract

Objective: To compare the efficacy of Holmium: YAG laser and pneumatic lithoclast in treating ureteric calculi.

Methods: The study included total of 100 patients divided into two equal groups of laser lithotripsy (LL) and pneumatic lithoclast (PL). Study was conducted between September 2006 and February 2007. Inclusion criteria were patients with a ureteric stone of size 1-2 cm and negative urine culture. An x-ray KUB was mandatory. IVU and CT pyelogram were also done when required. Procedures were done under general anaesthesia after a single dose of pre-operative antibiotic. A 7.5 Fr semi rigid ureteroscope was used for ureteroscopy in all cases. Holmium: YAG laser with 365 µm wide probe was employed in laser group and frequency was set between 5 and 10 Hz at a power of 10 to 15 W. Swiss lithoclast with single or multiple fire technique was used accordingly in PL group. Postoperatively patients underwent radiography and helical CT as required at 4th week of follow up to assess stone clearance.

Results: The mean patient age in LL and PL group was 38 ± 10 and 40 ± 10 years respectively. The male to female ratio and stone size were similar between the groups. Stone migration up in pelvicalyceal system occurred in two patients of LL group while in eight patients of PL group. JJ Stent was placed in 5(10%) patients in laser group where as 13(26%) patients required it in pneumatic lithoclast group. Stone free rate at 4 weeks was 92% in laser group as compared to 82% in pneumatic lithoclast group. Hospital stay was more than 24 hours in 2 patients of laser group as compared to 5 patients of pneumatic lithoclast group. Complication rate was 4% in LL group whereas it was 14% in PL group.

Conclusion: Holmium: YAG laser lithotripsy is a superior technology compared to pneumatic lithoclast in terms of rate of stone clearance and complications, especially in upper ureteric stones (JPMA 57:440:2007).

Introduction

Urolithiasis is a health problem of worldwide importance. Pakistan falls into Afro-Asian stone belt stretching from Egypt, Iran, India, Thailand to Indonesia. A variety of treatment options are available for ureteric calculi but there is increasing trend towards minimal invasive surgery. With the advent of and continuous refinements in minimally invasive techniques, open surgery is becoming a procedure of the past. The introduction of Extracorporeal Shock Wave Lithotripsy (ESWL) in 1980 has revolutionized the treatment of both renal and ureteric calculi.¹ In context of ureteric calculi, the combination of ureteroscopy and intra corporeal lithotripsy has proven to be a viable alternative to ESWL.² The different modalities of intra corporeal lithotripsy are lasers, pneumatic lithoclast, electro hydraulic lithoclast (EHL) and ultrasonic lithoclast.

The Holmium: Yttrium, Aluminum, Garnet laser was developed in early 1990s. It was discovered as early as 1993 that the holmium: YAG was effective in fragmenting stones under lab conditions.³ Further clinical studies in both children and adults have shown holmium: YAG laser

to be effective in the treatment of ureteric calculi in vivo as well.⁴⁻⁶ The holmium: YAG is a pulsed source that can work with frequencies of up to 50 Hz and can be used with very fine fibers of up to 200µm. Its growing success is a result of its excellent performance as both a lithotripter and a surgical laser. It can vaporize as well as coagulate the tissues. It has a wide range of endoscopic applications, and has demonstrated effectiveness in clearing stones of all compositions.⁷ The holmium: YAG laser is transmittable via flexible fibers. The thermal effect produced by holmium: YAG laser's pulses are due to formation of plasma bubble.⁸ This bubble at the tip of the fiber connected to the holmium: YAG laser makes it possible to work on stones and soft tissues. Intra corporeal lithotripsy with ballistic pneumatic device (Swiss lithoclast) is also an effective and safe technique.⁹ The Swiss lithoclast developed in Lausanne, Switzerland, fragments the stones by oscillatory movements of metal probe against the stones like the jack hammer.¹⁰

Holmium:YAG laser is a budding modality for treatment of urinary stones in Pakistan and this study would

be an effort to introduce modern methods for combating heavy burden of Urolithiasis in this part of the world. Aim of this study is to compare the efficacy of holmium: YAG laser and pneumatic lithoclast in treating ureteric calculi.

Patients and Methods

This comparative cross sectional study was carried out in the Urology department of Sindh Institute of Urology and Transplantation (SIUT) Karachi between September 2006 and February 2007. One hundred patients were selected after informed consent in stone clinic of SIUT. Patients with single stone of size 1-2 cm were selected. Patients with co-morbidities like diabetes mellitus, hypertension, and renal failure were excluded from the study. All the patients underwent thorough process of history, examination, and investigations. The treatment modality chosen for an individual was primarily based on patient choice after the patient was informed of the available therapeutic options, and the risks and benefits associated with each treatment modality. Two groups of 50 each were made, the laser lithotripsy (LL) group and pneumatic lithotripsy (PL) group. Negative urine cultures were mandatory in every patient of both groups. All patients received a single shot of pre-operative antibiotic. General Anaesthesia was employed in all patients. Ureteroscopy combined with either holmium: YAG laser or pneumatic lithotripsy was performed by a single Urologist using a 7.5 Fr semi rigid ureteroscope. The patient was placed in lithotomy position. The standard technique employed for ureteroscopic treatment of ureteric calculi included cystoscopy with placement of a 0.038-inch floppy tip guide wire past the stone (glide wire when necessary) to maintain access and then ureteroscope negotiation. Continuous irrigation with ureteromate and/or intermittent manual pumping of irrigant was done to maintain a clear ureteroscopic view when appropriate. For ureteroscopic laser lithotripsy a Hol: YAG laser which operates at a wavelength of 2100 nm was used. Frequency was usually set between 5 and 10 Hz at a power of 10 to 15 W. Higher settings were required to treat harder calculi. The majority of the patients were treated with a 365 m quartz fiber. Swiss lithoclast with 1mm probe was used to break the stones in PL group. Stones were fragmented by using single or multiple fire technique at a single sitting. Stents were used accordingly.

Preoperatively, a kidney-ureter-bladder radiograph was done in all cases. Excretory urography, noncontrast helical computerized tomography or ultrasound was done when indicated to document stone size and location. Postoperatively patients underwent radiography for X-ray KUB and helical CT as required at 4th week of follow up. Treatment outcomes were defined as complete

disappearance of the stones. Statistical comparison of two independent percentages was done and p value of 0.05 considered statistically significant.

Results

Average patient age, the male to female ratio and stone size were similar between the groups (Table 1). Mean operative time in LL group was 39.6 ± 11.9 minutes (18-80 min), as compared to 37.2 ± 13.0 minutes (15-79 min) in PL group ($p < 0.07$). The mean stone size was 1.6 ± 0.2 cm in LL and 1.5 ± 0.2 in PL group with a range of 1 to 2 cm ($p < 0.08$). As far as location is concerned, we divided the ureter into proximal, mid and distal portions as per standard anatomical landmarks. In LL group 22 (42%) stones were located in proximal ureter, 9 (18%) in mid ureter and 19 (38%) in distal ureter while 17 (34%) were in proximal part of ureter, 12 (24%) in mid ureter and 21 (42%) in distal ureter in PL group. Only 2 (4%) patients required re-treatment or any ancillary procedure in LL as compared to 7 (14%) patients who required more than one session in PL. In two patients treated with laser, we came across stone migration up in the pelvicalyceal system. One of them was treated with conservative measures as it was partially fragmented to small pieces, while the other required ESWL. On the other hand stone migration occurred in eight patients in PL group. One of them later passed spontaneously but the other 7 required ancillary procedures. So the stone migration rate was 16% ($p < 0.05$) in PL group. We were not very generous in the use of JJ stent. In LL group, 5 (10%) required JJ stenting and 13 (26%) were subjected to JJ stenting in PL group ($p = 0.03$). It was essentially a day care procedure in both groups. Only 2 patients required more than 24 hours hospital stay in LL group, whereas 5 patients stayed more than 24 hours in PL group. Stone clearance was better in LL as compared to PL not only in breakup of three sites of ureter but also in aggregate (Table 2). In LL group stone clearance rate in proximal ureter is 90.9%, in mid ureter 93.7% and in distal ureter 91.3% with overall rate of

Table 1. Mean, age, male to female ratio and mean stone size.

Variable	LL Group	PL Group	P-Value
Mean Age (yrs)	38.4 ± 13.7	40.7 ± 14.7	0.41
Sex Ratio	M : F	M : F	
	1.9 : 1	1.4 : 1	0.4
Mean Stone Size (cm)	1.6 ± 0.2	1.5 ± 0.3	0.06

Table 2. Stone clearance rate.

Location	LL	PL	P-Value
Proximal ureter	90.9%	71.4 %	
Mid ureter	93.7%	86.6%	
Distal ureter	91.3%	89.2%	
Overall rate	92%	82%	<0.05

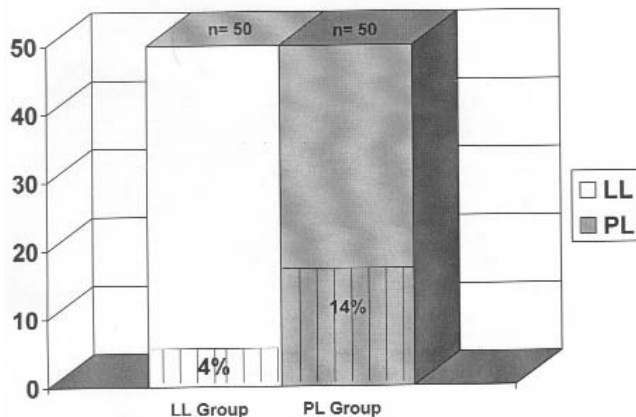


Figure 1. Complication Rate

92%. Similarly stone clearance in PL group is 71.4%, 86.6%, and 89.2% respectively with an overall rate of 82%. There was not a single case of ureteric injury in both groups. However one patient suffered haematuria and one had fever in LL group. Three patients encountered haematuria and four patients had fever in PL group (Figure 1). The indwelling ureteral stents placed in patients of both groups were removed after four weeks.

Discussion

The miniaturization of ureteroscopes and improved intra corporeal lithotripsy technology has made it possible to successfully access and treat virtually any stone within the ureter in a relatively atraumatic fashion. The holmium: YAG laser is a solid state system which can be used to fragment stones of all composition¹¹, with a fragmentation rate of 90-100%. In our study this rate is 92%. Stones can be fragmented with a power setting of 10 W, and we used a similar power.¹² This laser energy was effective for ureteroscopic procedures, such that all stones were fragmented completely. An important point of technique is that the tip must be 1 mm away from the urothelium or the guide wire during activation of the laser pulses, as the depth of thermal injury is 0.5-1 mm. Laser lithotripsy has significant advantages over the other lithotripsy techniques.¹³ It has a local effect on stone, and this prevents proximal migration. The probes for laser lithotripters are more suitable for smaller caliber instruments. The only disadvantage of this energy source seems to be the cost of the device and probes. It can be decreased by using a probe several times, after re-sterilization.

The Swiss lithoclast was developed in Switzerland in 1989 and clinical results of its use in fragmenting urinary stones were published in the early 1990s.¹⁴ Our results show that this modality is also an effective way of fragmenting

stones. We have achieved an overall stone clearance rate of 82% at 4 weeks, which is comparable to international published data. The disadvantage being stone migration up, because of jack hammer mechanism of lithoclast probe.¹⁵ In majority of cases we have applied energy in single pulse as we observed that these were more powerful in breaking stones but on the contrary were more helpful in preventing the stones from going upwards into the kidney. Most of the migrations occurred in proximal ureteric stones. We also tried elevated head end of the table to prevent stone migration but we avoided the use of baskets and ureteric occlusion balloons due to the risk of ureteric mucosal injury. Mohammad et al¹⁶ used lidocain jelly for preventing stone displacement during pneumatic lithotripsy for ureteral calculi. Overall complication rate was a bit higher in PL as compared to LL.¹⁷ According to O H Peh et al holmium: YAG laser lithotripsy is both effective and safe.¹⁸ In another study conducted by James D et al holmium: YAG laser is even safer in patients with bleeding diathesis.¹⁹ A comparison of holmium: YAG laser with pneumatic lithotripsy in ureteral calculi fragmentation was done by Seong Soo Jeon et al²⁰ in Korea in 2005. This study revealed that laser is better than lithoclast in terms of stone free rates as well complication rates. Our study also gave similar results. A prospective randomized controlled trial comparing nonstented versus stented ureteroscopic lithotripsy by John D et al²¹ had given the observation that routine stenting after ureteroscopic intra corporeal lithotripsy with the holmium laser is not required as long as the procedure is uncomplicated. We also used stents only, when required.

Conclusion

Holmium: YAG laser lithotripsy is a superior technology than pneumatic lithoclast in terms of rate of stone clearance and complications, especially in upper ureteric stones. Since this is a single centre study, a multi centre study at a larger scale is required.

References

1. Chaussy C, Schuler J, Schmiedt E, Brandl H, Jocham D, Liedl B. Extracorporeal Shock Wave Lithotripsy (ESWL) for treatment of Urolithiasis. *Urology* 1984; 23: 59-66.
2. Segura JW, Preminger GM, Assimos DG, Dretler SP, Kohn RI, et al. Ureteral stones clinical guidelines panel summary report on the management of ureteral calculi. *J Urol* 1997; 158: 1915-21.
3. Sayer J, Johnson DE, Price RE, Cromeen DM. Ureteral lithotripsy with Holmium:YAG Laser. *J Clin Laser Med Surg* 1993; 11:61-5.
4. Wollin TA, Teichman JMH, Rogenes VJ, Razvi HA, Denstedt JD, Grasso M. Holmium:YAG lithotripsy in children. *J Urol* 1999; 162:1717-20.
5. Shroff S, Watson GM, Parikh A, Thomas R, Soonawalla PF, Pope A. The Holmium:YAG laser for ureteric stones. *Br J Urol* 1996; 78: 836-9.
6. Devarajan R, Ashraf M, Beck RO, Lemberger RJ, Taylor MC. Holmium:YAG lasertripsy for ureteric calculi; an experience of 300 procedures. *Br J Urol* 1998; 82: 342-7.

7. Yiu MK, Liu PL, Yiu TF, Chan AY. Clinical experience with Holmium:YAG laser lithotripsy of ureteric calculi. *Lasers Surg. Med.* 1996; 19: 103-6.
 8. Cecchetti W, Zattoni F, Nigro F, Tasca A. Plasma bubble formation induced by Hol: yag laser: An in-vitro study. *Urology* 2004; 63: 586-90.
 9. Naqvi AA, Khaliq M, Zafar MN, Rizvi SAH. Pneumatic lithotripsy: a new modality for treatment of ureteric stones. *J Pak Med Assoc* 1995; 45: 9-11.
 10. Denstedt JD, Razvi HA, Rowe E, Grignon DJ, Eberwein PM. Investigation of tissue effects of a new device for intra corporeal shock wave lithotripsy the Swiss lithoclast. *J Urol* 1995; 153: 535-7.
 11. Zheng W, Denstedt JD: Intra corporeal lithotripsy: update on technology. *Urol Clin North Am* 2000; 27: 301-13.
 12. Kourambas J, Delvecchio FC, Preminger GM. Low-power holmium laser for the management of urinary tract calculi, strictures and tumors. *J Endourol* 2001; 15: 529-32.
 13. Dogan HS, Tekgul S, Akdogan B, Keskin MS, Sahin A. Use of Hol:YAG laser for ureterolithotripsy in children. *Brit J Urol* 2004; 94: 131-3.
 14. Lanquetin JM, Jichlinski P, Favre R, Von Niederhusern W. The Swiss Lithoclast. *J Urol* 1990 part 2; 143: 179A, abstract V-032.
 15. Schock J, Barsky RI, Pietras JR: Urolithiasis update: Clinical experience with the swiss lithoclast. *J Am Osteopath Assoc* 2000; 101 : 437-40.
 16. Mohseni MG, Arasteh S, Alizadeh F. Preventing retrograde stone displacement during pneumatic lithotripsy for ureteral calculi using lidocain jelly. *Urology* 2006; 68: 505-7.
 17. Kamran T. Pneumatic lithotripsy for the management of ureteric calculi. *JCPSP* 2003; 13: 101-3.
 18. Peh OH, Lim PHC, Ng FC, Chin CM, Queck P, Ho SH. Holmium laser lithotripsy in the management of ureteric calculi. *Ann Acad Med Singapore* 2001; 30: 563-7.
 19. Watterson JD, Girvan AR, Cook AJ, Beiko DT, Nott L, Auge BK et al. Safety and efficacy of Holmium:YAG laser lithotripsy in patients with bleeding diatheses. *J Urol* 2001; 168: 442-5.
 20. Seong SJ, Ji-Hwan H, Kyu SL. A comparison of holmium:YAG laser with lithoclast lithotripsy in ureteral calculi fragmentation. *Int Jr of Urol* 2005;12:544-7.
 21. Denstedt JD, Wollin TA, Sofer M, Nott L, Weir M, Honey RJ. A prospective randomized controlled trial comparing nonstented versus stented ureteroscopic lithotripsy. *J Urol* 2001; 165: 1419-22.
-