

Assessment of complications of the open treatment of mandibular condylar fractures

Muhammad Adil Asim¹, Waseem Ahmed², Muhammad Wasim Ibrahim³, Syed Gulzar Ali Bukhari⁴, Muhammad Nazir Khan⁵

Abstract

The objective of our study was to analyze the complications of open treatment of mandibular condylar fractures operated via various surgical approaches. Thirty-eight patients with 42 fracture sides having moderate to severely displaced condylar fractures were studied. Open treatment was performed, and patients were assessed for complications of open treatment in terms of facial nerve paresis, unaesthetic scar, salivary fistula/sialocele. Facial nerve paresis was noted in 13 (31%) cases, mostly transient in nature (n=9, 69.2%), that recovered within 8 weeks. Furthermore, 5 (11.9%) patients had unaesthetic scar formation, while just 1 (2.4%) case of salivary fistula was observed. Facial nerve paresis was the most common complication of open treatment of mandibular condylar fractures and most of them were observed in cases operated by preauricular approach.

Keywords: Mandibular condyle, Maxillomandibular fixation. Open reduction, Internal fixation.

DOI: <https://doi.org/10.47391/JPMA.03-499>

Introduction

Condylar fractures are the most common fractures of the mandible due to indirect facial trauma. They account for 20% to 52% of all mandibular fractures.¹ Various options are available for the treatment of mandibular condylar fractures. Conservative treatment includes, observation only protocol and is mostly indicated for un-displaced condylar fractures. The closed treatment involves close reduction of fracture followed by a period of maxillomandibular fixation while open treatment includes open reduction via extraoral or intraoral approach followed by fixation with miniplates or lag screws.² Open treatment is being increasingly favoured by many maxillofacial surgeons for moderate to severely displaced and dislocated

mandibular condylar fractures. Despite various advantages of open treatment of condylar fracture, several complications have also been documented including iatrogenic neural injuries, surgical scar, salivary fistula, plate fracture/loosening, and increased operative time.

As each surgical approach has its own advantages and limitations, there is lack of consensus regarding the ideal approach to minimize the complications of open treatment. Furthermore, there is paucity of local studies that describe the complications of open treatment particularly the facial nerve injuries. The aim of this study was to share our experience of various complications during different surgical approaches used for open treatment of mandibular condylar fractures.

Case Series

This study was carried out at Oral and Maxillofacial Surgery Department, Armed Forces Institute of Dentistry Rawalpindi, Pakistan from February 2014 to January 2017.

Approval from ethical review committee of the institute and informed consent from the patients were taken. Diagnosis of fractures was made by clinical and radiographic evaluation. Orthopantomogram was used to assess the displacement of condylar fractures while deviation was assessed by reverse townes or PA mandible radiograph. Patients who had dislocated, moderate to severely displaced (≥ 2 mm but < 15 mm of overlap) or deviated ($\geq 10^\circ$ but $< 45^\circ$ of angulation) mandibular condylar neck/subcondylar fractures were included in our study. While all patients younger than 18 years of age, those with pre-trauma trismus, having severe pre-traumatic skeletal malocclusion or facial nerve weakness were excluded from the study.

Selection of surgical approach for open reduction and internal fixation (ORIF) was made according to the level of fracture, extent of displacement/deviation of fracture and experience/personal choice of the operating surgeon. Complications of open treatment were assessed by clinical examination, initially at 1st post-operative day and later on, at 1 week, 1 month, 3 months and 6 months post operatively. Radiographic assessment was performed on 1st post-operative day (for baseline record of reduction and fixation) and later if clinical condition mandated

¹Department of Oral and Maxillofacial Surgery, Shifa College of Dentistry, Islamabad, Pakistan; ^{2,5}Department of Oral and Maxillofacial Surgery, Armed Forces Institute of Dentistry, Rawalpindi, Pakistan; ³Department of Oral and Maxillofacial Surgery, Combined Military Hospital, Malir Cantt, Karachi, Pakistan; ⁴Department of Oral and Maxillofacial Surgery, Combined Military Hospital Institute of Medical Sciences, Multan, Pakistan.

Correspondence: Muhammad Adil Asim. e-mail: adil_asim@yahoo.com

radiographic assessment.

Complications were assessed in terms of facial nerve palsy, hardware fracture/loosening, salivary fistula/sialocele and unaesthetic scar. Facial nerve function was assessed by testing the motor response of all five branches of facial nerve. Severity of facial nerve injury was assessed according to Seddon's classification by evaluating the recovery of facial nerve function in follow up period. Patient with neuropraxia, restored their facial nerve function within 3 months of operation while those with axonotmesis recovered most of the nerve function within 6 months of surgery.³ Patients who had complete nerve paralysis or negligible recovery at last follow up appointment were supposed to be having neurotmesis of facial nerve.

Data was analyzed on SPSS 17. Mean±S.D was calculated for descriptive variables like age. Frequency and percentages were calculated for categorical variables. Chi square test was applied to compare the results. P value <0.05 was considered significant.

Forty patients fulfilling the inclusion criteria were selected for the study. Two patients who were unable to comply to our follow up protocol were excluded. Out of 38 patients we studied, 29(76.3%) were males while just 9(23.7%) were females. The mean age of our study sample was 32.42±11.93 years with range of 18 to 68 years.

In our study 34(89.5%) patients had unilateral fractures while 4(10.5%) patients had bilateral condylar fractures. Therefore, a total of 42 mandibular condylar fractures/fracture sides were treated by ORIF in our study. Four types of surgical approaches were used for ORIF of condylar fractures. Preauricular approach was used in 22(52.4%) fractures, retromandibular trans-parotid approach in 14(33.3%) fractures while submandibular and intraoral approaches were used in 3(7.1%) cases each.

Out of 42 fracture sides studied, 13(31%) had facial nerve palsy post-operatively. Five (11.9%) patients described their surgical scars as unaesthetic at the 6 months follow up appointment while just one (2.4%) patient had salivary fistula of parotid gland. None of the patients operated by intraoral approach had any complaint of facial nerve palsy, unaesthetic scar or salivary fistula postoperatively. Relationship of facial nerve palsy, unaesthetic scar and salivary fistula with the various extraoral surgical approaches was further evaluated but we could not develop any statistical significance except in case of unaesthetic scar (p= 0.017). Table-1

Distribution of type of facial nerve injury with respect to

Table-1: Relationship of complications with extraoral surgical approaches.

		Surgical Approach			p-value
		Preauricular (n=22)	Retromandibular (n=14)	Submandibular (n=3)	
Facial Nerve Paresis	Yes	10 (45.5%)	2 (14.3%)	1 (33.3%)	0.154
	No	12 (55.5%)	12 (85.7%)	2 (66.7%)	
Salivary Fistula	Yes	0	1 (7.1%)	0	0.010
	No	22 (100%)	13 (92.9%)	3 (100%)	
Scar	yes	1 (4.5%)	2 (14.3%)	2 (66.7%)	0.4
	no	22 (95.5%)	12 (85.7%)	1 (33.3%)	

Table-2: Distribution of the types of facial nerve injury.

	Surgical Approach			Total
	Preauricular n (%)	Retromandibular n (%)	Submandibular n (%)	
Neuropraxia	6 (60)	2 (100)	1 (100)	9 (69.2)
Axonotmesis	2 (20)	0	0	2 (15.4)
Neurotmesis	2 (20)	0	0	2 (15.4)
Total	10 (100)	2 (100)	1 (100)	13 (100)

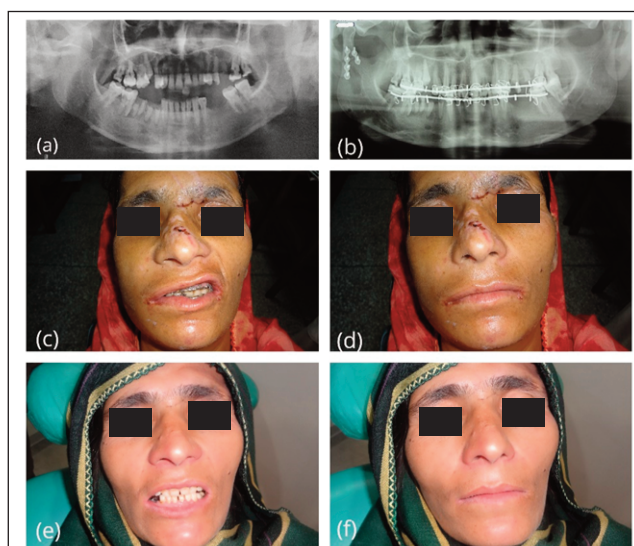


Figure: Neuropraxia of facial nerve.

(a) Pre-op OPG (b) Post-op OPG (c & d) First post-op day photographs showing facial nerve weakness (d & e) Photographs taken on 3-month post-operative follow up showing full recovery of facial nerve (permission taken from patient).

surgical approach is shown in Table-2. We observed that neuropraxia (n=9, 69.2%) was the most common type of facial nerve injury.(Figure)

Finally, none of the patients reported with hardware fracture or screw loosening.

Discussion

Facial nerve palsy is considered one of the most serious and debilitating complications of surgical treatment of condylar fractures. In our study 31% (13/42) fractured sides

had facial nerve paresis after surgical treatment. We noted a significantly high incidence of facial nerve palsy among cases operated by preauricular approach (45.5% cases) as compared to retromandibular approach (14.3% cases) which provides direct access to fracture site. Al-moraissi et.al in their meta-analysis described retromandibular anteroparotid approach as the better extraoral approach for ORIF of condylar neck and base fractures.⁴ On the other hand, excessive retraction of flap by preauricular approach, particularly during fixation of miniplate to the distal segment, results in relatively high incidence of facial nerve paresis.⁵ In various studies incidence of facial nerve paresis has been reported to be 3 to 48% by preauricular approach while it is 5 to 48% after submandibular approach.^{5,6} We did not find any facial nerve paresis in patients operated by intraoral approach. However, in a recent meta-analysis it is described that facial nerve injury after intraoral approach for ORIF of condylar fracture ranges from 0.72-4.2% and transbuccal instrumentation is stated as the main cause of facial nerve injury.⁴

Severity of facial nerve injury is directly proportional to the degree of manipulation of soft tissue flaps during surgery. Neuropraxia is most common type of injury observed due to inappropriate retraction of tissues. Whereas excessive traction of tissues results in increased postoperative oedema which may lead to neural ischaemia and ultimately axonal damage (axonotmesis).⁵ Furthermore, excessive ischaemia or direct damage to any branch of facial nerve results in most severe form of nerve injury i.e. neurotmesis. In our study, most of the patients had temporary facial nerve damage that recovered within 3 months. While cases which had axonotmesis and neurotmesis type of injuries were all operated by preauricular approach. A comprehensive meta-analysis of 45 studies comprising 2810 mandibular condyle fractures reported facial nerve damage in 55% of studies.⁷ Moreover, they showed that after surgical treatment of condylar fractures the relative frequency of patients with facial nerve paresis was 8.6% and most of them (8.3%) were temporary in nature. Rozeboom and colleagues in their review of literature reported 12% to 48% incidence of facial nerve paralysis.⁸ They further pointed out that the incidence of both transient and permanent weakness is much higher in cases operated by non-transparotid approaches as compared to transparotid approach. Li and colleagues in their study compared standard preauricular approach to their modified supratemporalis approach and found facial nerve injury in almost 11% of cases (7/64) operated by standard approach while none of the patients operated by supratemporalis approach had any facial nerve dysfunction postoperatively.⁹

We observed that most of the patients treated by submandibular approach were not satisfied with their surgical scar. Among extraoral approaches preauricular approach showed best aesthetic results followed by retromandibular approach. Preauricular incision being concealed in preauricular crease/fold remains less conspicuous than other incisions. Contrarily, Rozeboom AVJ and colleagues showed comparatively better esthetic outcome in case of submandibular approach as compared to preauricular and retromandibular approaches.⁸

We observed salivary fistula in just one case (7.1%) and it was operated by retromandibular approach. Similarly, in literature the incidence of salivary fistula is found only in cases where transparotid approach is used except in a study where two cases with salivary fistula were seen after anterior parotid approach.¹⁰

In our study internal fixation was performed by a single miniplate (2.0 mm diameter screws) parallel to posterior border of ramus while an additional plate below the sigmoid notch was used in case of subcondylar fractures. Although we did not report any case of hardware fracture or screw loosening, there are some relatively old studies that have shown quite high hardware failure rates.^{6,11}

Conclusion

Facial nerve paresis is the most common complication of open treatment of mandibular condylar fractures. Although most of the facial nerve injuries were transient in nature, preauricular approach resulted in few permanent injuries. Submandibular incision results in most unaesthetic scars while the incidence of other complications was not remarkable in our study.

Disclaimer: None.

Conflict of Interest: None.

Funding Sources: None.

References

1. Niezen ET, Bos RRM, van Minnen B, Eckelt U, Tavassol F, Dijkstra PU. Fractures of the mandibular condyle: A comparison of patients, fractures and treatment characteristics between Groningen (The Netherlands) and Dresden (Germany). *J Craniomaxillofac Surg* 2018; 46: 1719-25.
2. Weiss JP, Sawhney R. Update on mandibular condylar fracture management. *Curr Opin Otolaryngol Head Neck Surg* 2016; 24: 273-8.
3. Grinsell D, Keating CP. Peripheral nerve reconstruction after injury: a review of clinical and experimental therapies. *Biomed Res Int* 2014; 2014: 698256.
4. Al-Moraissi EA, Louvrier A, Colletti G, Wolford LM, Biglioli F, Ragaey M, et al. Does the surgical approach for treating mandibular condylar fractures affect the rate of seventh cranial nerve injuries? A systematic review and meta-analysis based on a new classification for surgical approaches. *J Craniomaxillofac Surg* 2018; 46: 398-412.
5. Bhutia O, Kumar L, Jose A, Roychoudhury A, Trikha A. Evaluation of

- facial nerve following open reduction and internal fixation of subcondylar fracture through retromandibular transparotid approach. *Br J Oral Maxillofac Surg* 2014; 52: 236-40.
6. Hammer B, Schier P, Prein J. Osteosynthesis of condylar neck fractures: a review of 30 patients. *Br J Oral Maxillofac Surg* 1997; 35: 288-91.
 7. García-Guerrero I, Ramírez JM, Gómez de Diego R, Martínez-González JM, Poblador MS, Lancho JL. Complications in the treatment of mandibular condylar fractures: Surgical versus conservative treatment. *Ann Anat* 2018; 216: 60-8.
 8. Rozeboom AVJ, Dubois L, Bos RRM, Spijker R, de Lange J. Open treatment of condylar fractures via extraoral approaches: A review of complications. *J Craniomaxillofac Surg* 2018; 46: 1232-40.
 9. Li H, Zhang G, Cui J, Liu W, Dilxat D, Liu L. A modified preauricular approach for treating intracapsular condylar fractures to prevent facial nerve injury: the supratemporalis approach. *J Oral Maxillofac Surg* 2016; 74: 1013-22.
 10. Hou J, Chen L, Wang T, Jing W, Tang W, Long J, et.al. A new surgical approach to treat medial or low condylar fractures: the minor parotid anterior approach. *Oral Surg Oral Med Oral Pathol Oral Radiol* 2014; 117: 283-8.
 11. Derfoufi L, Delaval C, Goudot P, Yachouh J. Complications of condylar fracture osteosynthesis. *J Craniofac Surg* 2011; 22: 1448-51.
-